

June 5, 2018 – UCSF Osher MMS

# Shoulder & Elbow Fractures

**Utku KANDEMIR, MD**

Clinical Professor

University of California, San Francisco



# Disclosures

- AONA : Honorarium
- Biomet : Research Support
- Depuy Synthes: Research Support, Honorarium
- Stryker : Research Support, Honorarium

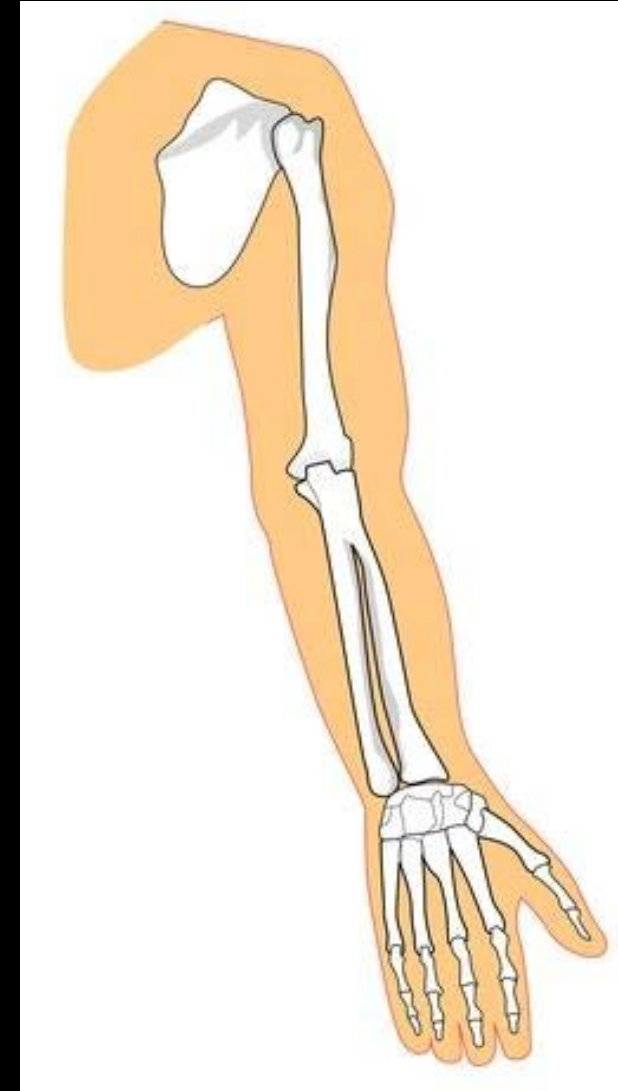
# Shoulder & Elbow

- Positioning of hand in the space



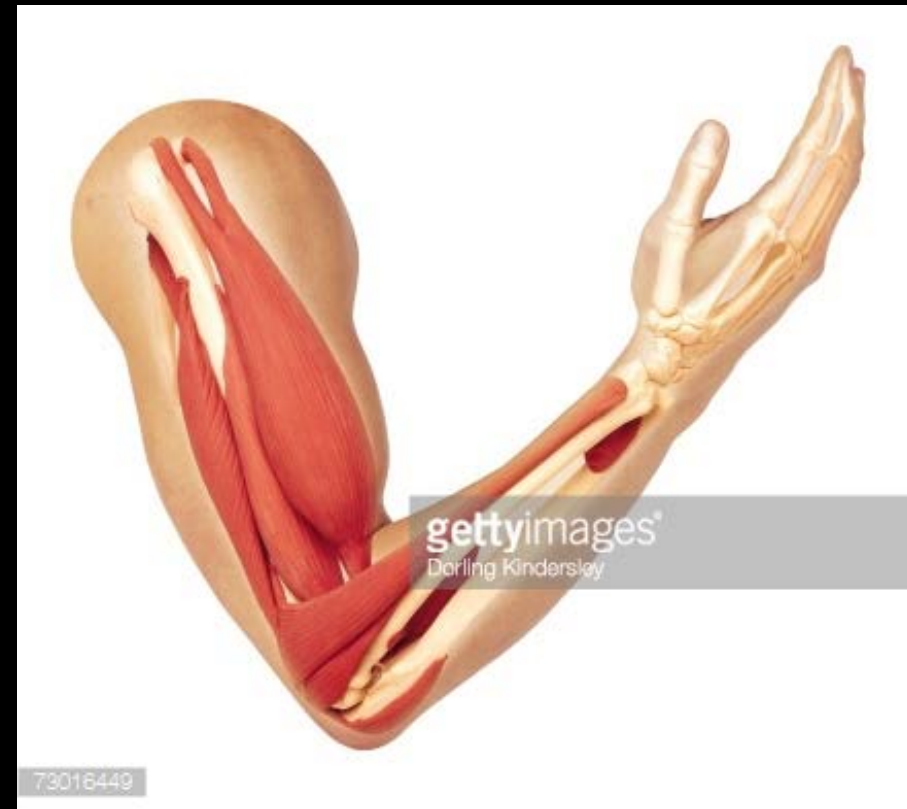# ADL

- Routine activities that people tend to do everyday without needing assistance



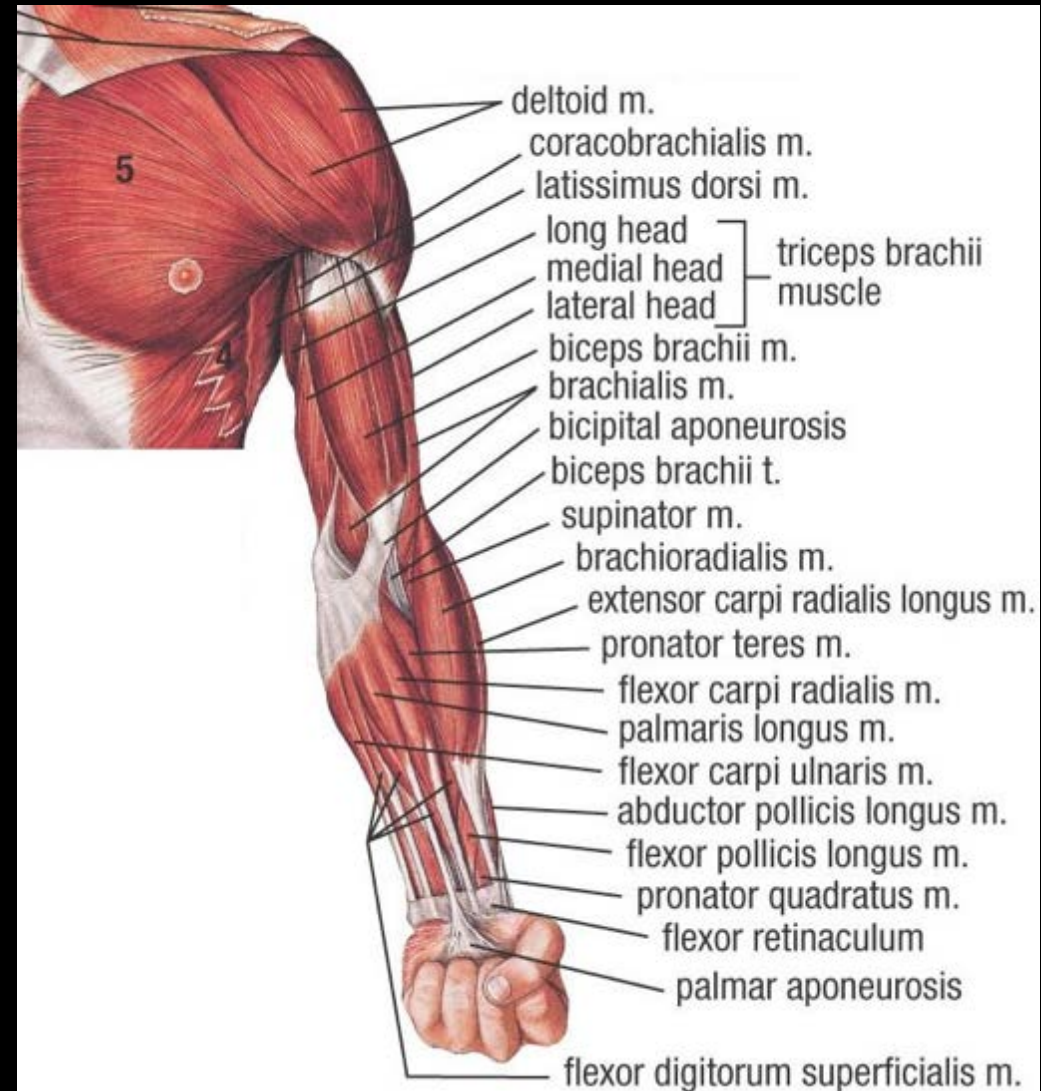
# 6 Basic ADL's

- Eating
- Bathing
- Dressing
- Toileting
- Transferring (walking)
- Contenance

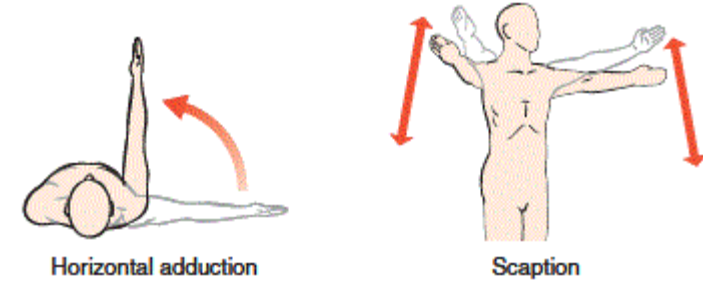
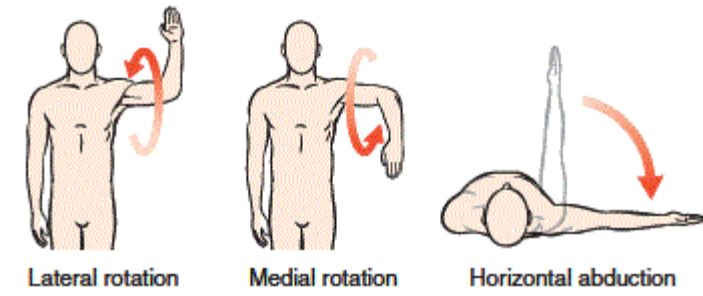
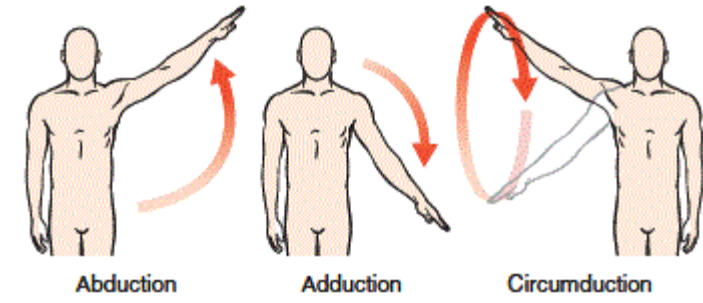
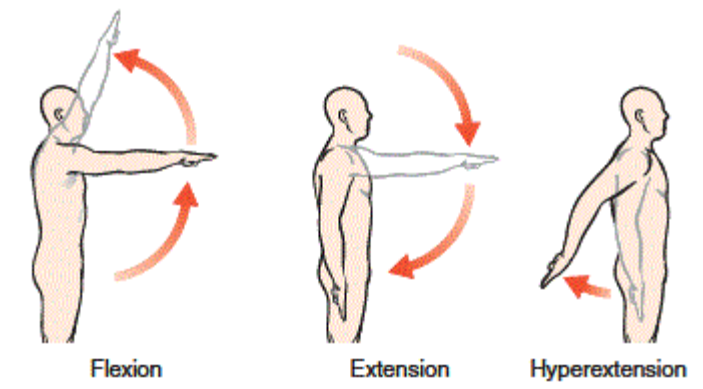
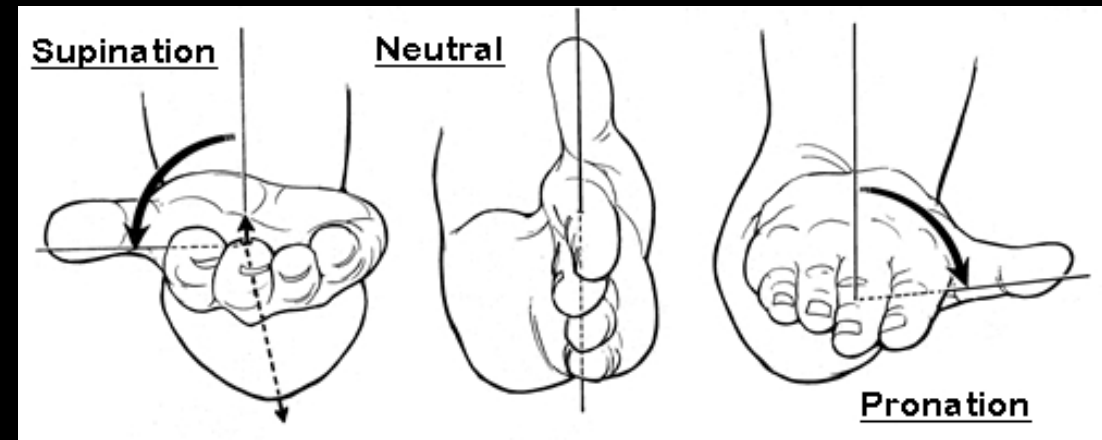
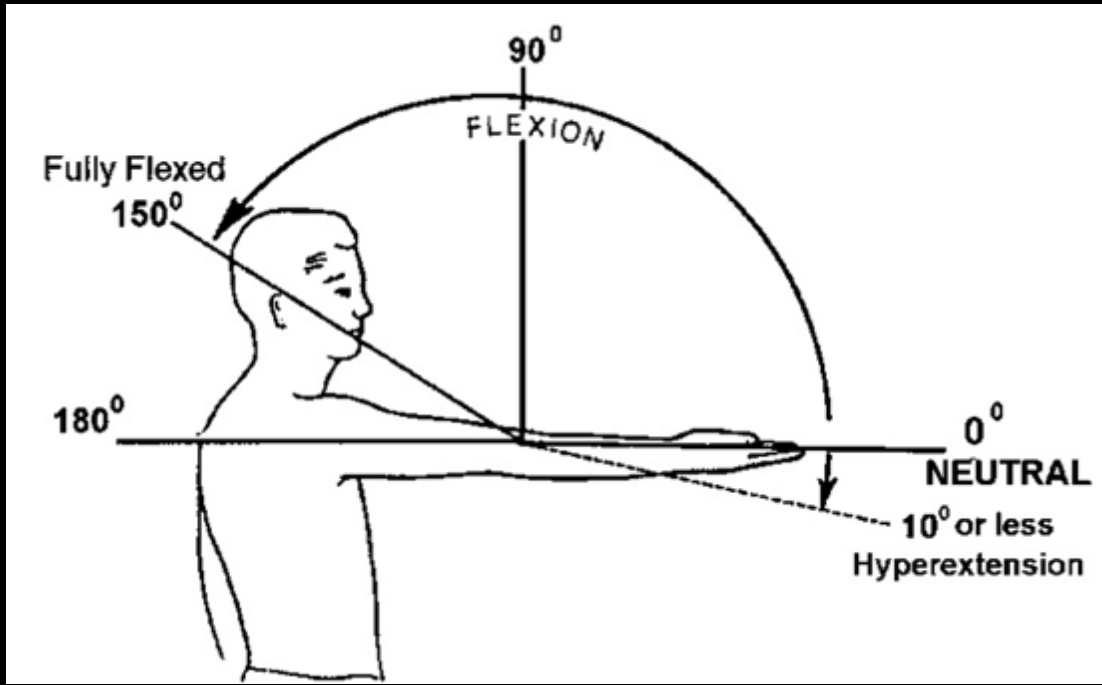


# Shoulder & Elbow

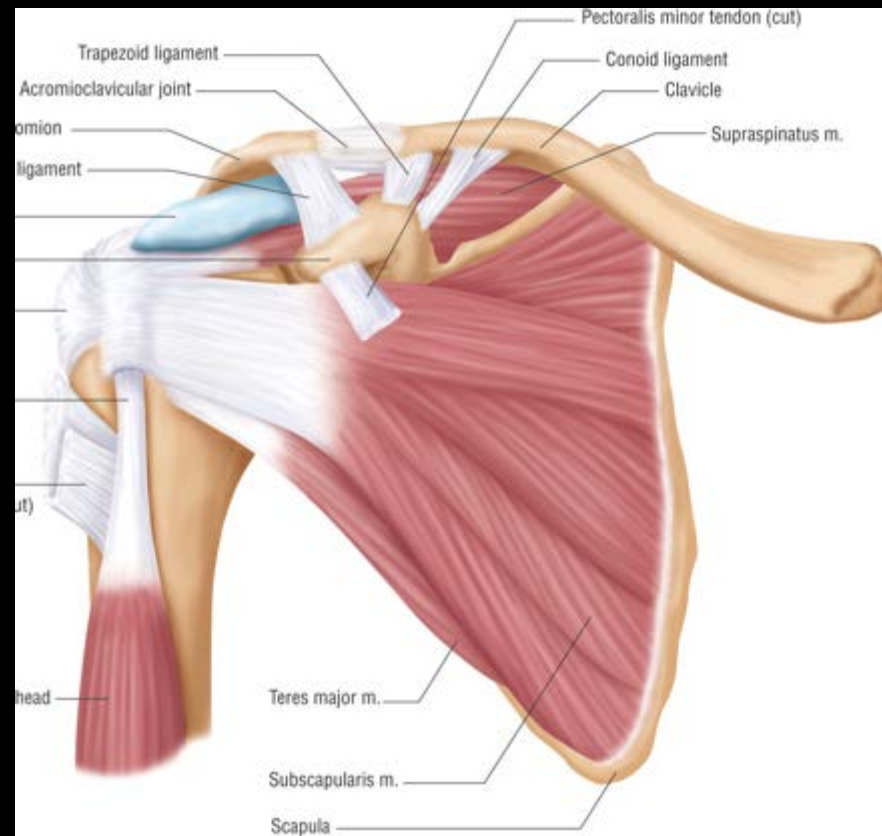
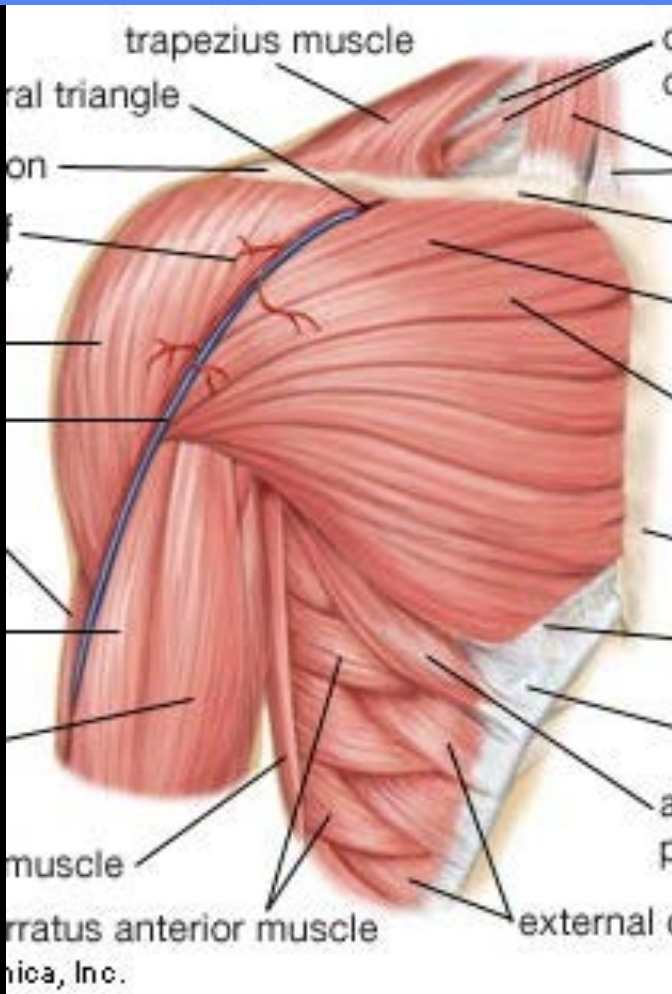
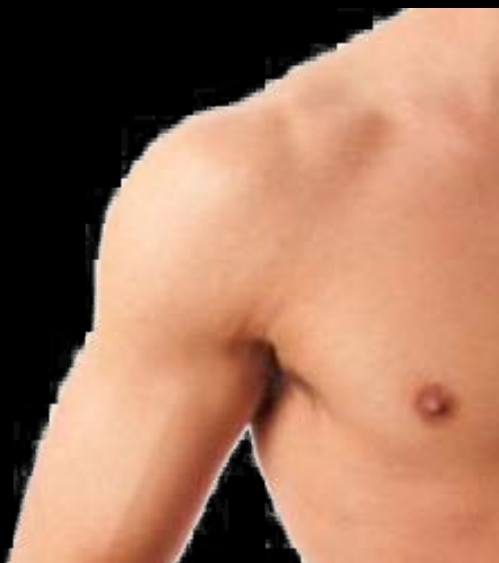- STIFFNESS:  
reduced ROM
- Challenging  
problem



# Functional ROM

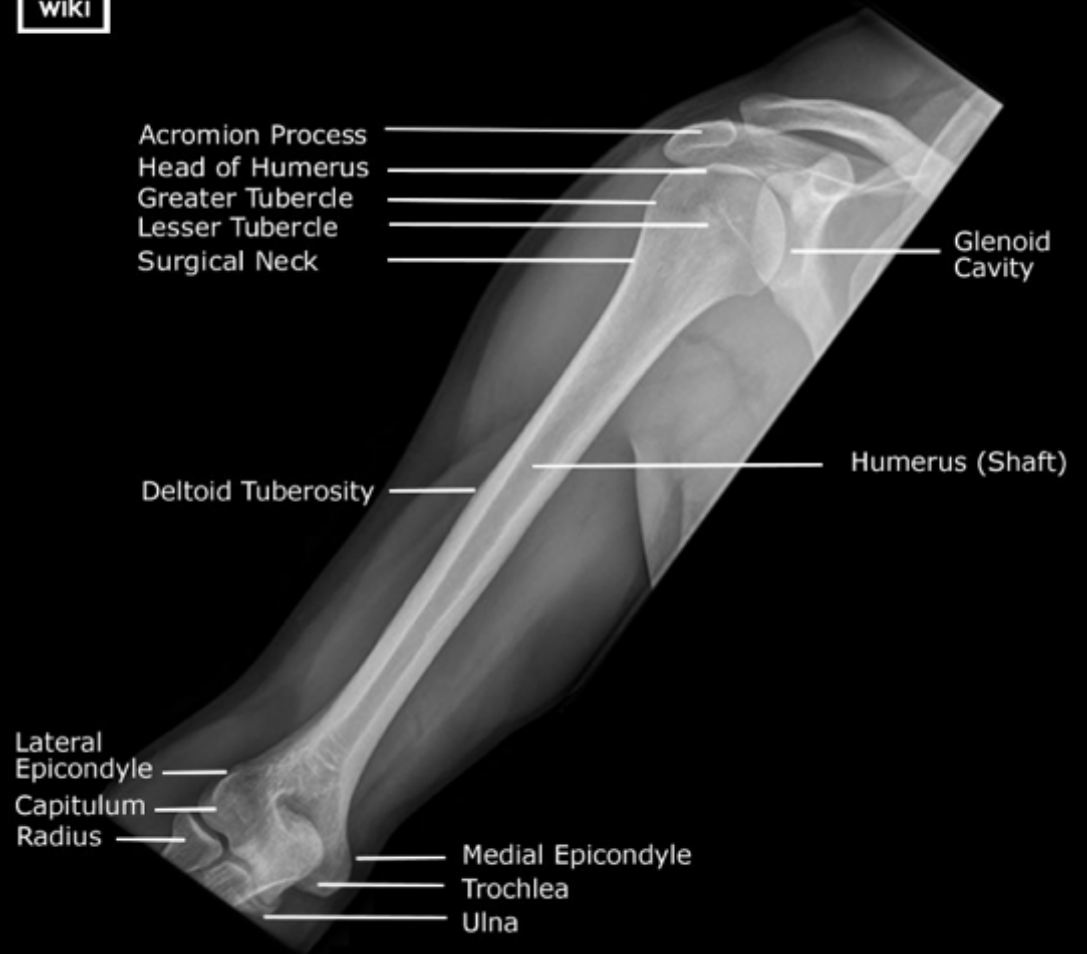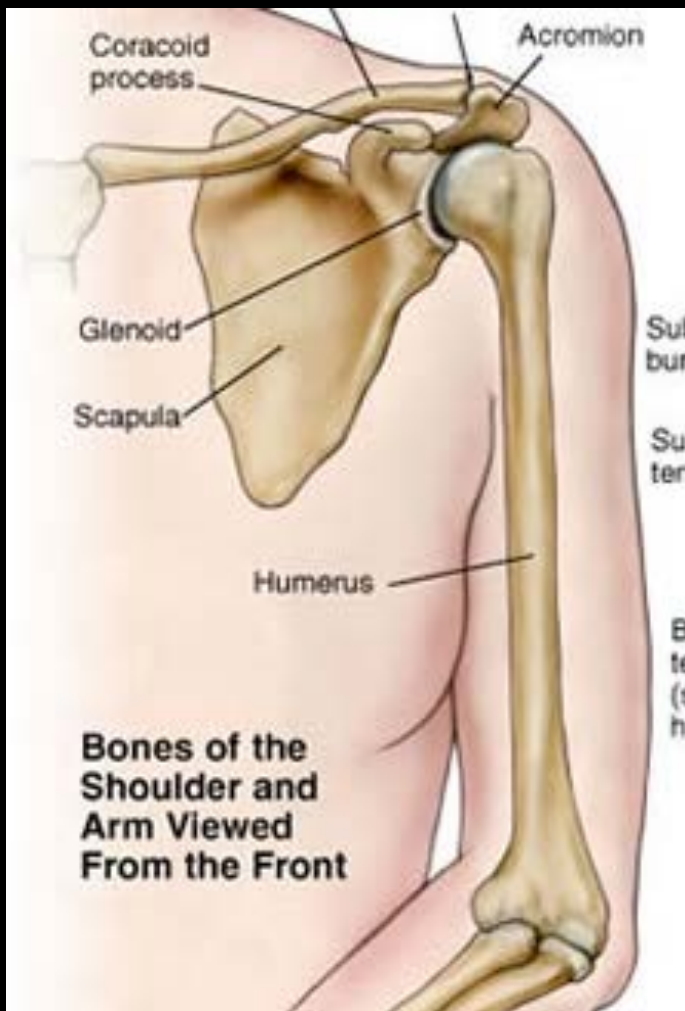


# Shoulder



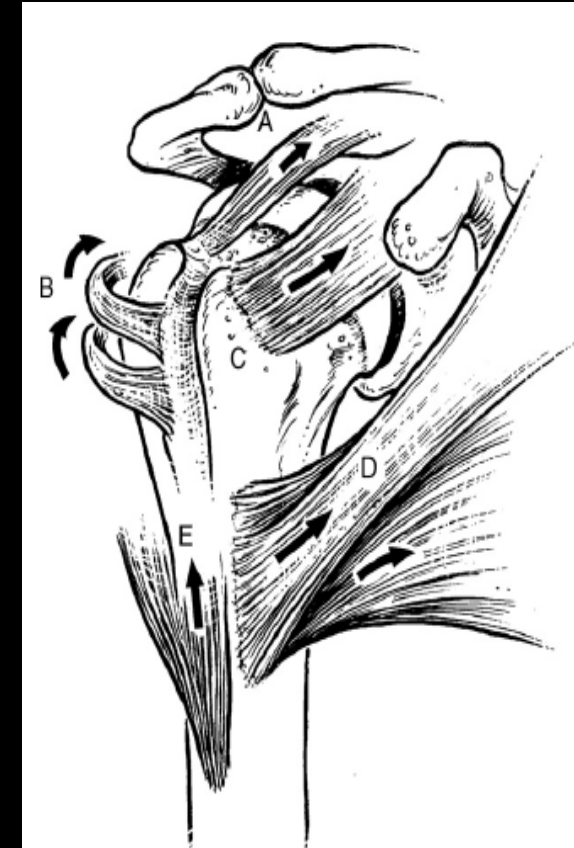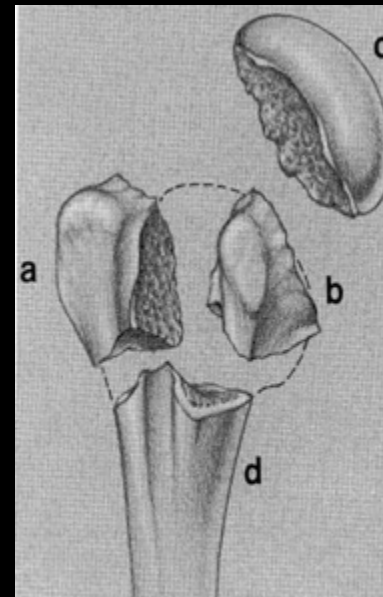
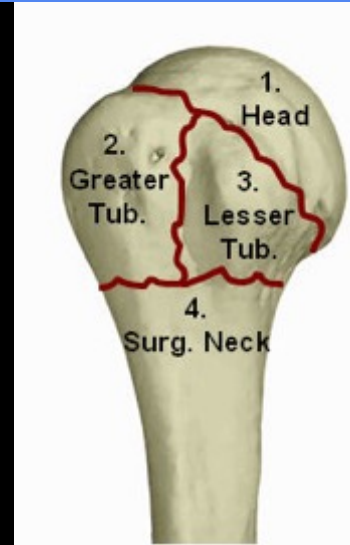


# Shoulder



# Proximal Humerus Fx's

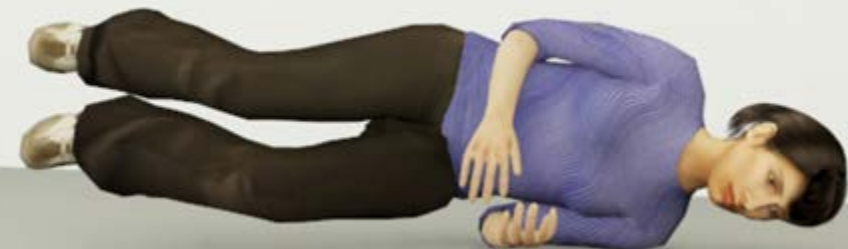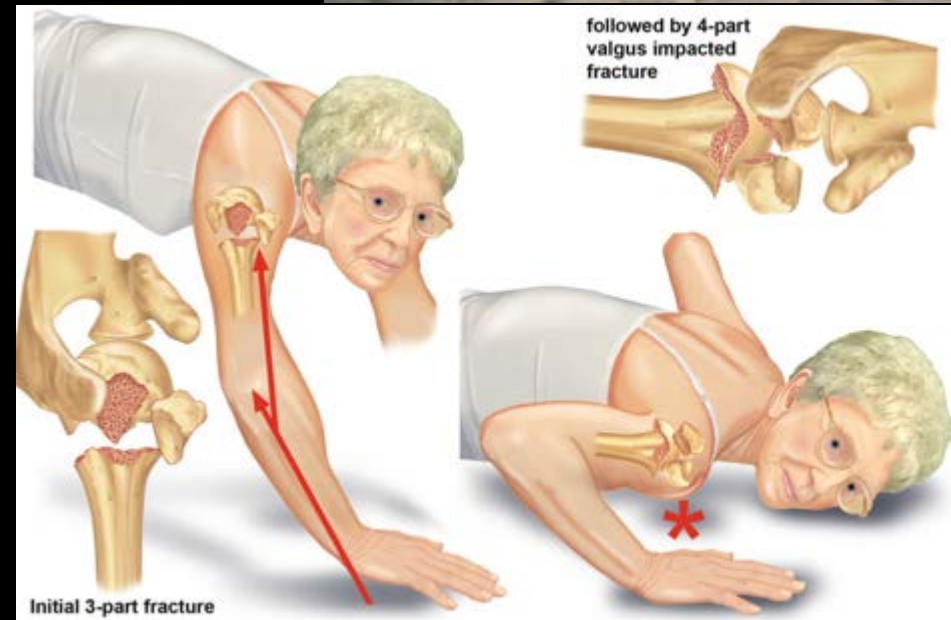
- 2<sup>nd</sup> most common UE fx (after DRFx)
- 3<sup>rd</sup> most common in > 65yo (hip fx, DRFx)
- Increasing epidemic (aging population)



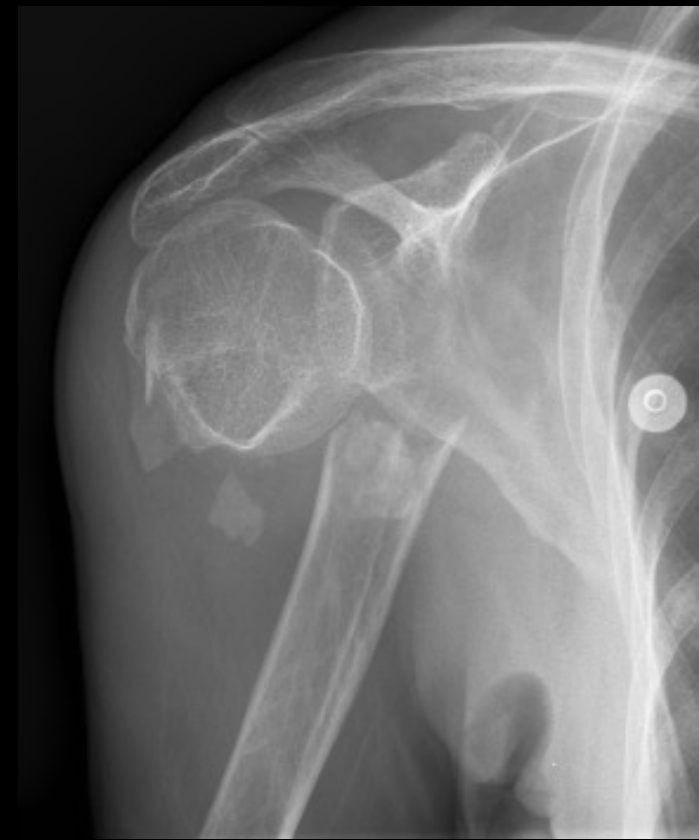
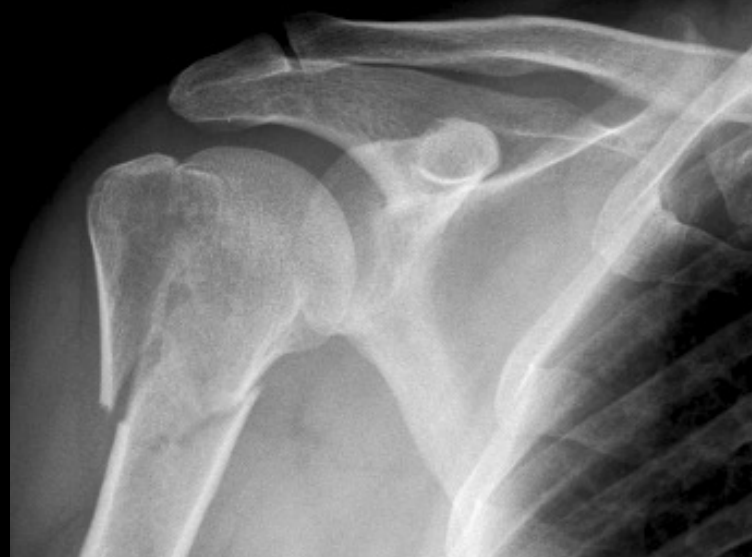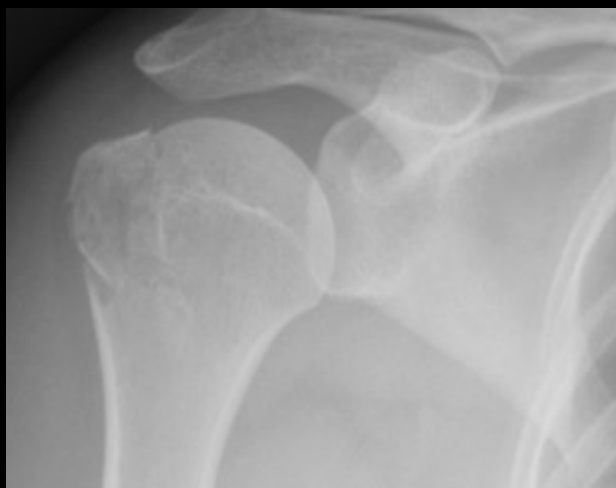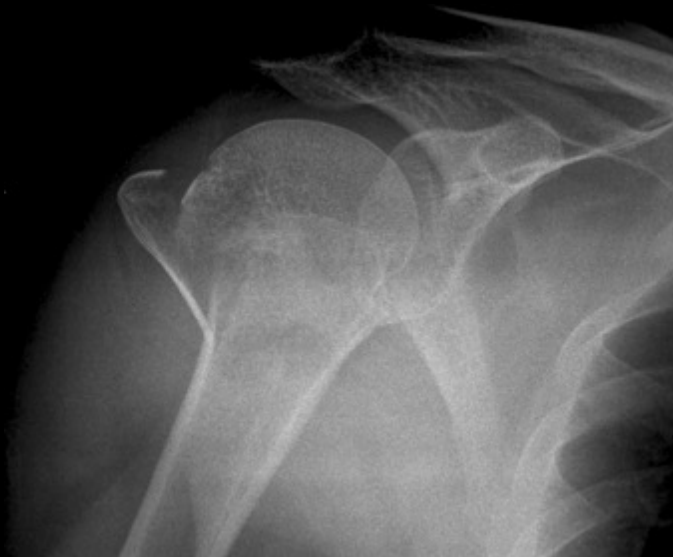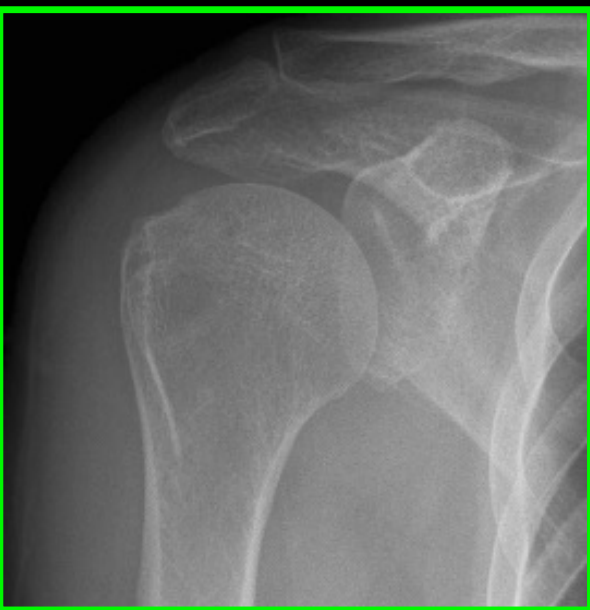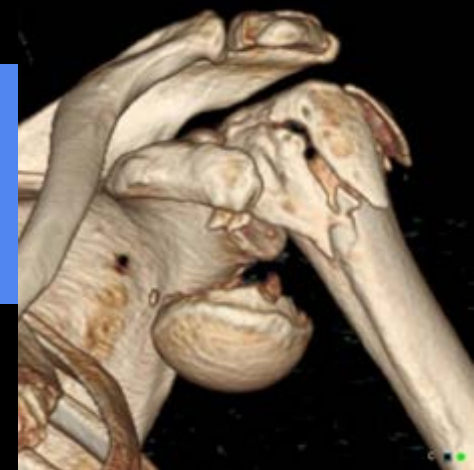
# Proximal Humerus Fx's

- Mechanism: Fall
- ♀ / ♂ = 2-3
- Bone quality is very poor (osteoporotic: eggshell)
- Most can be Rx'ed Nonop  
(~ 85-90%)

Court-Brown CM, JBJS 2001  
Kannus P, Bone 2009

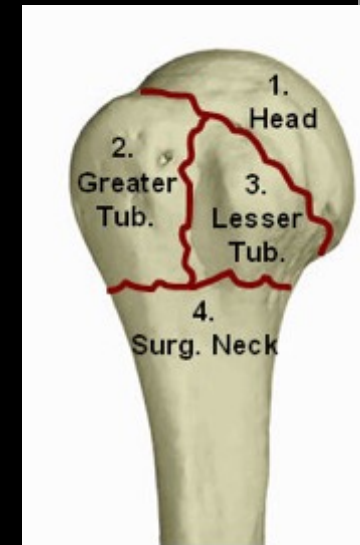
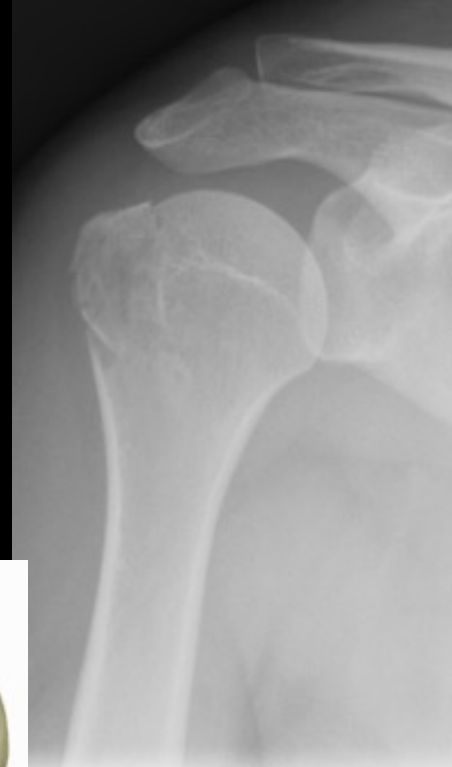

# Proximal Humerus Fx's



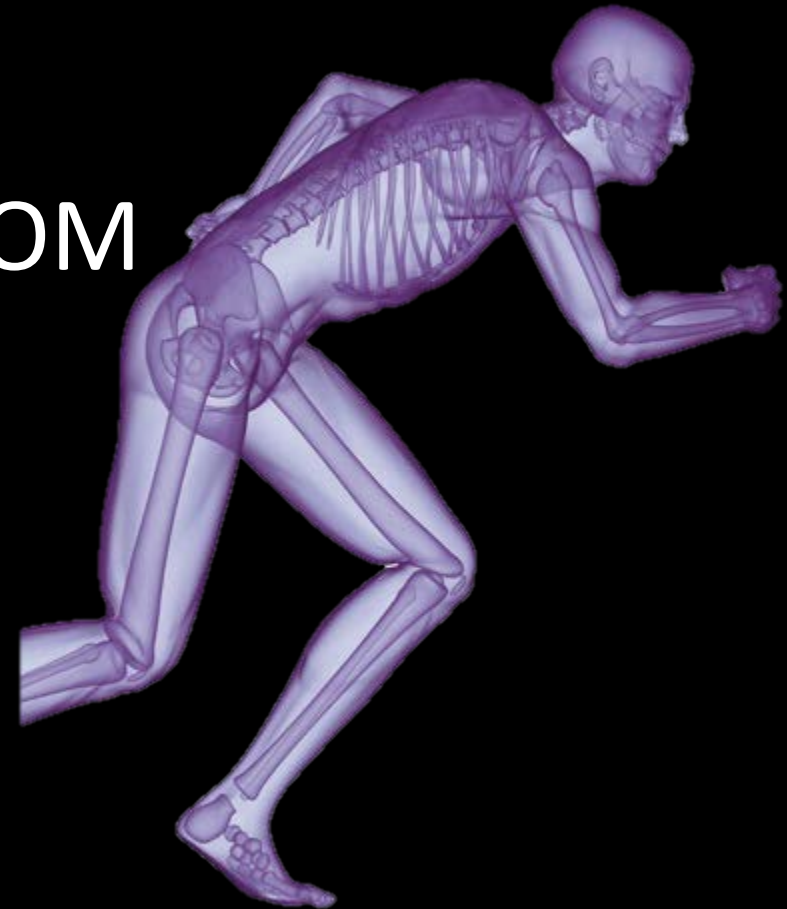# Proximal Humerus Fx's: TREATMENT

- Nonoperative
  - Most manageable nonoperatively
- Operative
  - NO clear cut Indications
    - >1cm, >45°
    - >5mm for Greater tuberosity



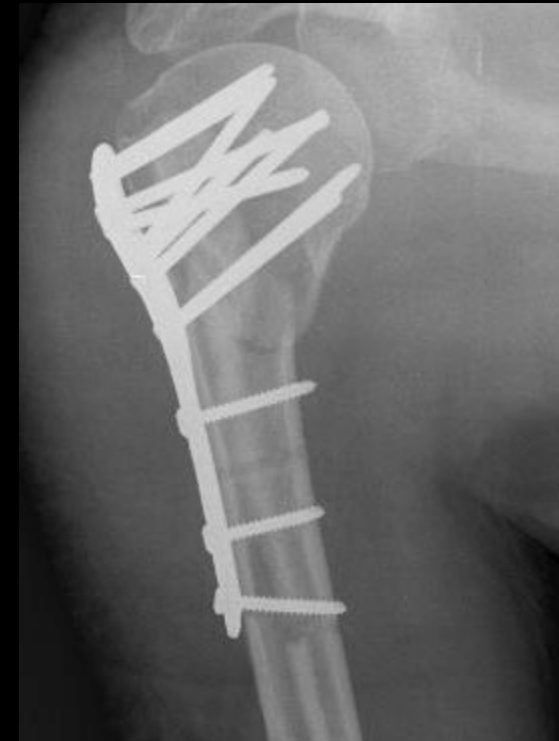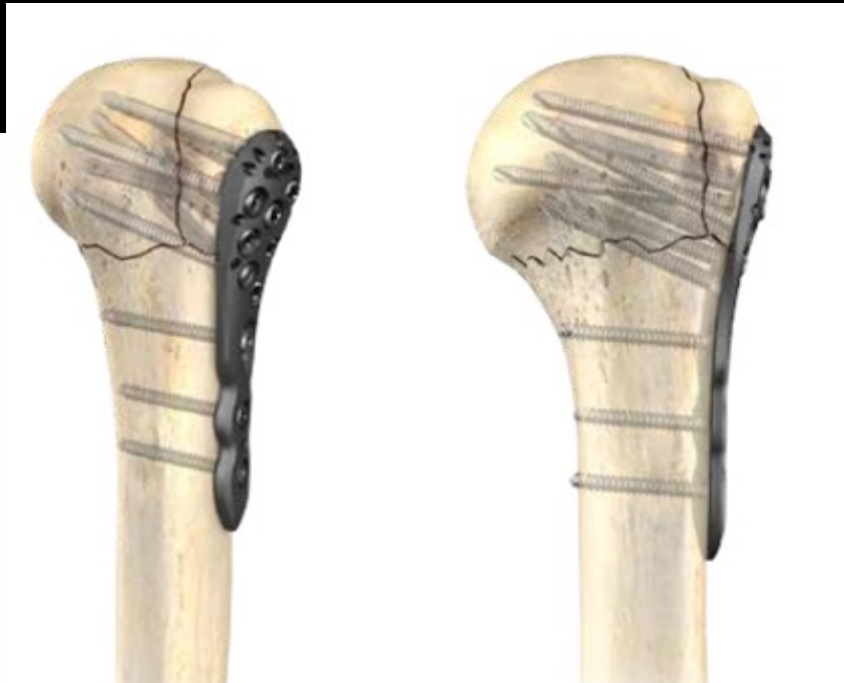# Treatment Goals

- Obtain & Maintain satisfactory REDUCTION
- Allow early progressive ROM
- Achieve healing
- Restore FUNCTION !



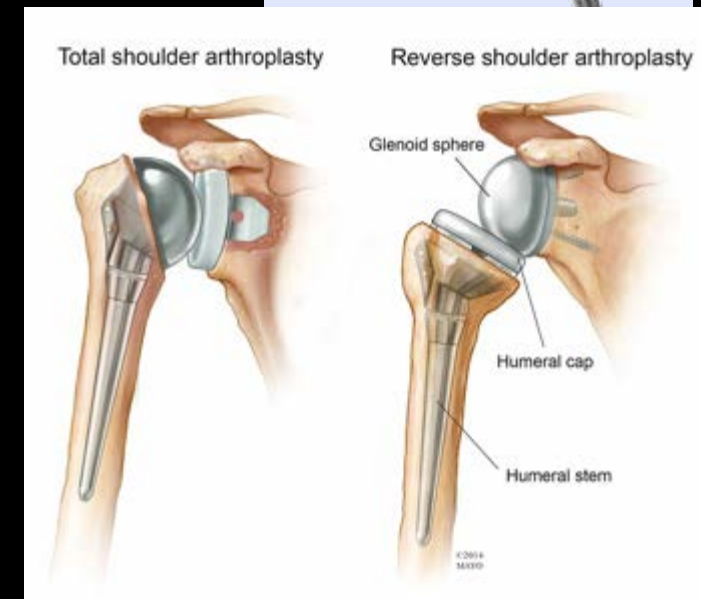
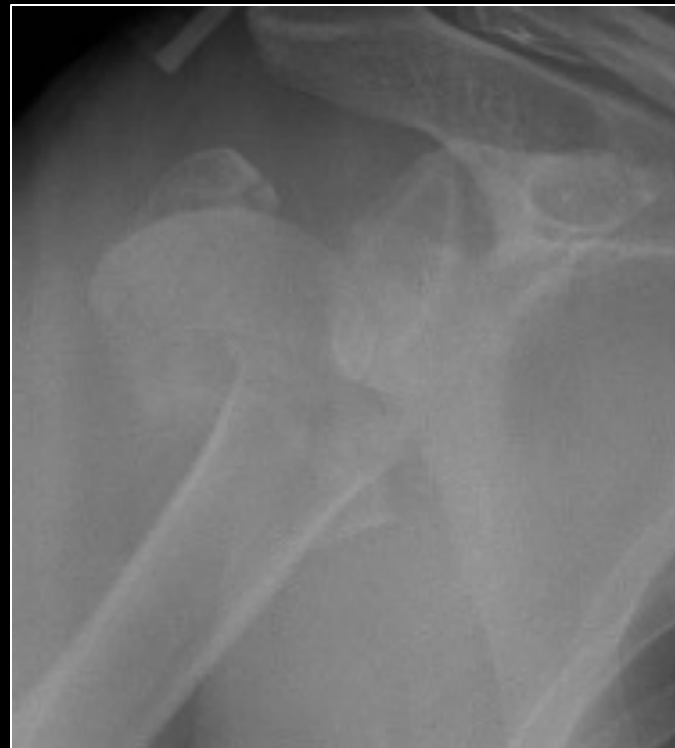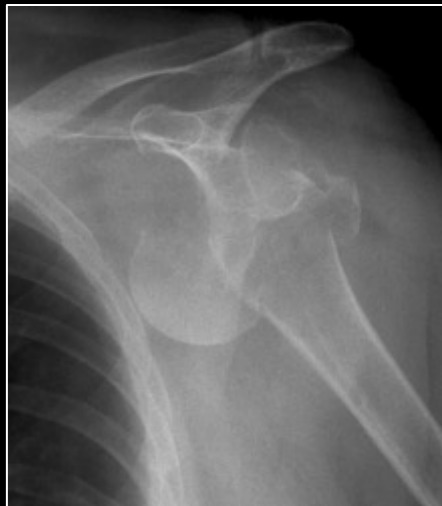# ORIF

- Most common type of surgical tx in US



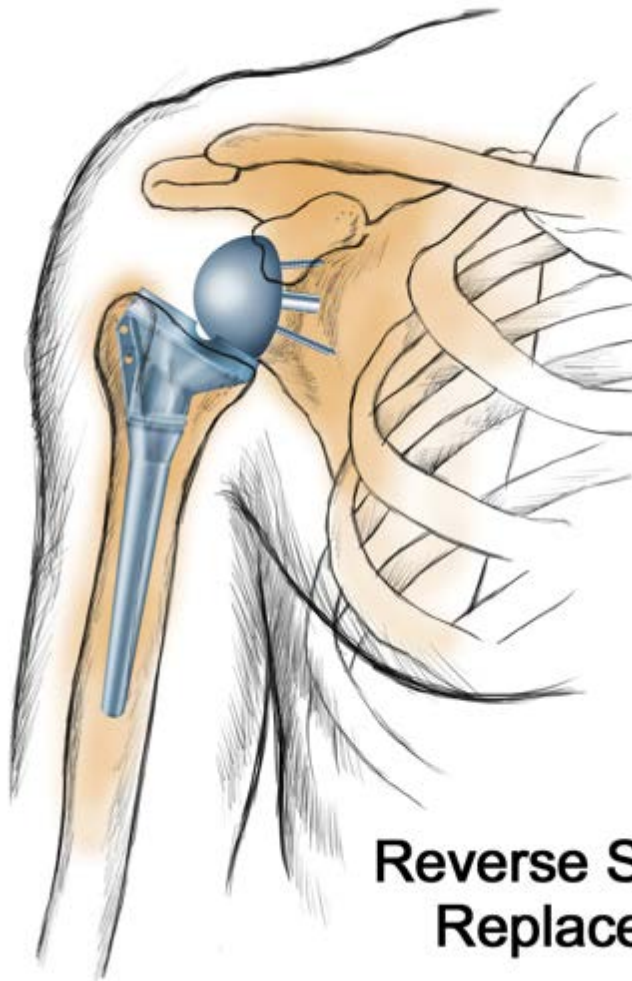
# Indication for Arthroplasty

- When fixation - **STABLE to allow early ROM** - is NOT possible
  - Fx pattern
  - Bone quality

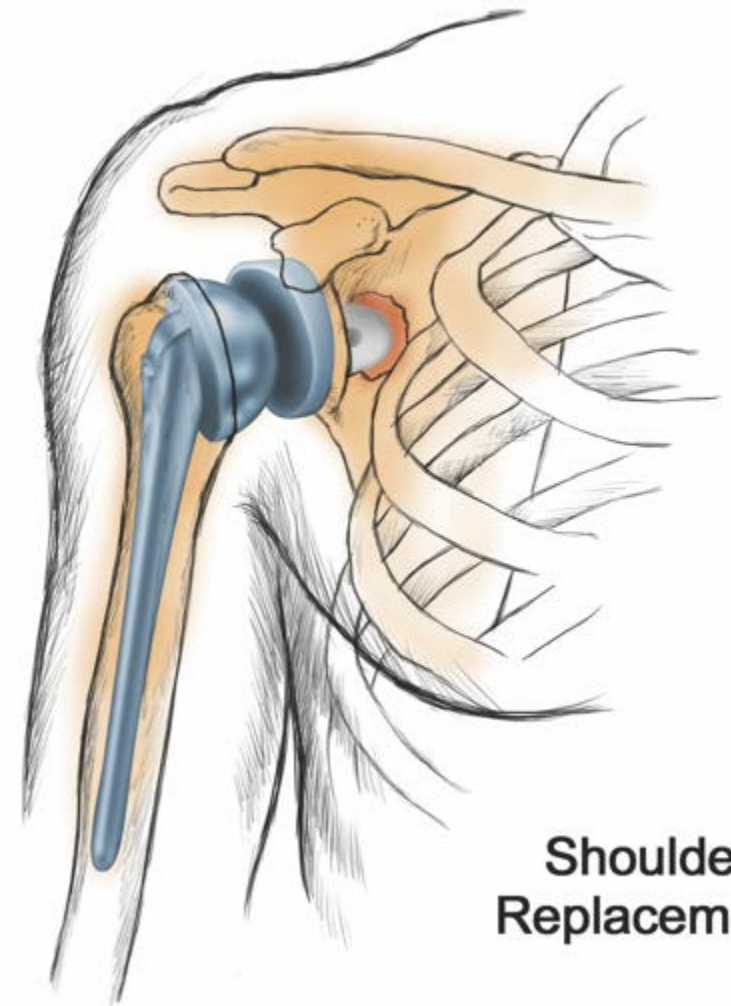
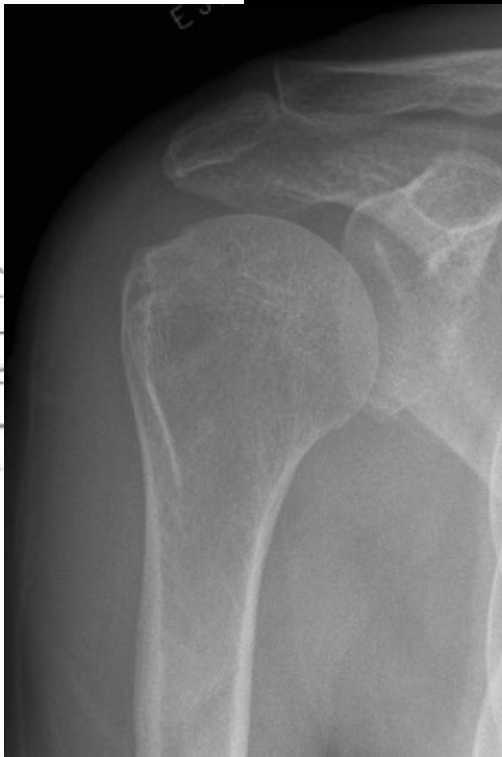



# Reverse TSA

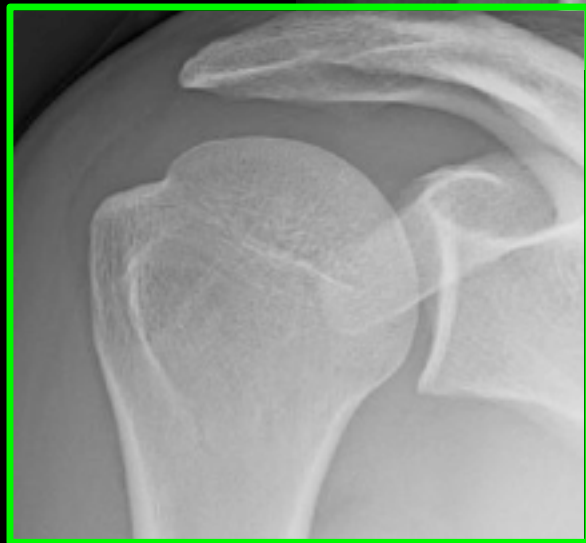
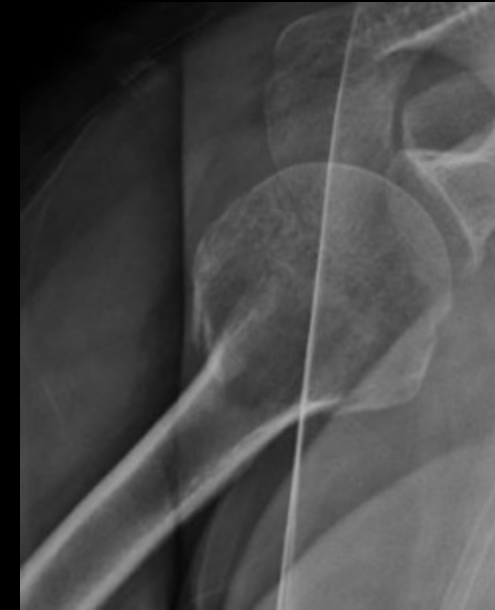
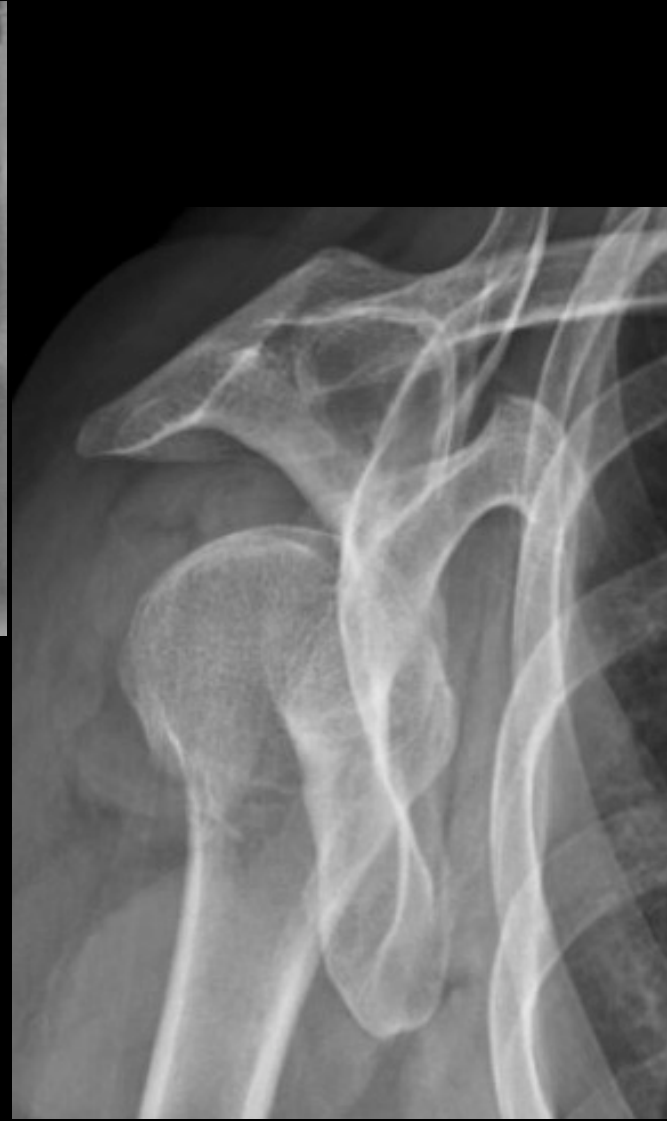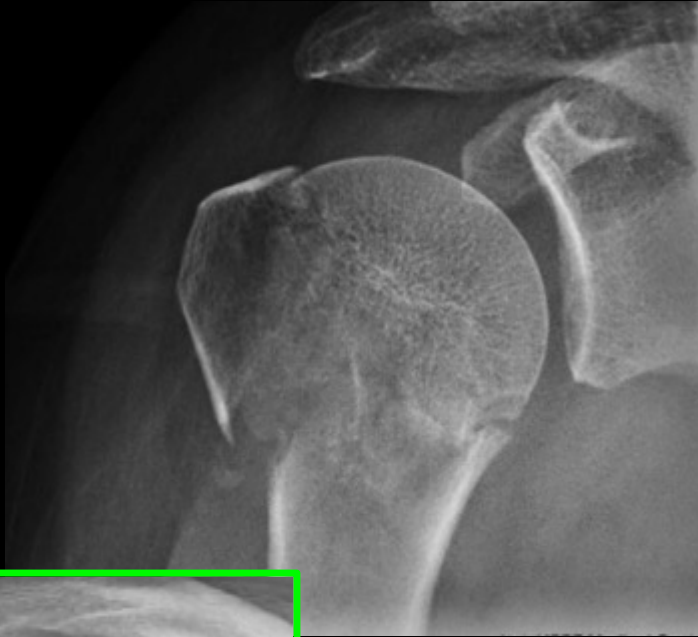**Reverse Shoulder  
Replacement**

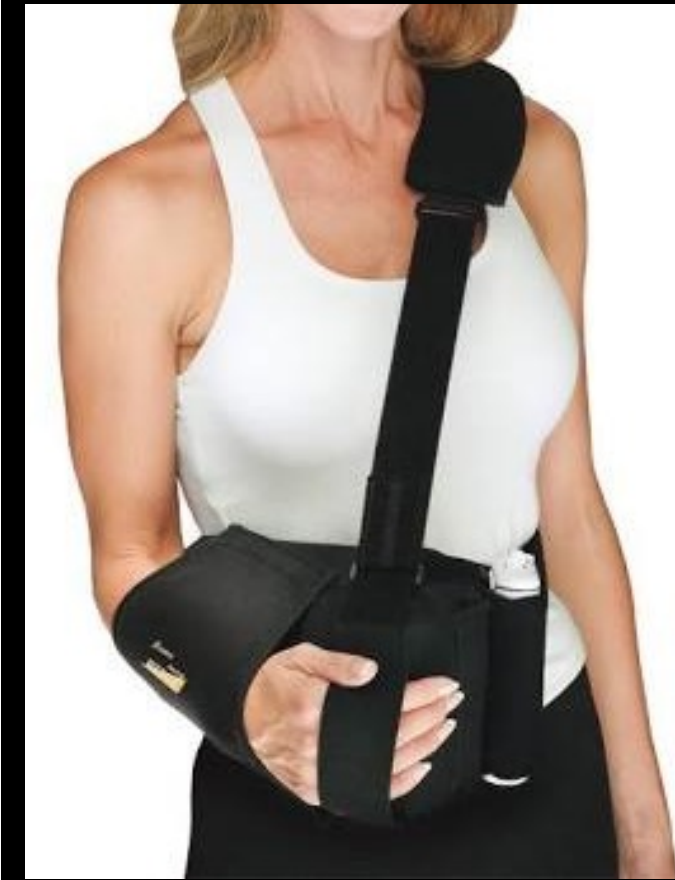
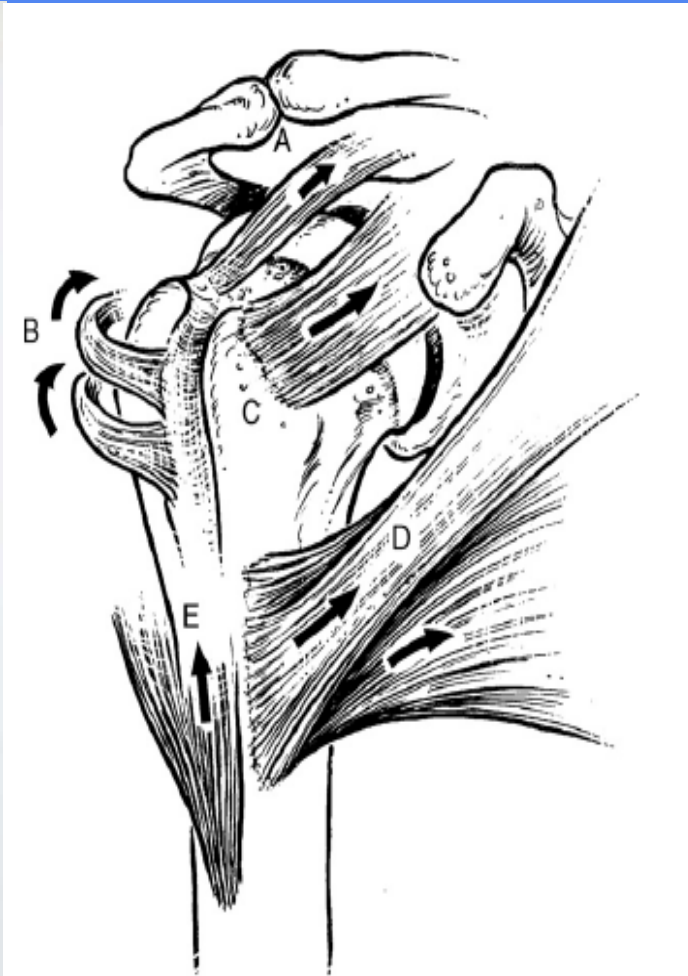
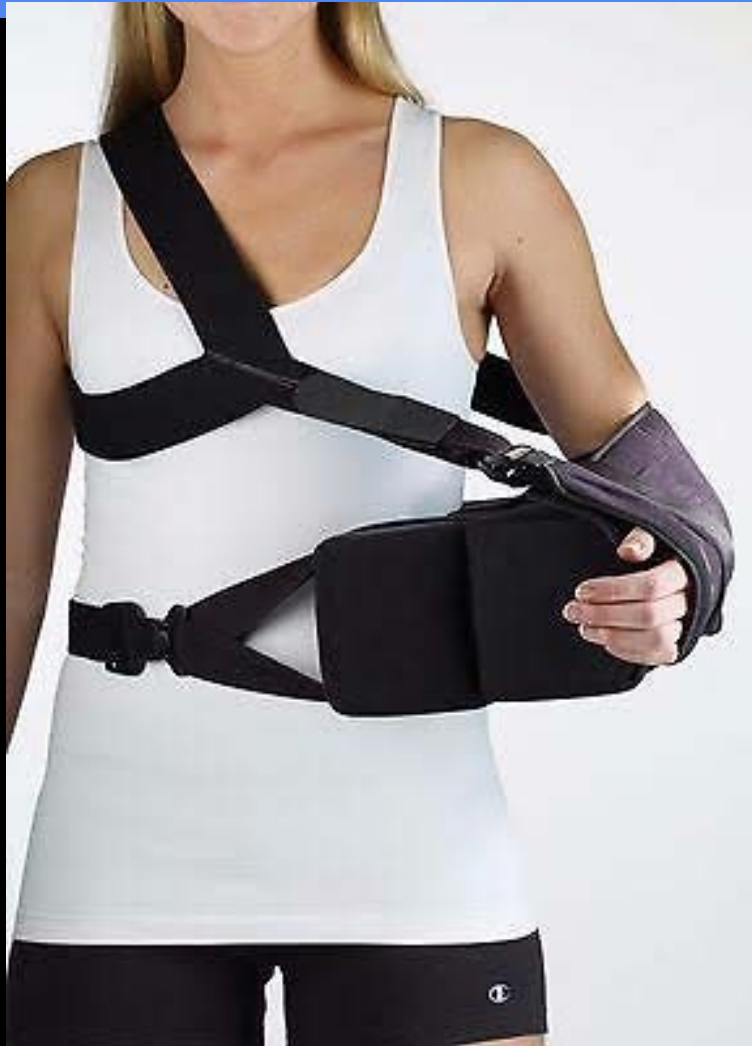**Shoulder  
Replacement**

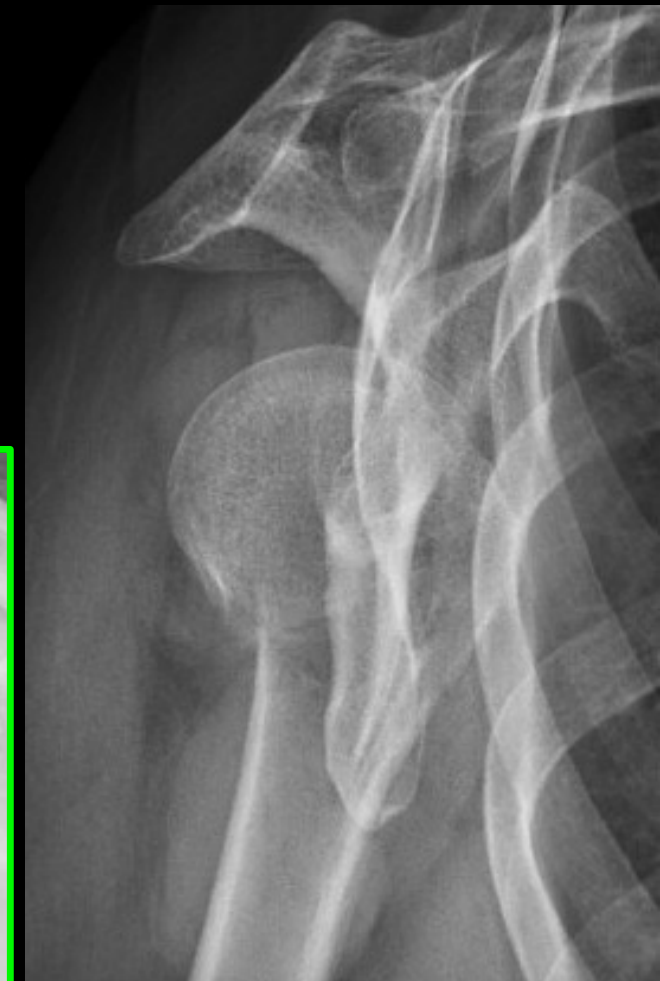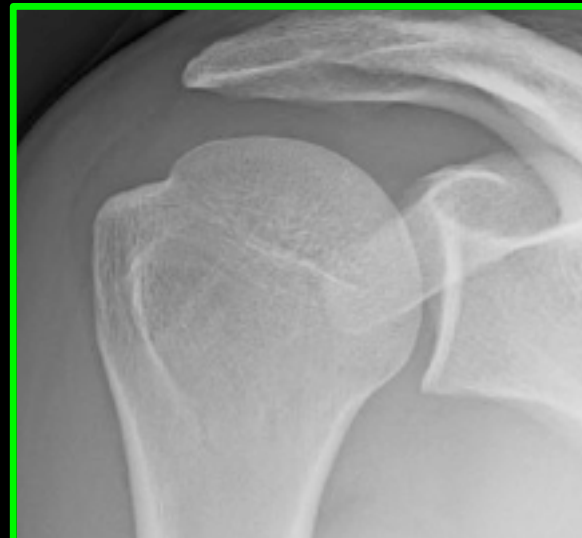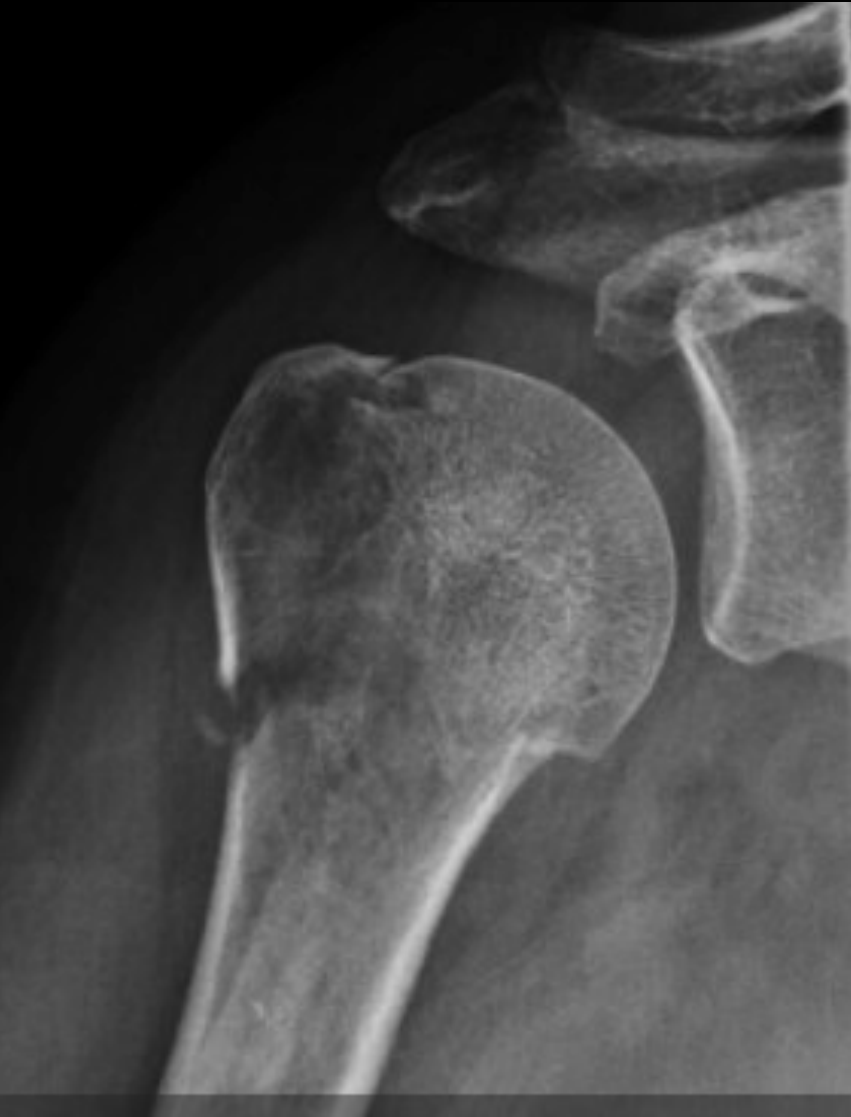# 54 y/o flight attendant, RHD postinjury day #5: Clinic



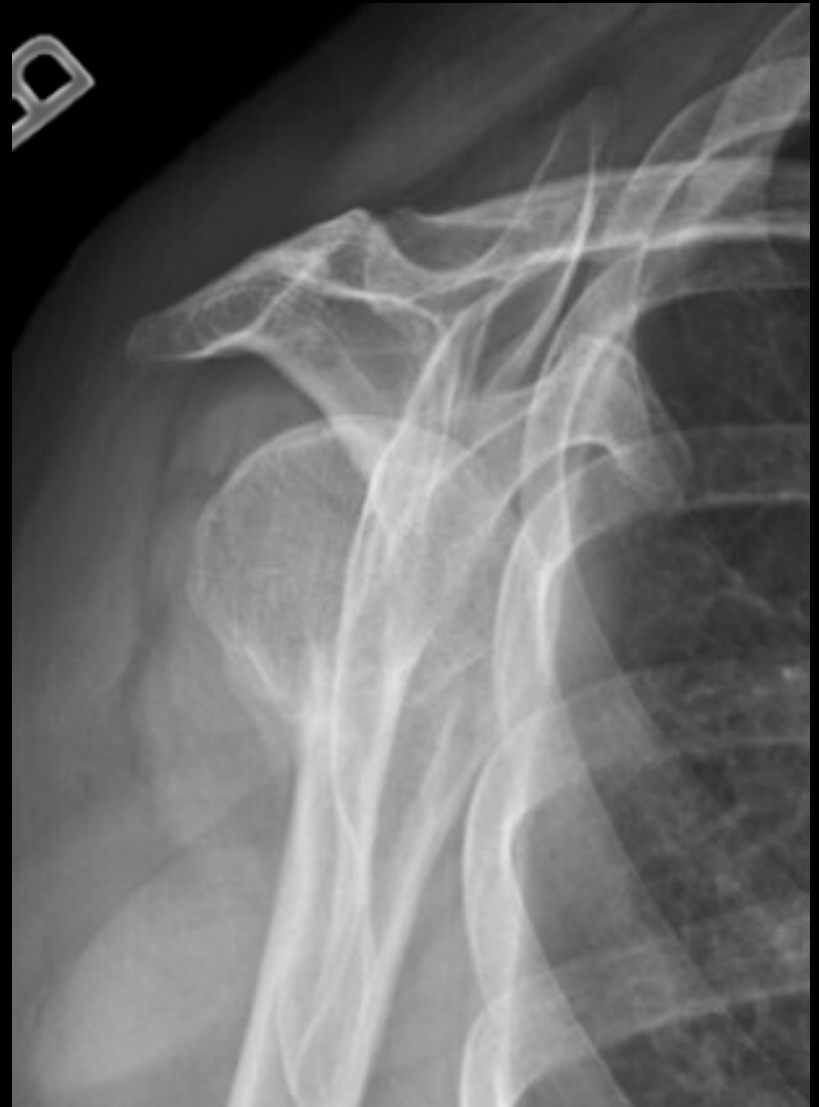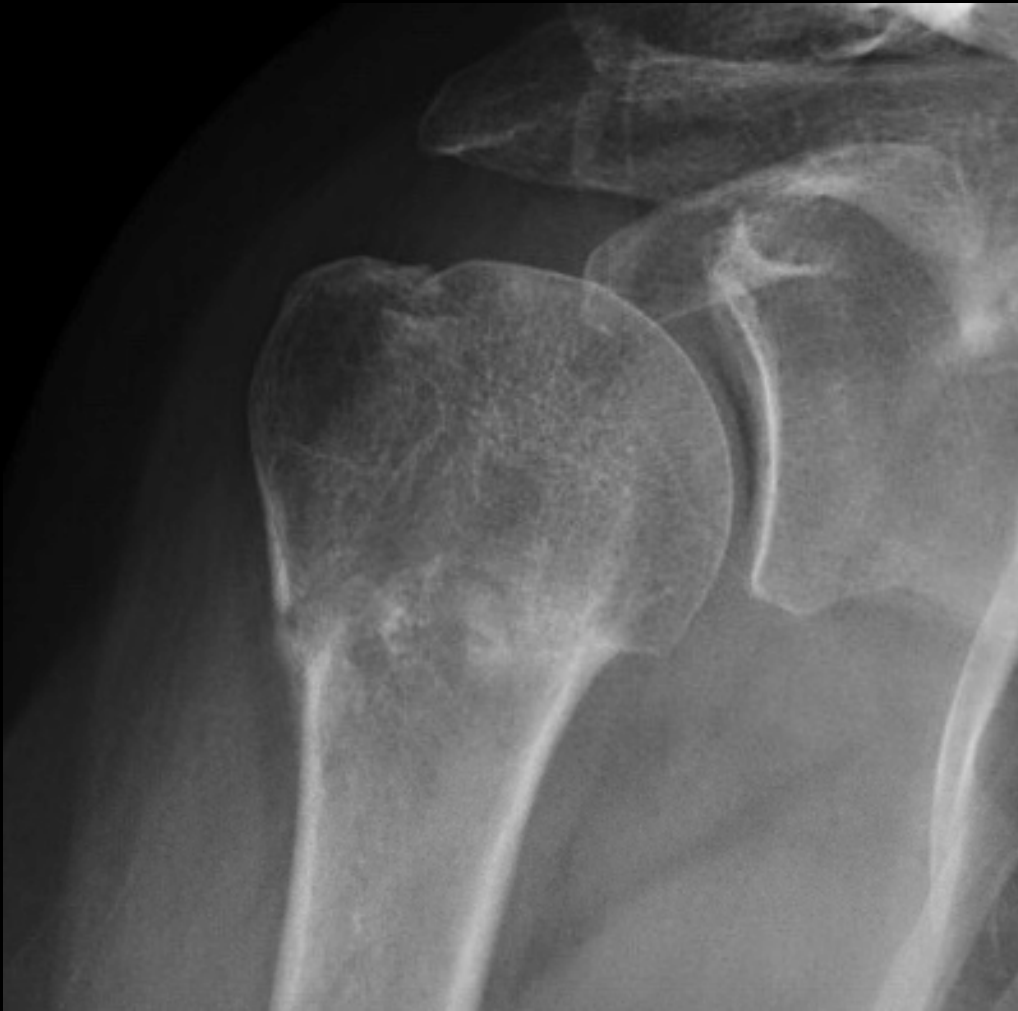# Nonoperative/Postop Treatment



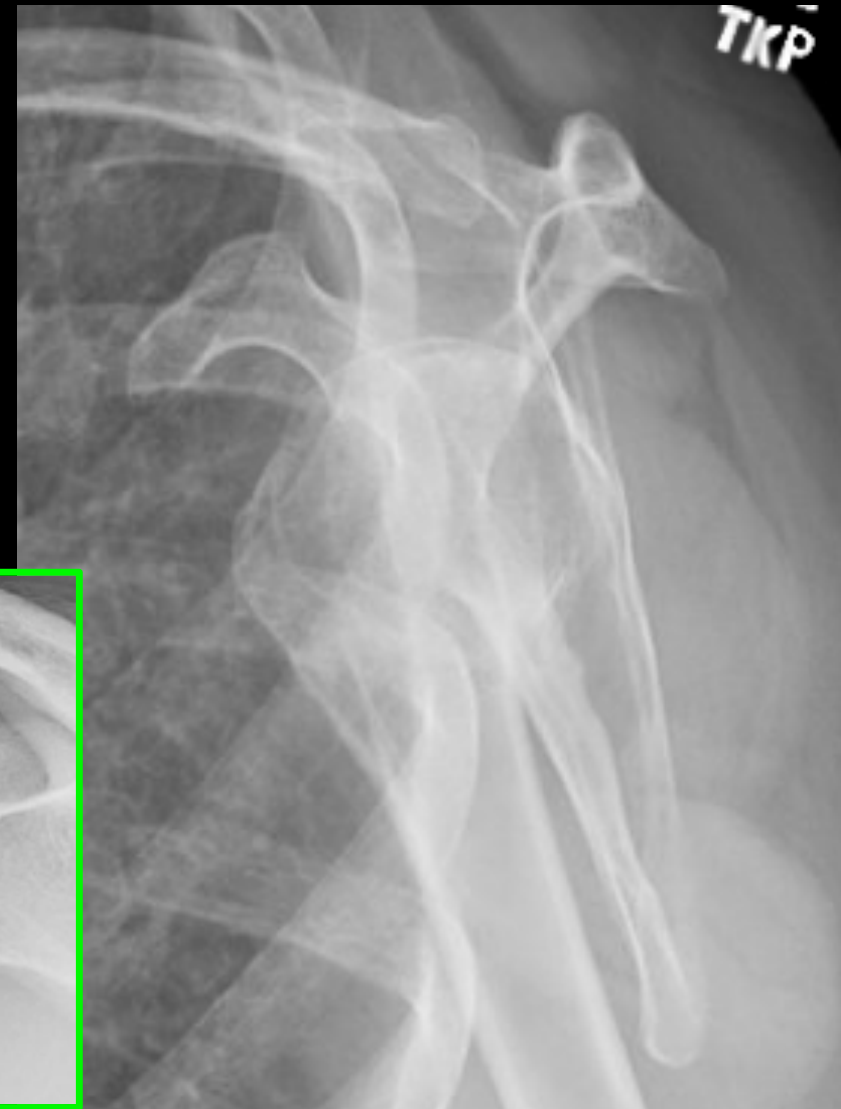
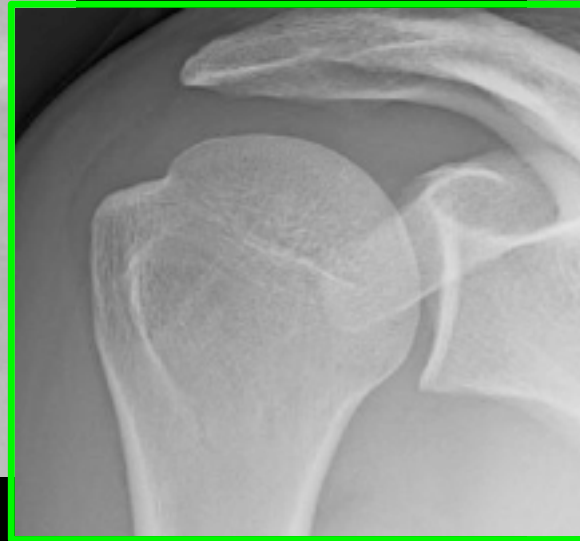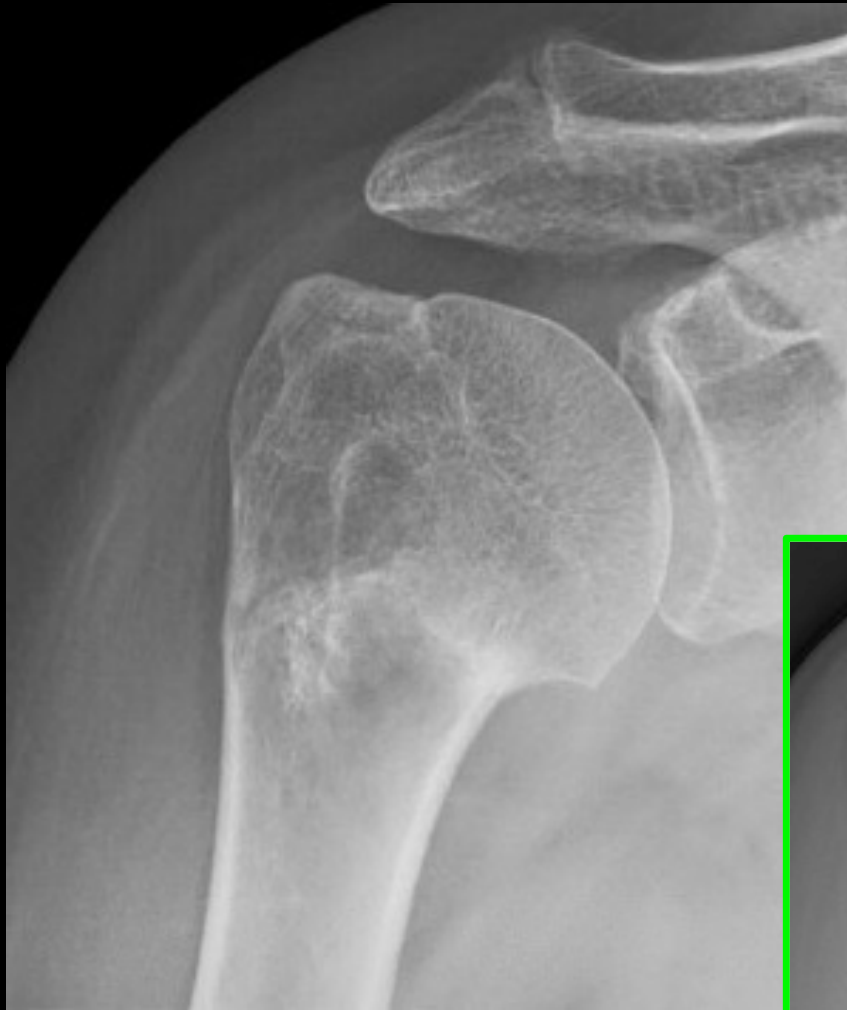54 y/o flight attendant, RHD  
postinjury 3 weeks



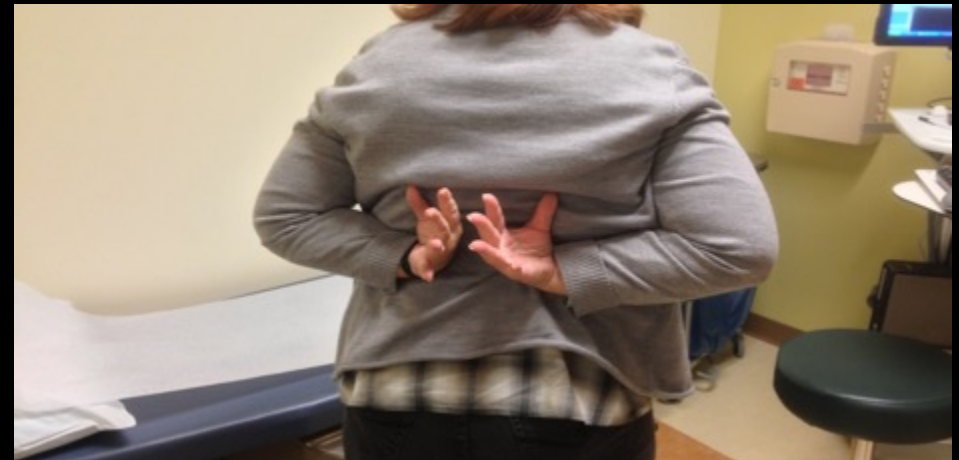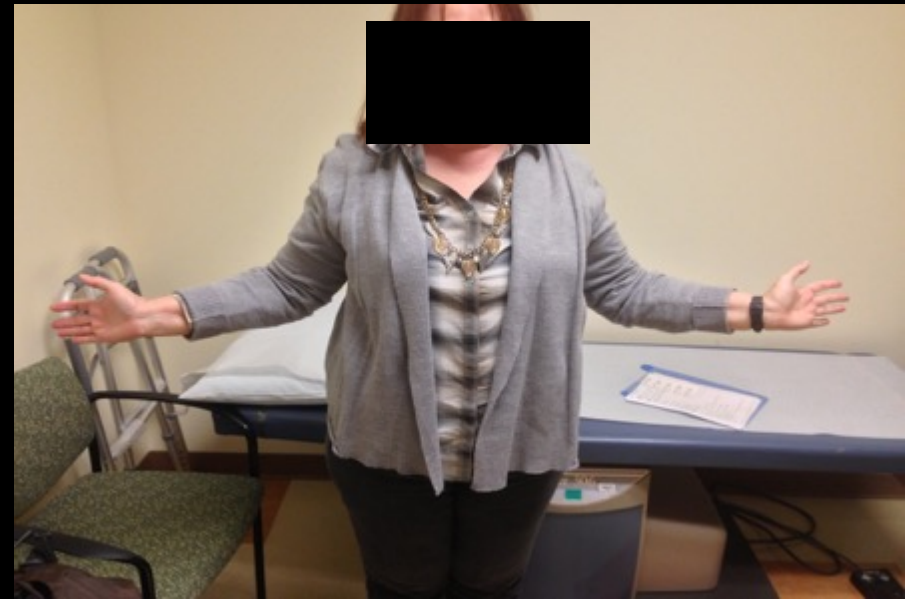54 y/o flight attendant, RHD  
postinjury 3 months



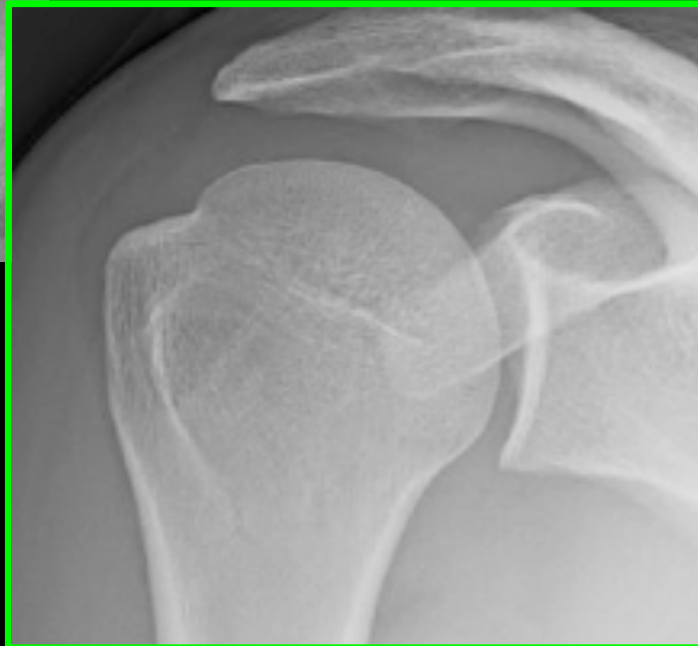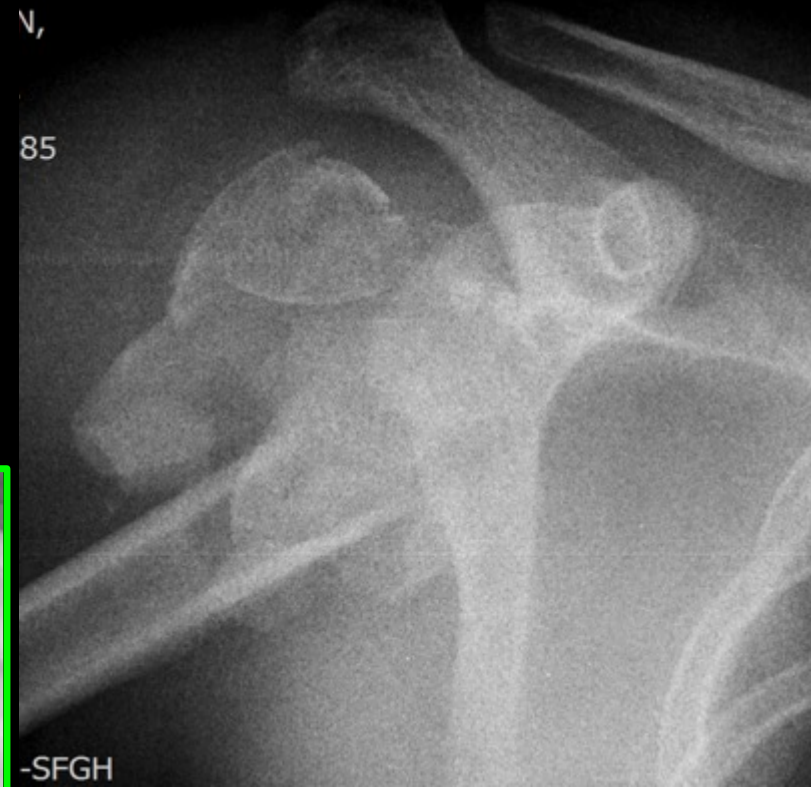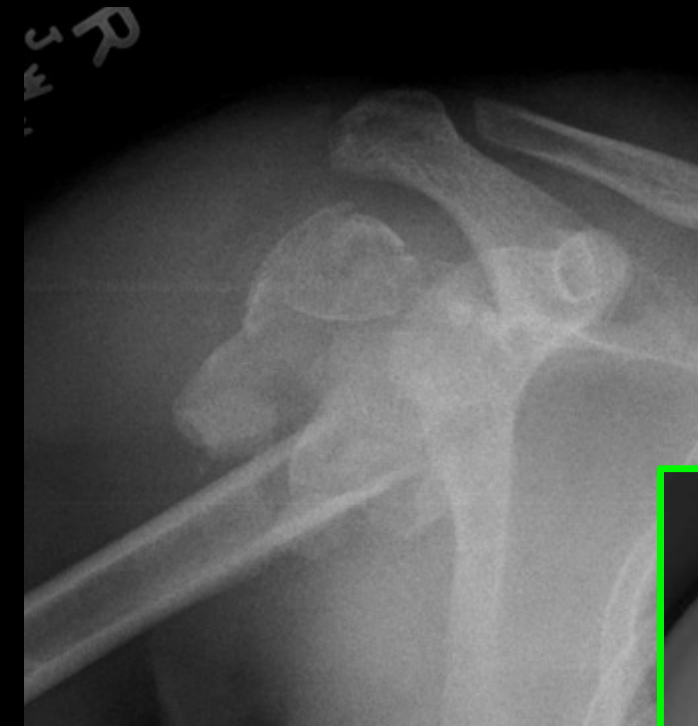54 y/o flight attendant, RHD  
postinjury 6 months



# SC, 54 y/o flight attendant, RHD postinjury 6 months

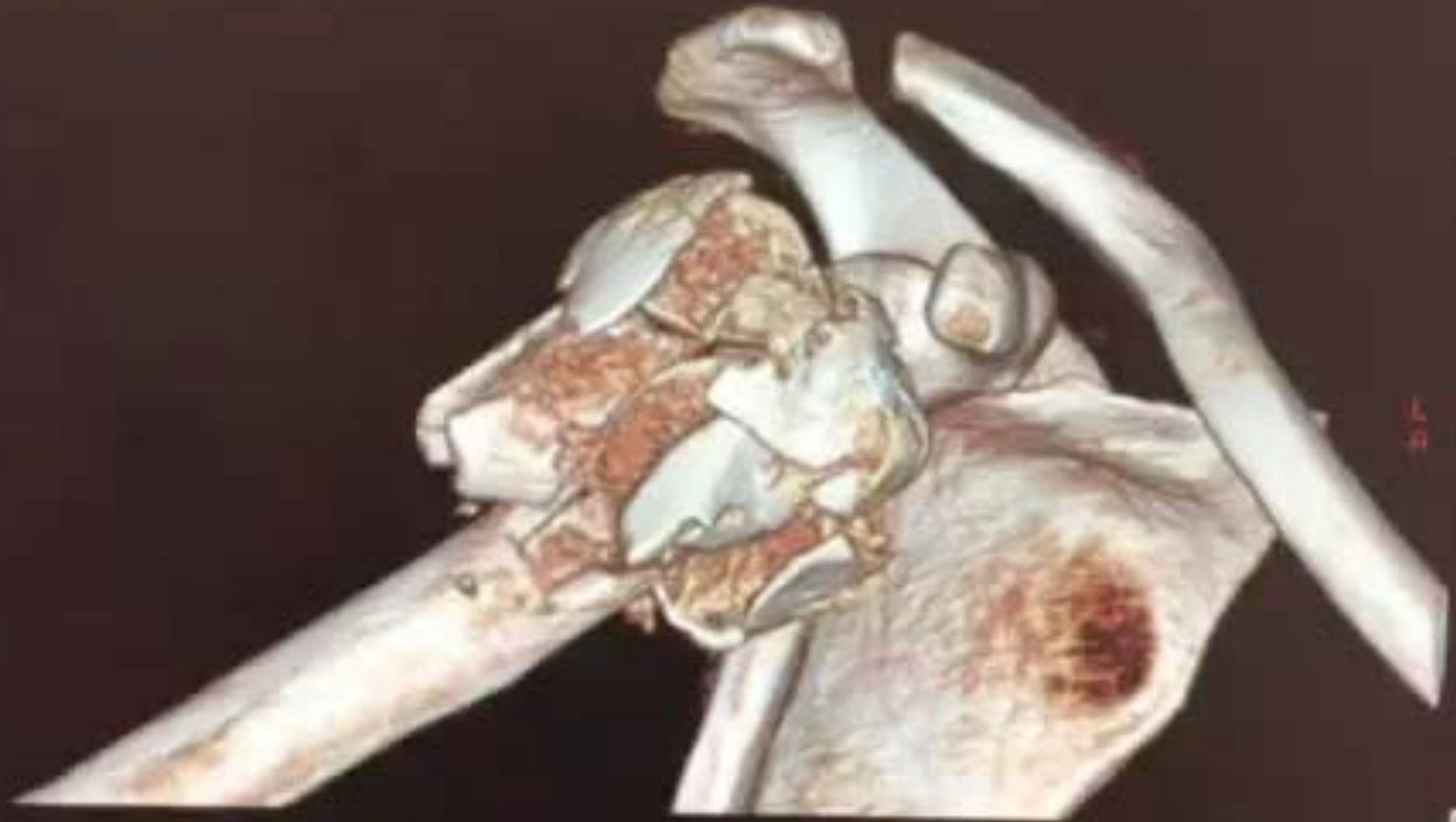

# 29 y/o computer engineer, s/p MCA, bilateral shoulder injury





29 y/o



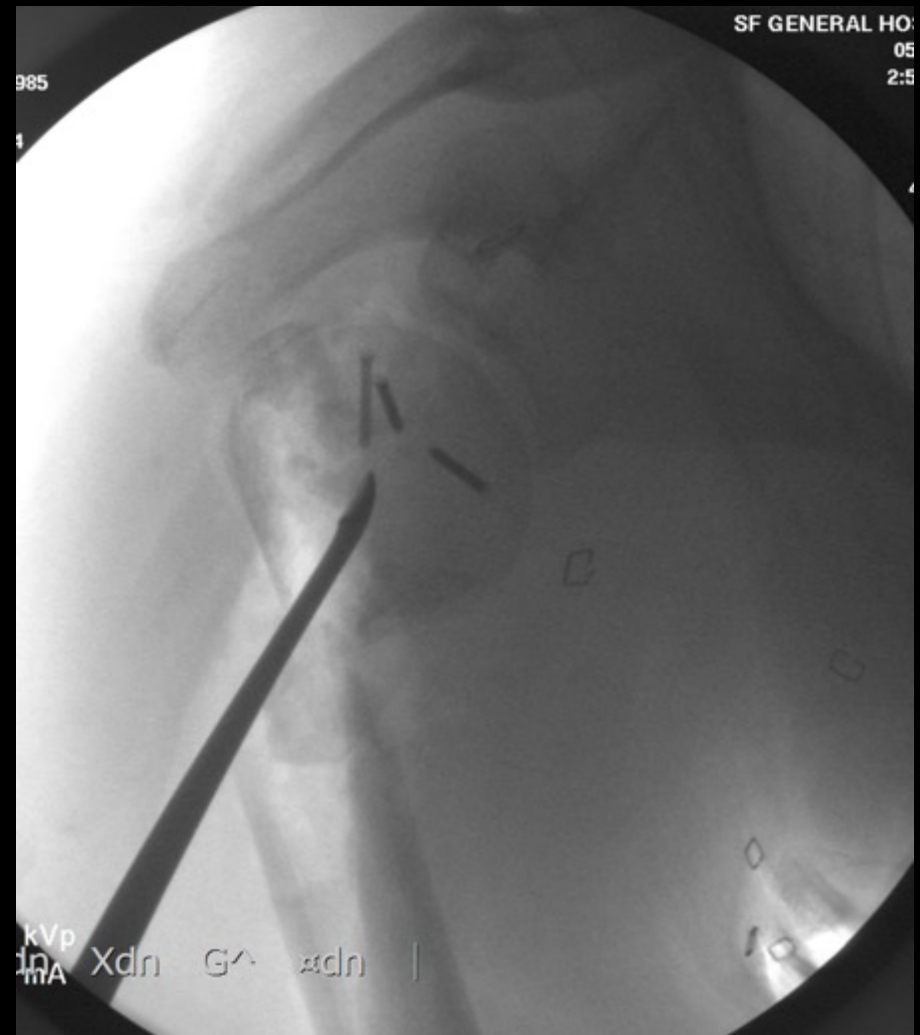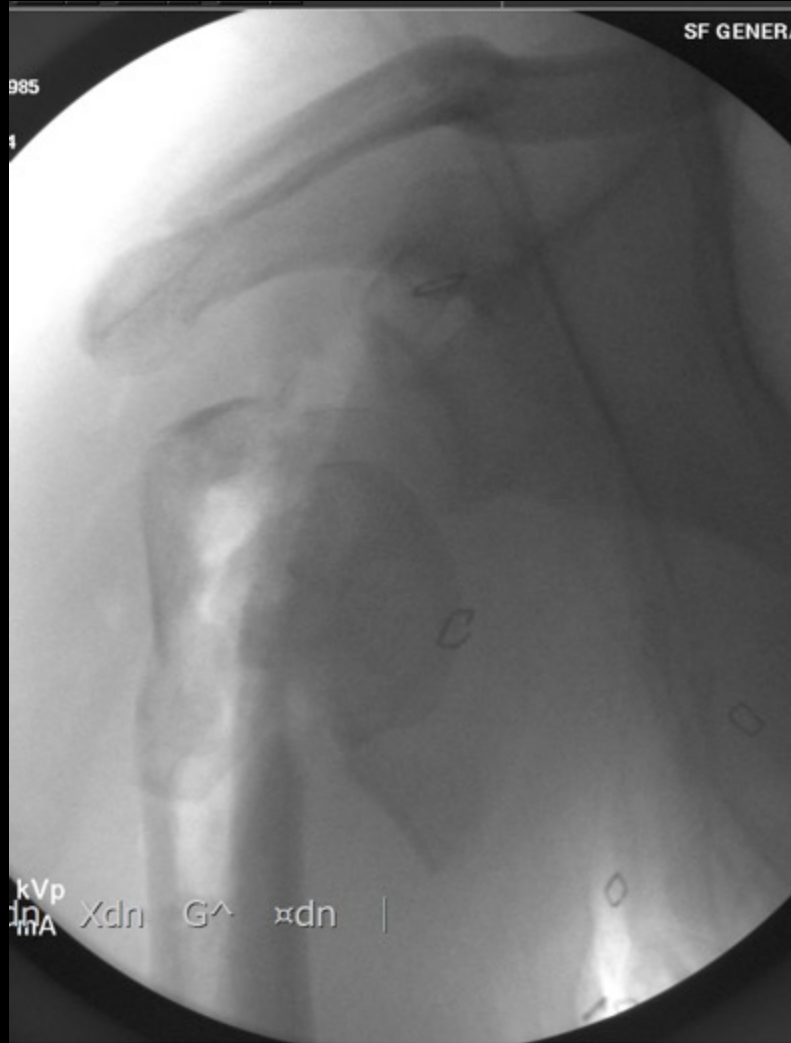1.4

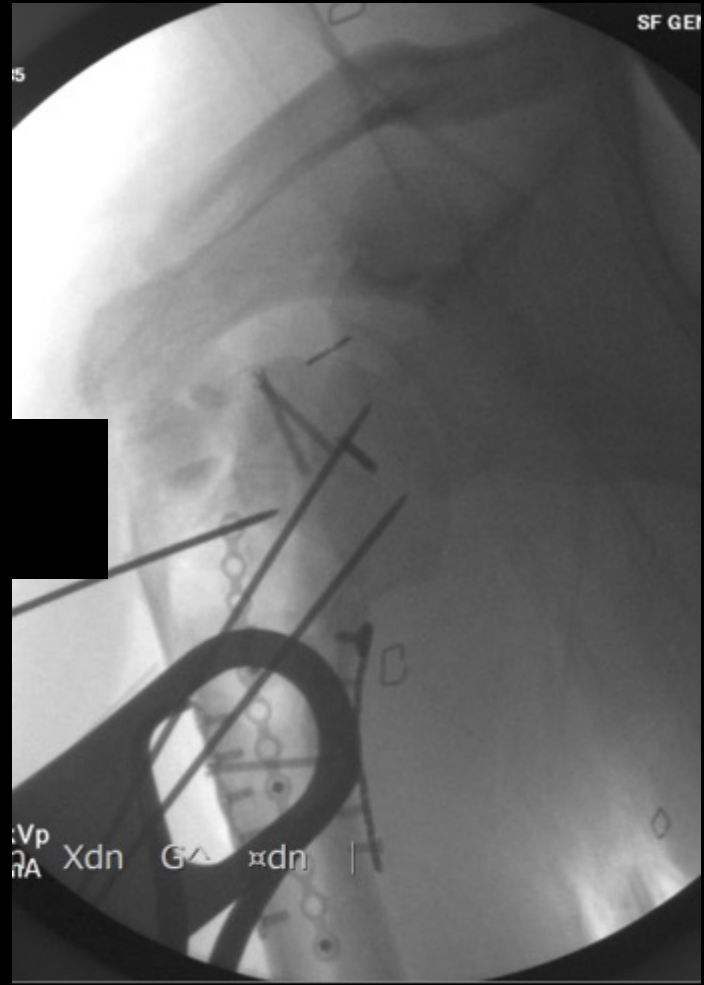
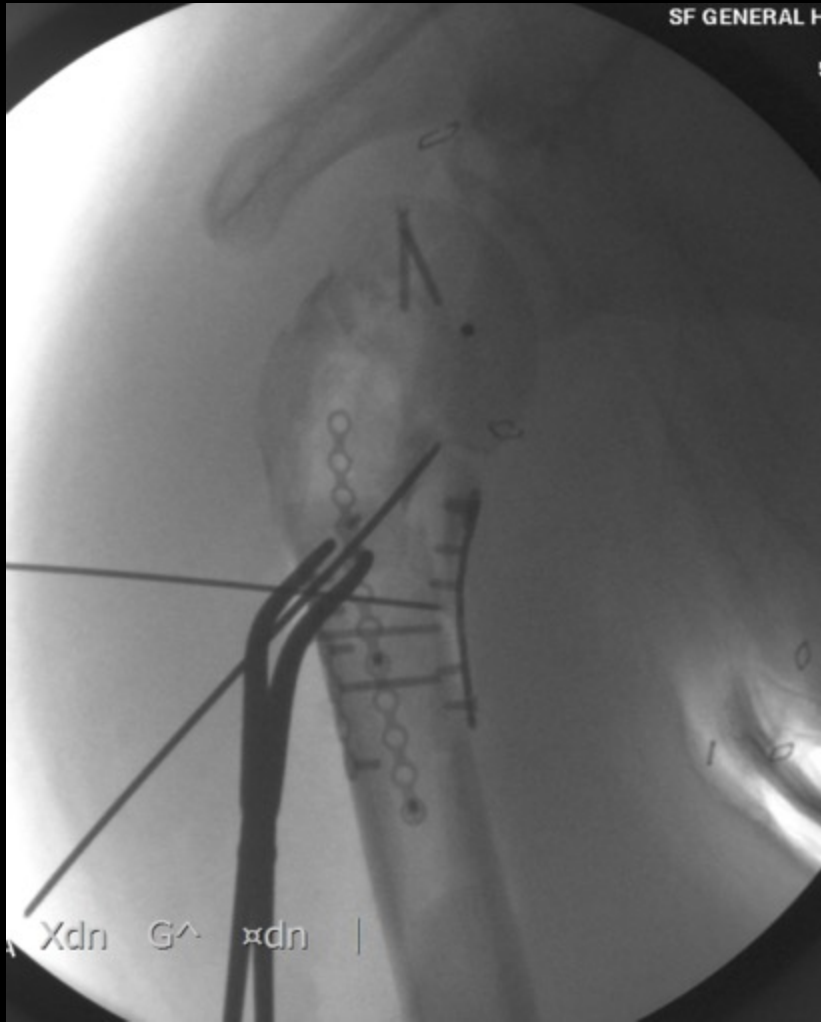
DFOV

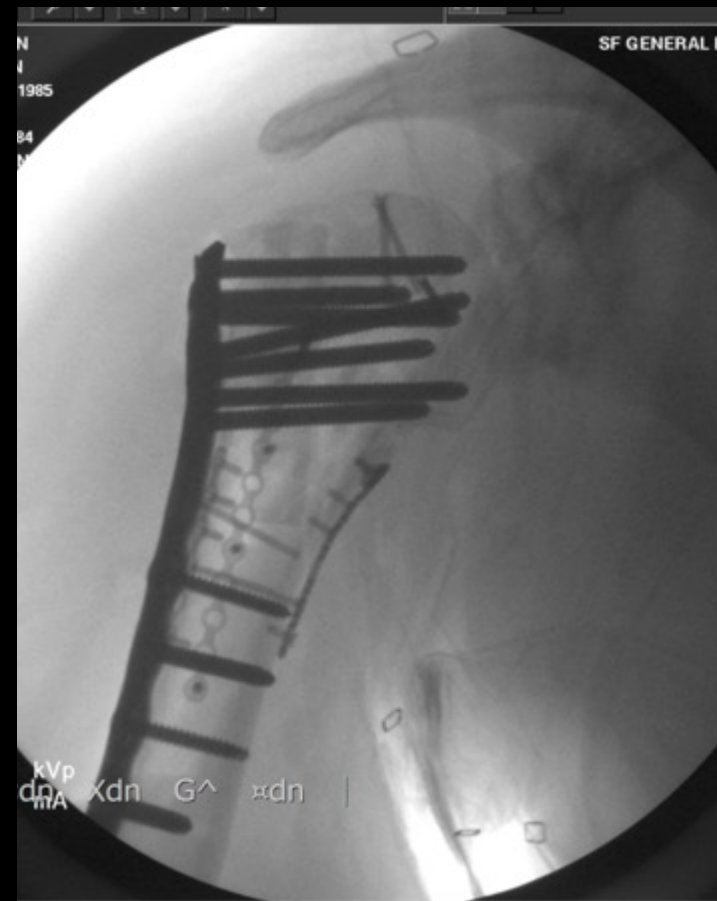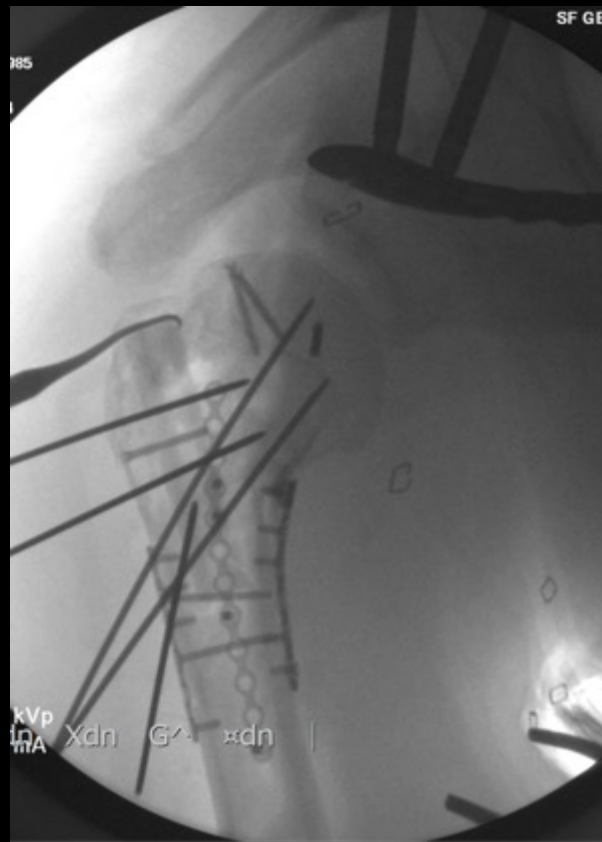
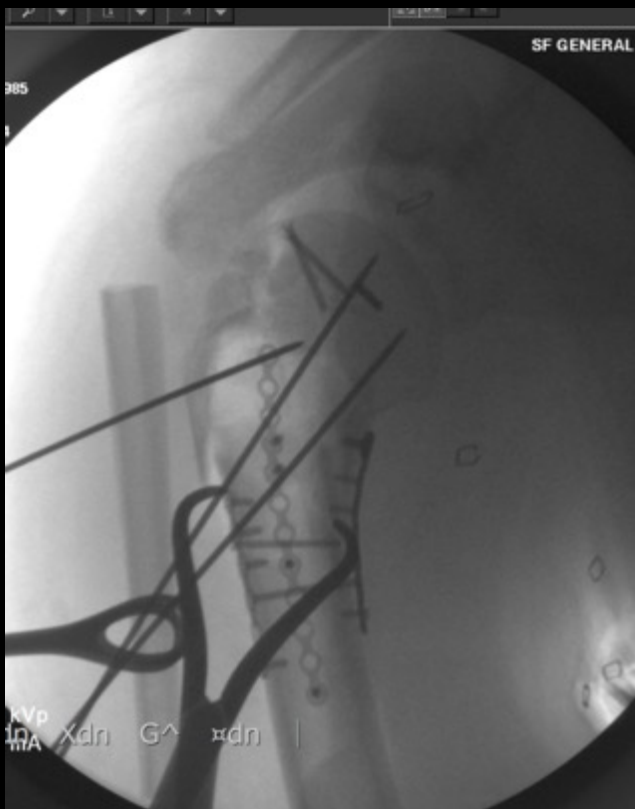TILT:

SHOULDER  
Hospital

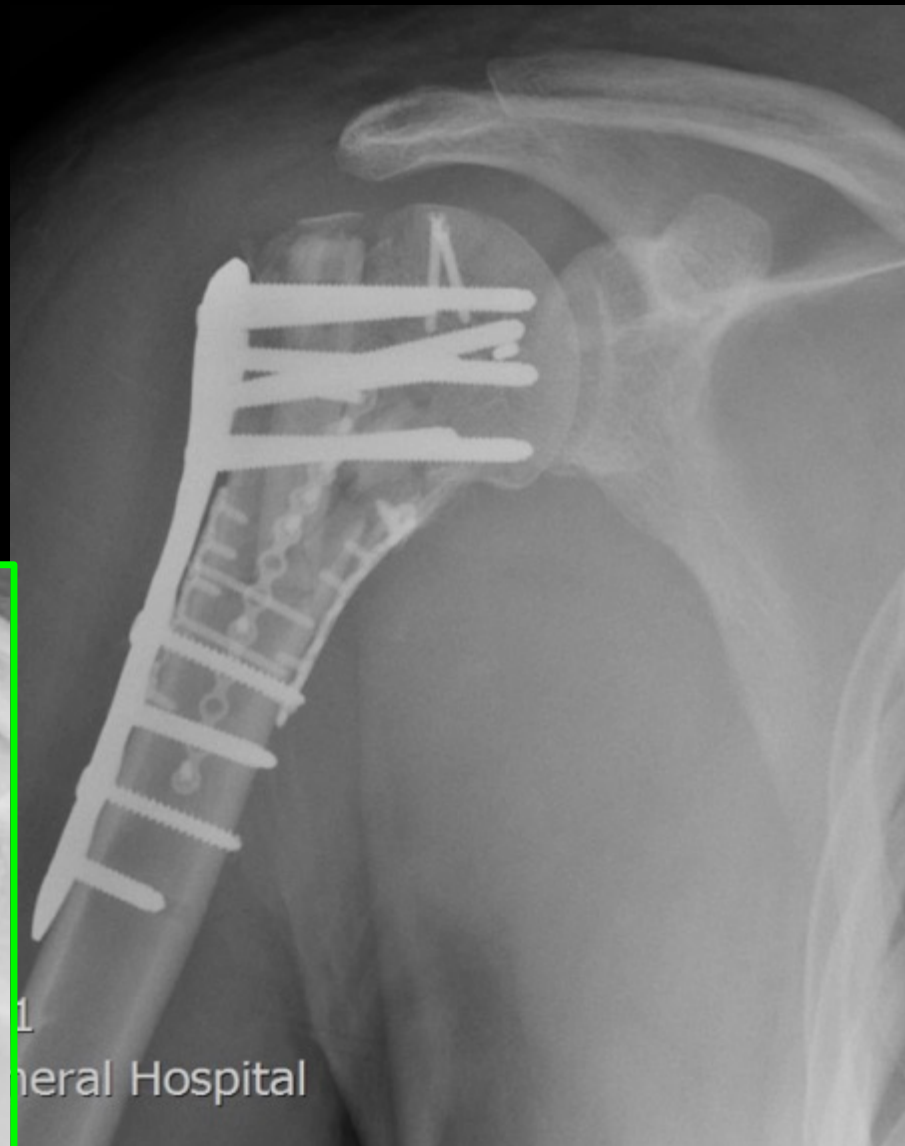
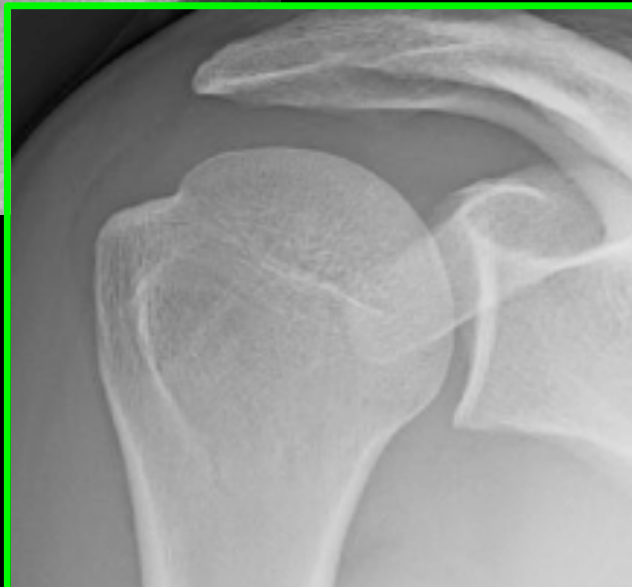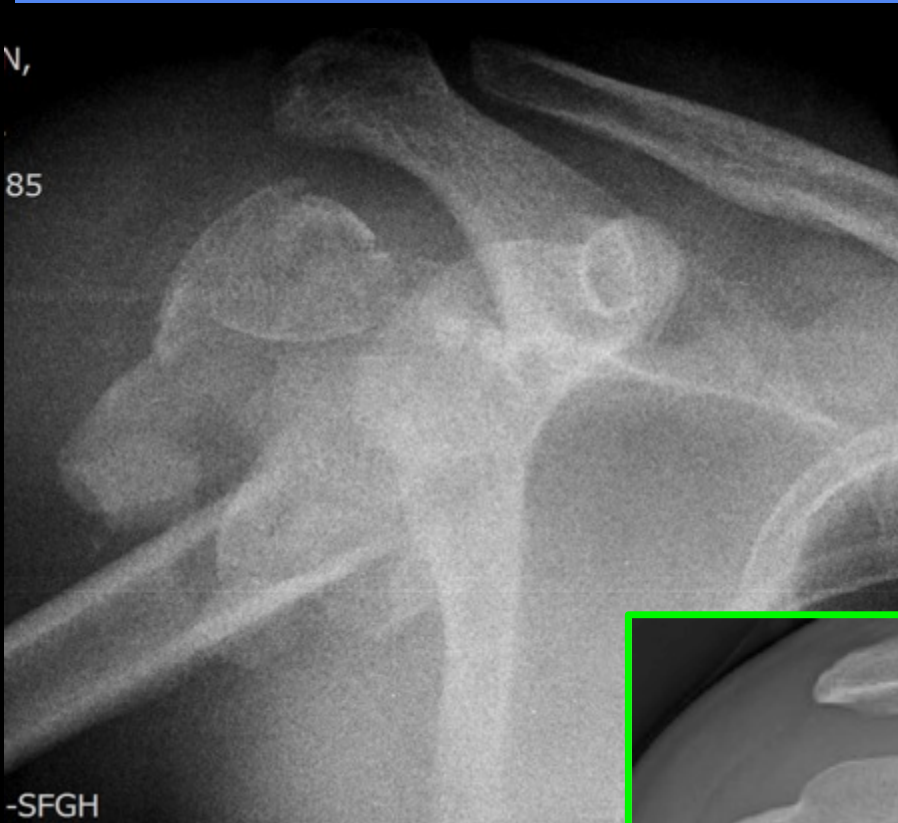CT EXTREM UPPER RT WO CONTR







# 29 y/o, Postop

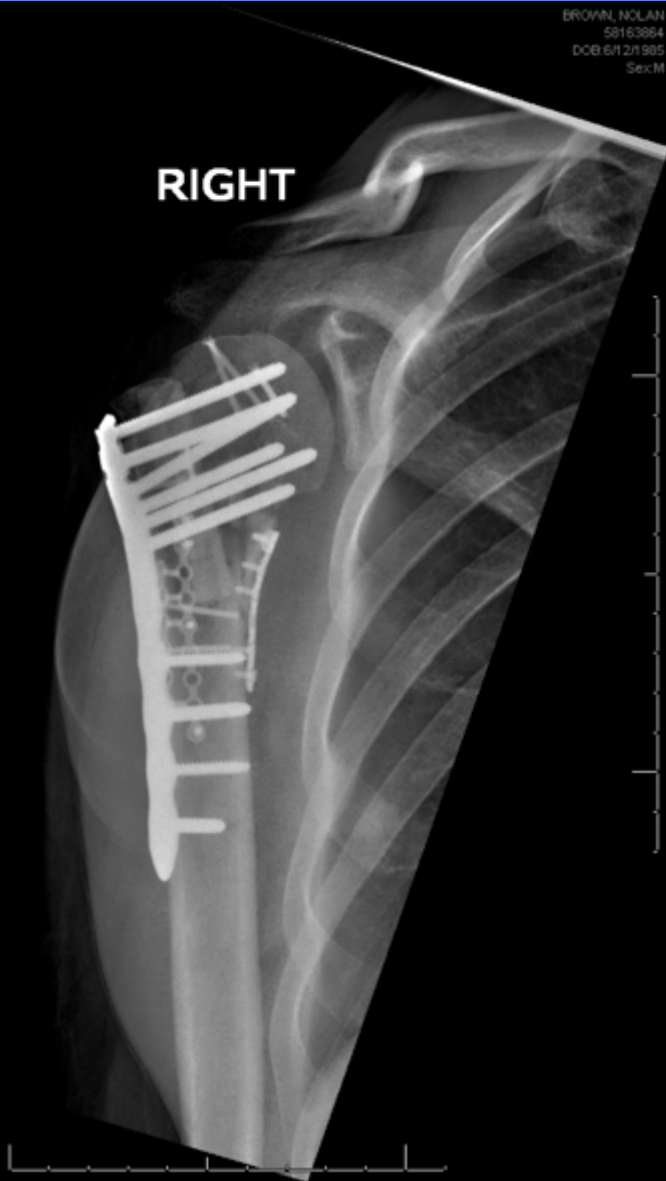

# 4.5 months postop

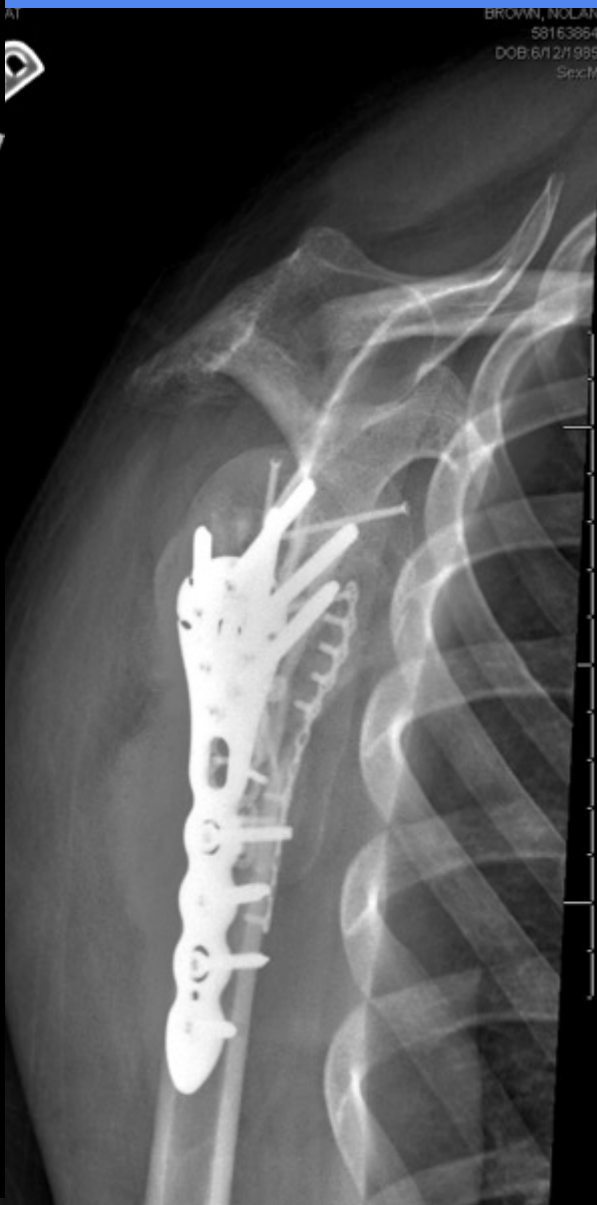AX LAT

BROWN, NOLAN  
58163884  
DOB: 6/12/1985  
Sex: M

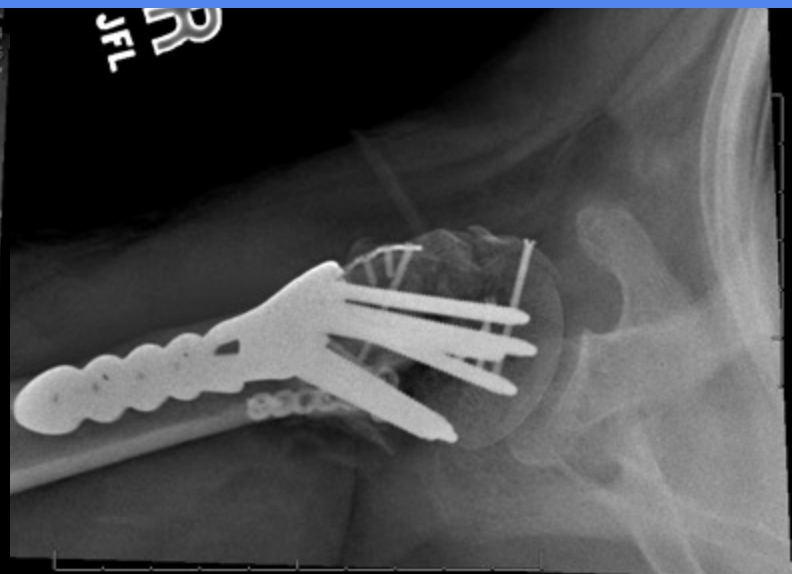
RIGHT

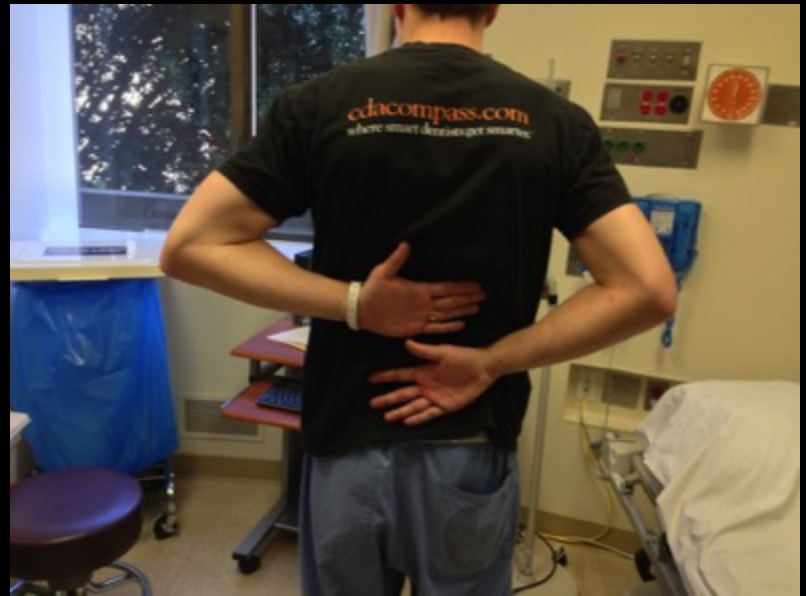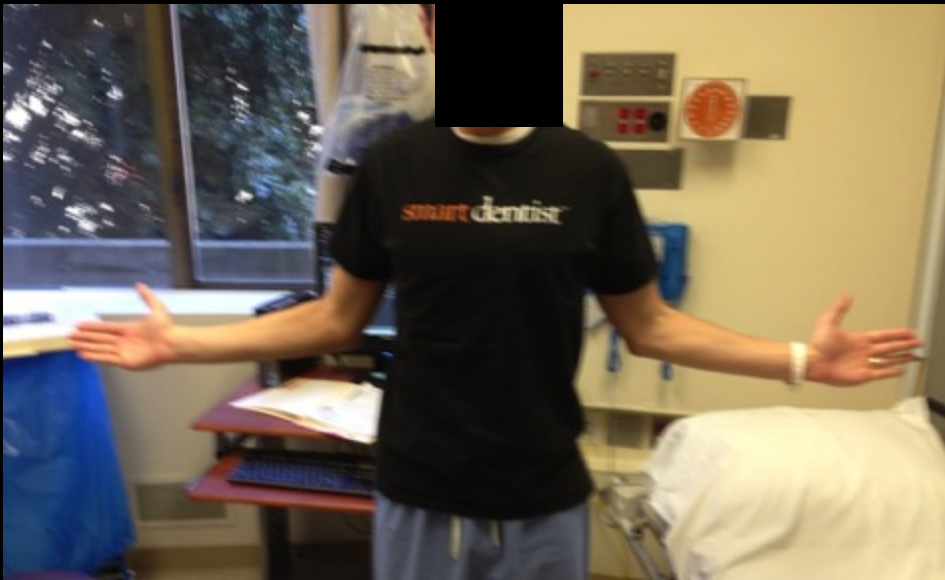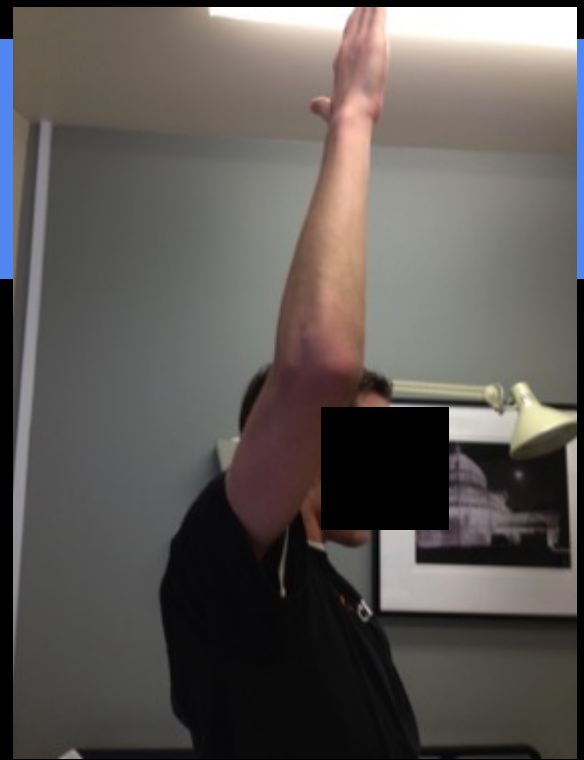


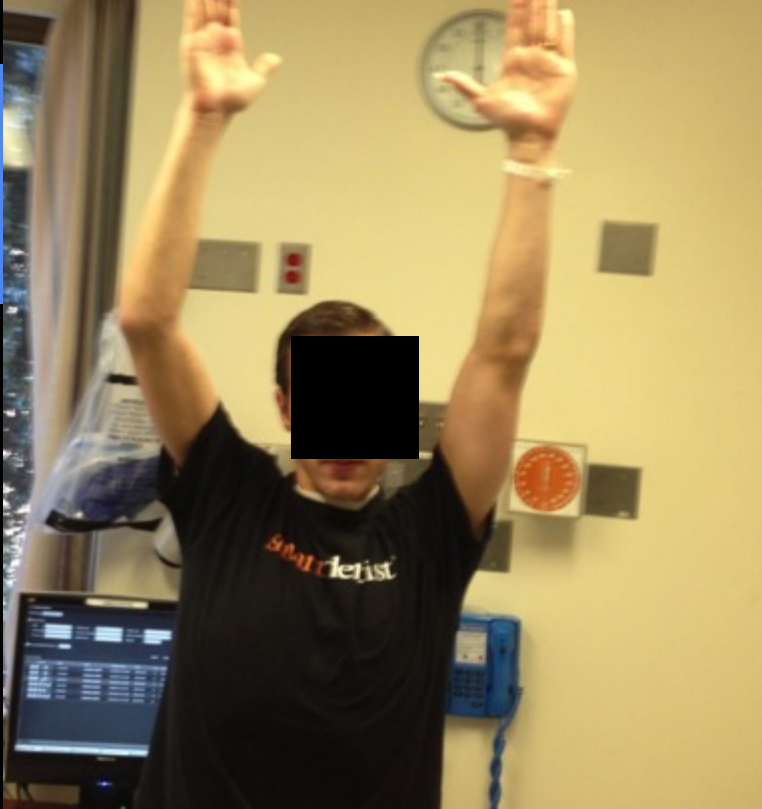BROWN, NOLAN  
58163884  
DOB: 6/12/1985  
Sex: M

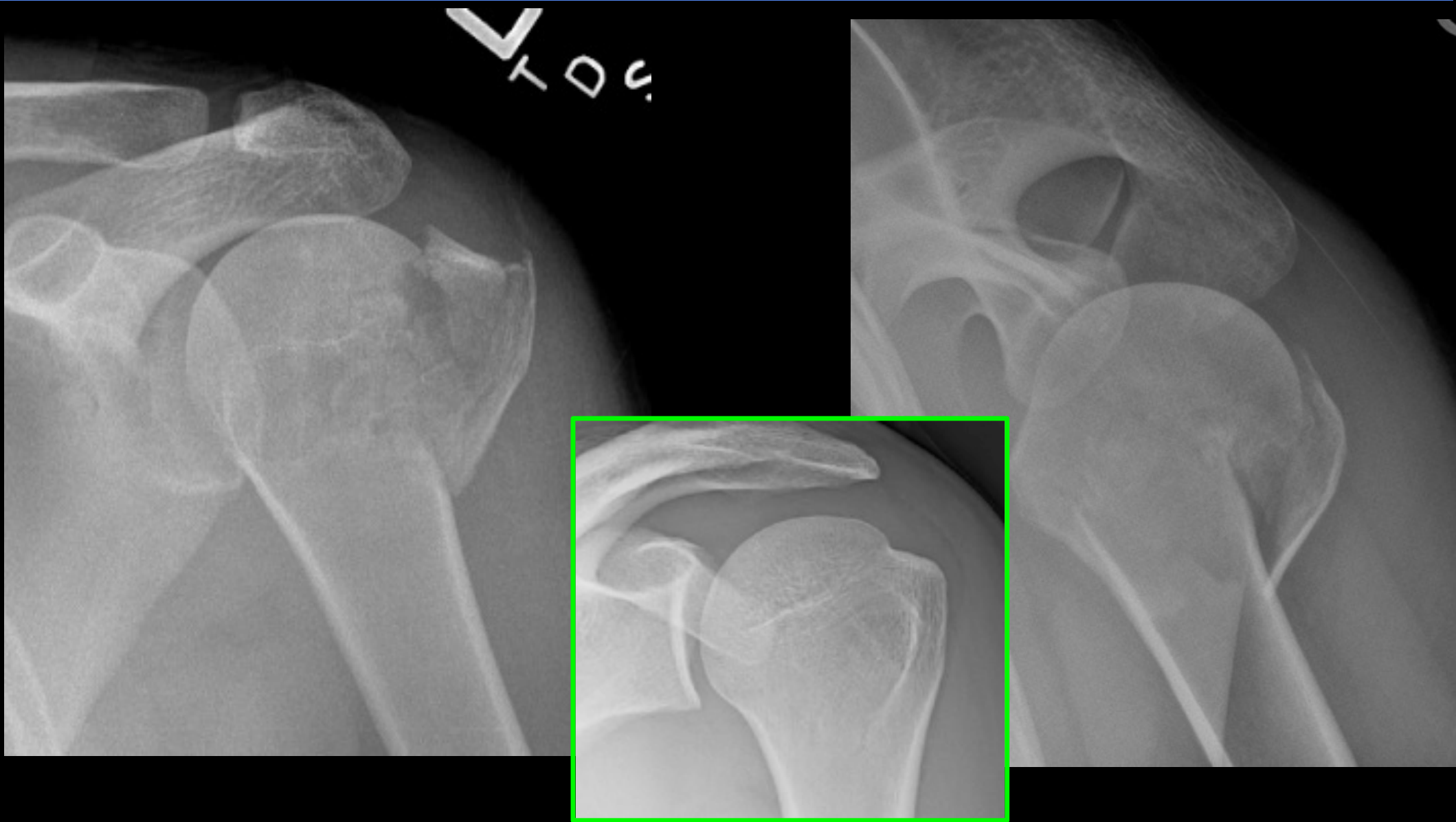


R  
JFL

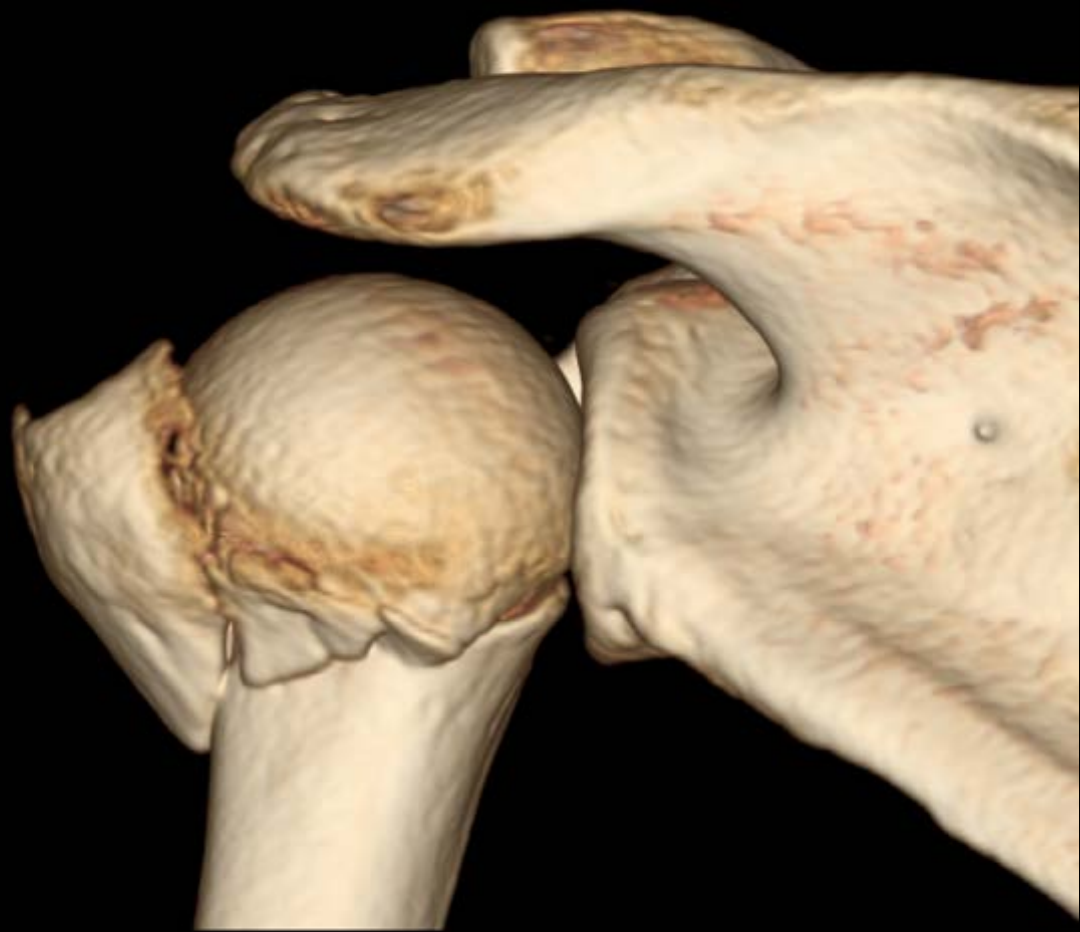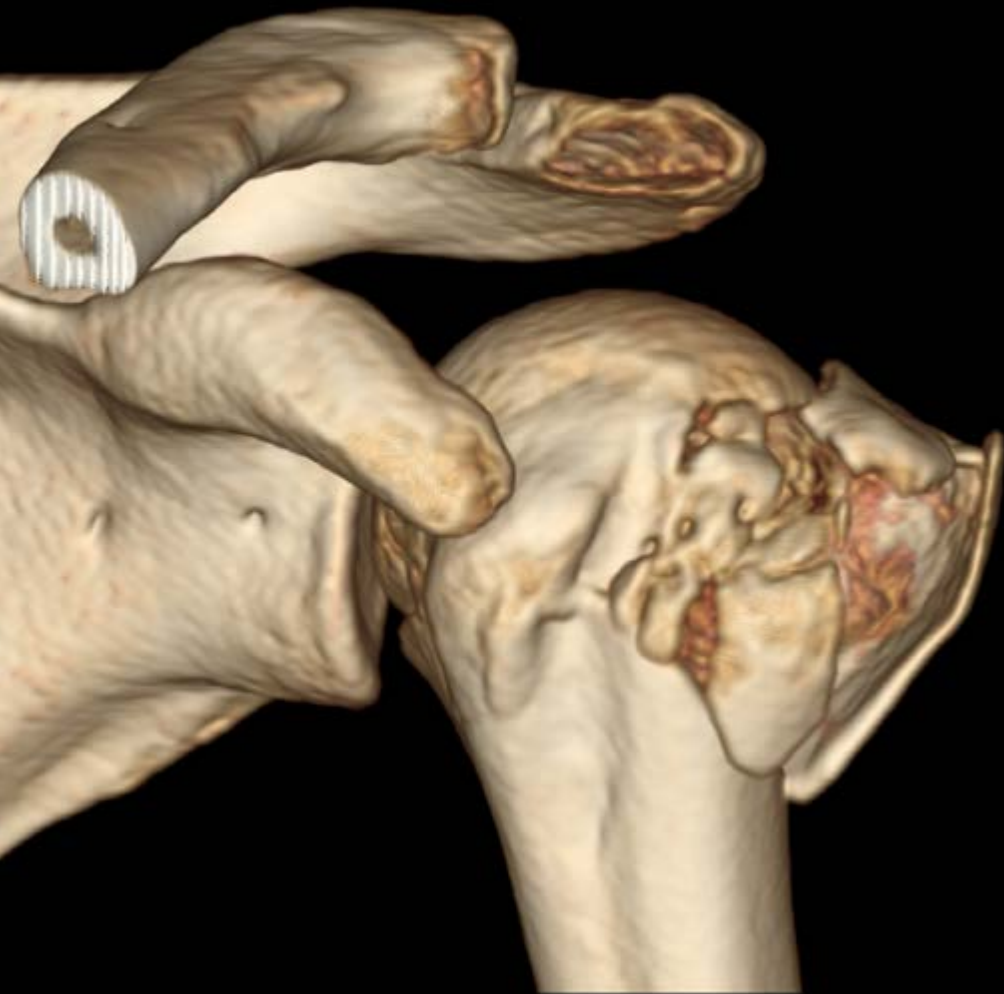



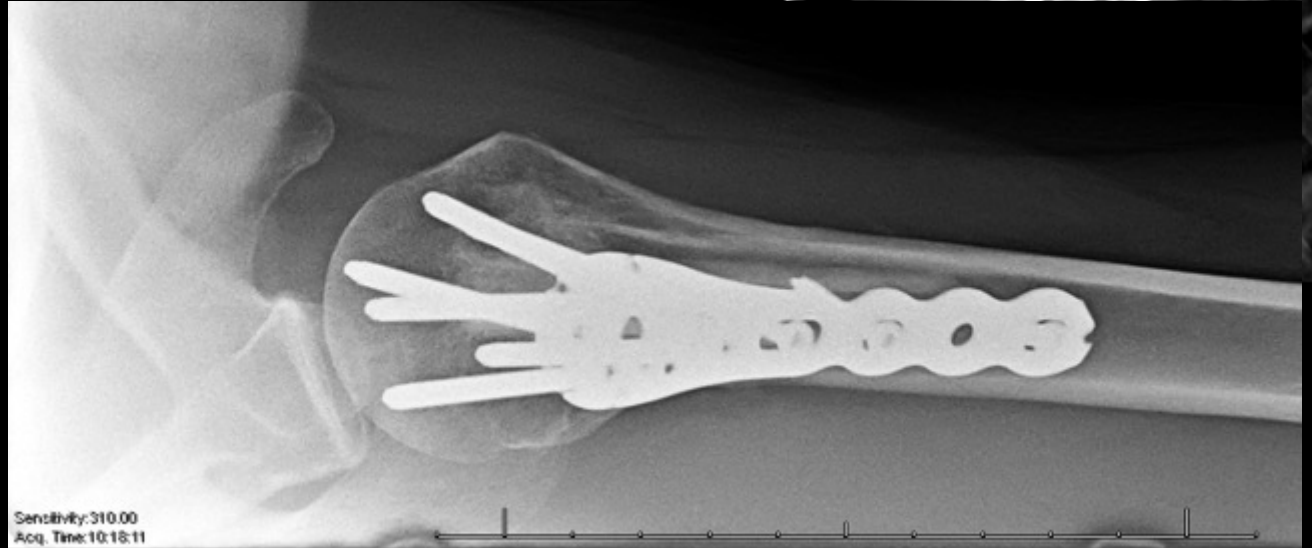
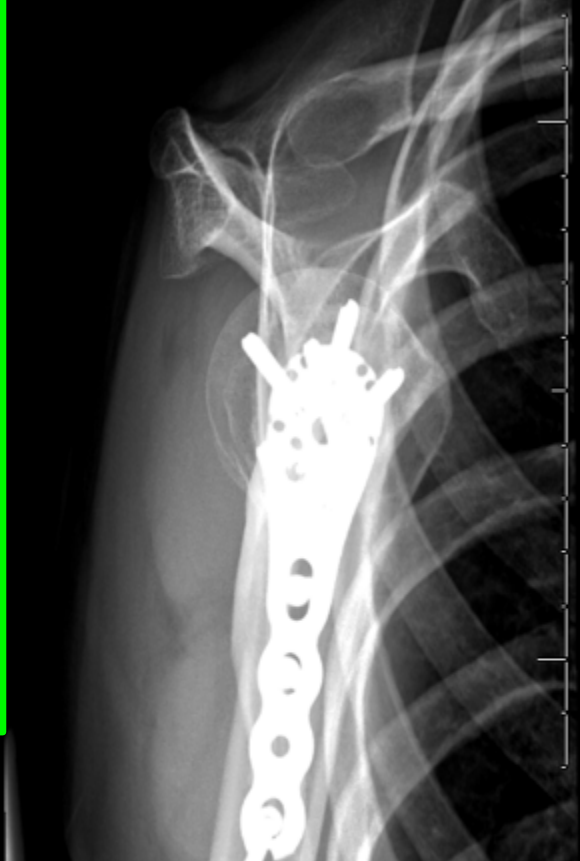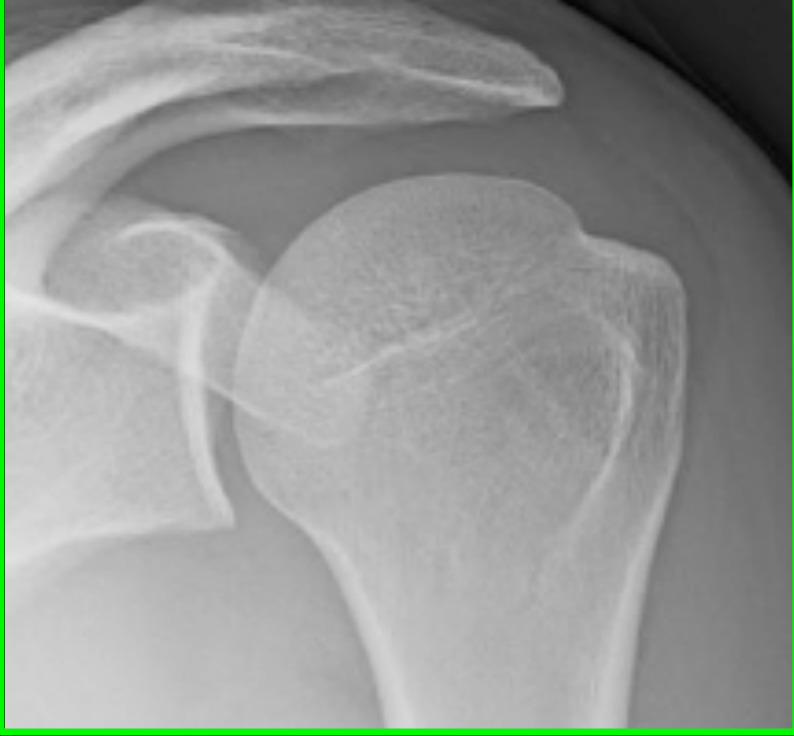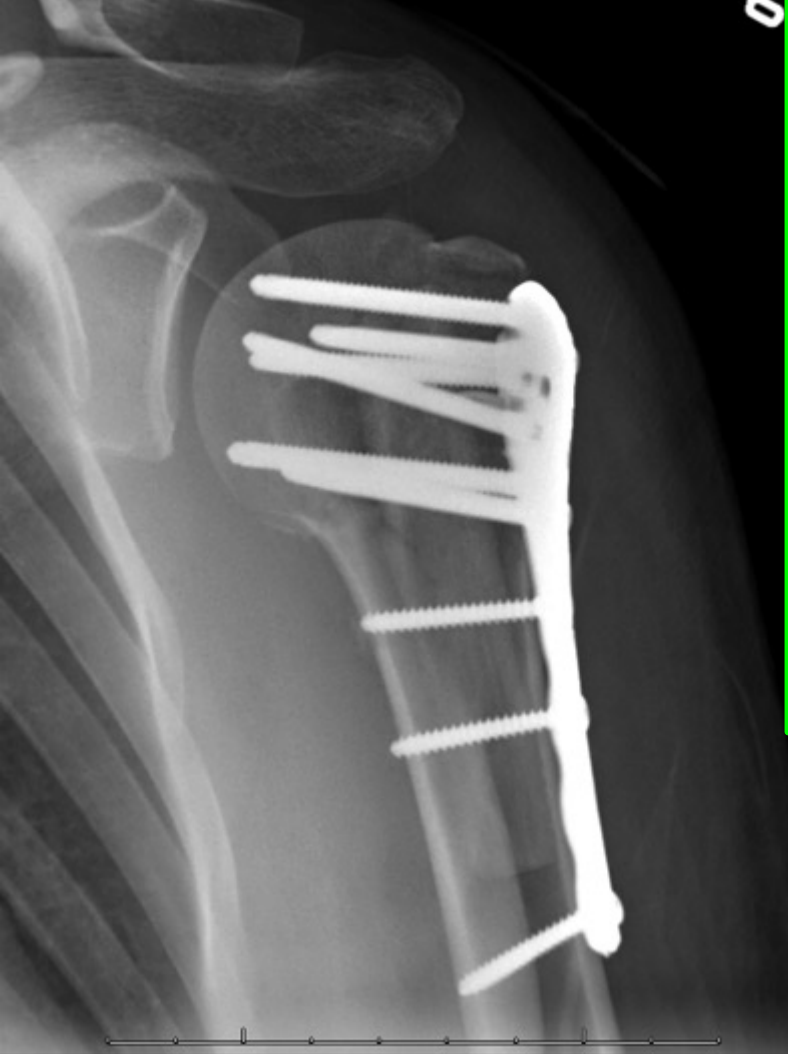30 y/o

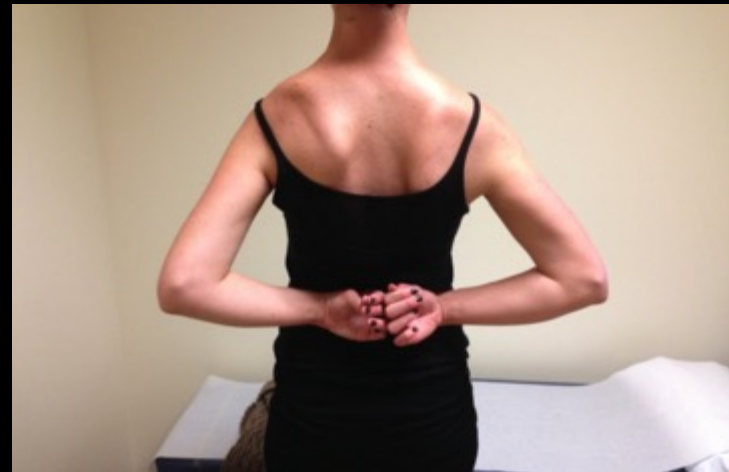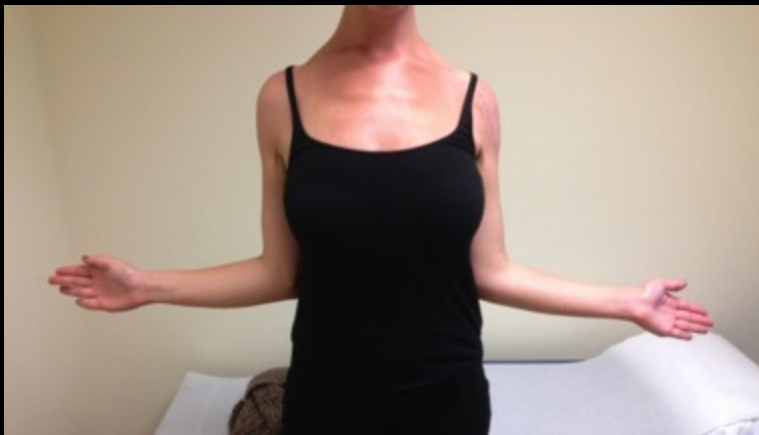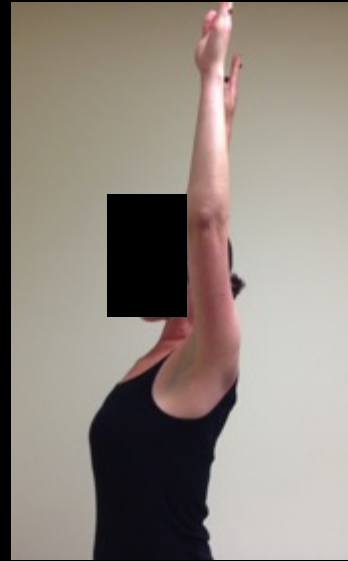


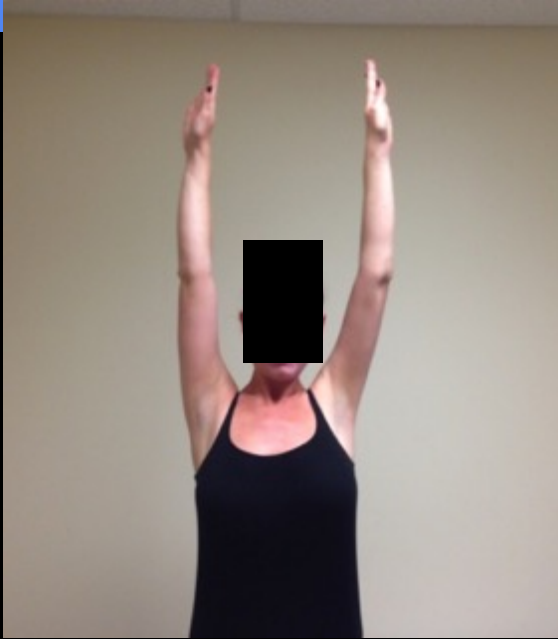




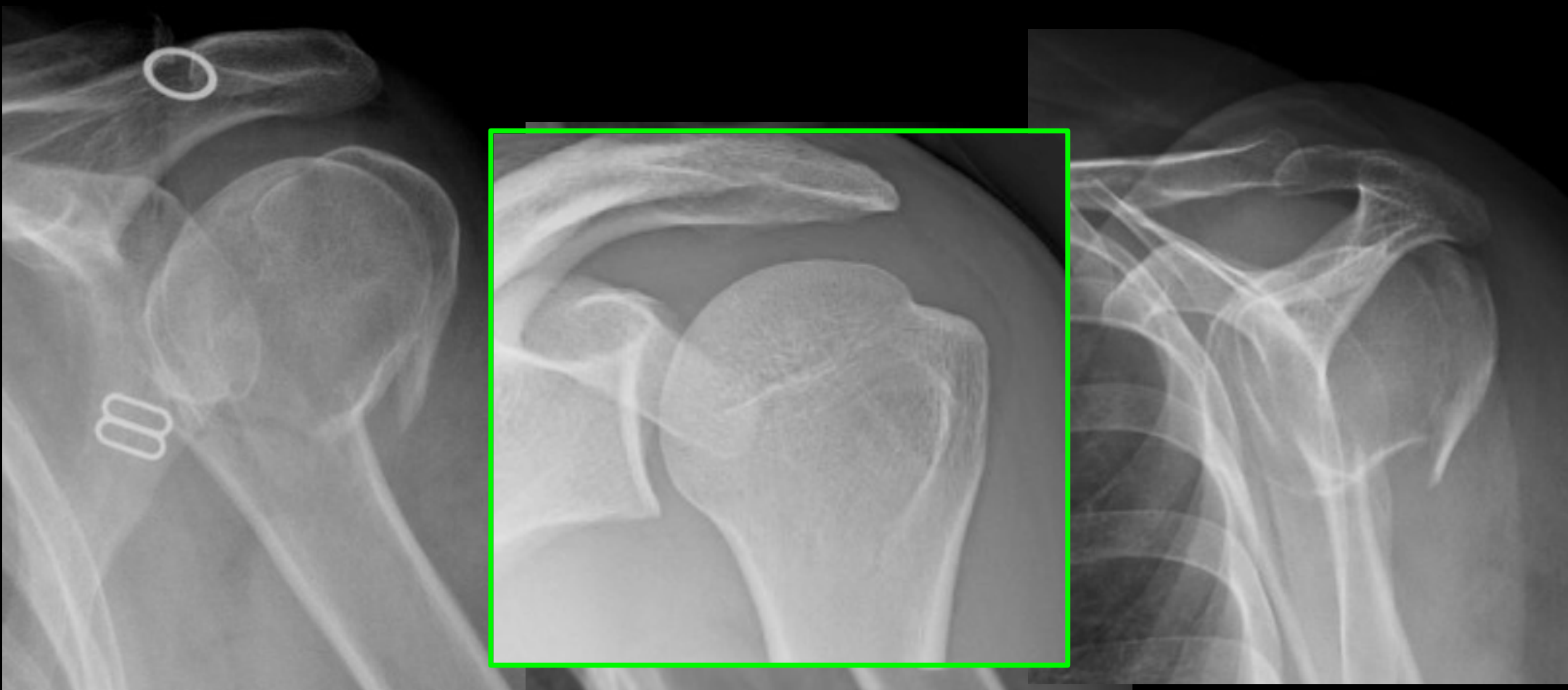
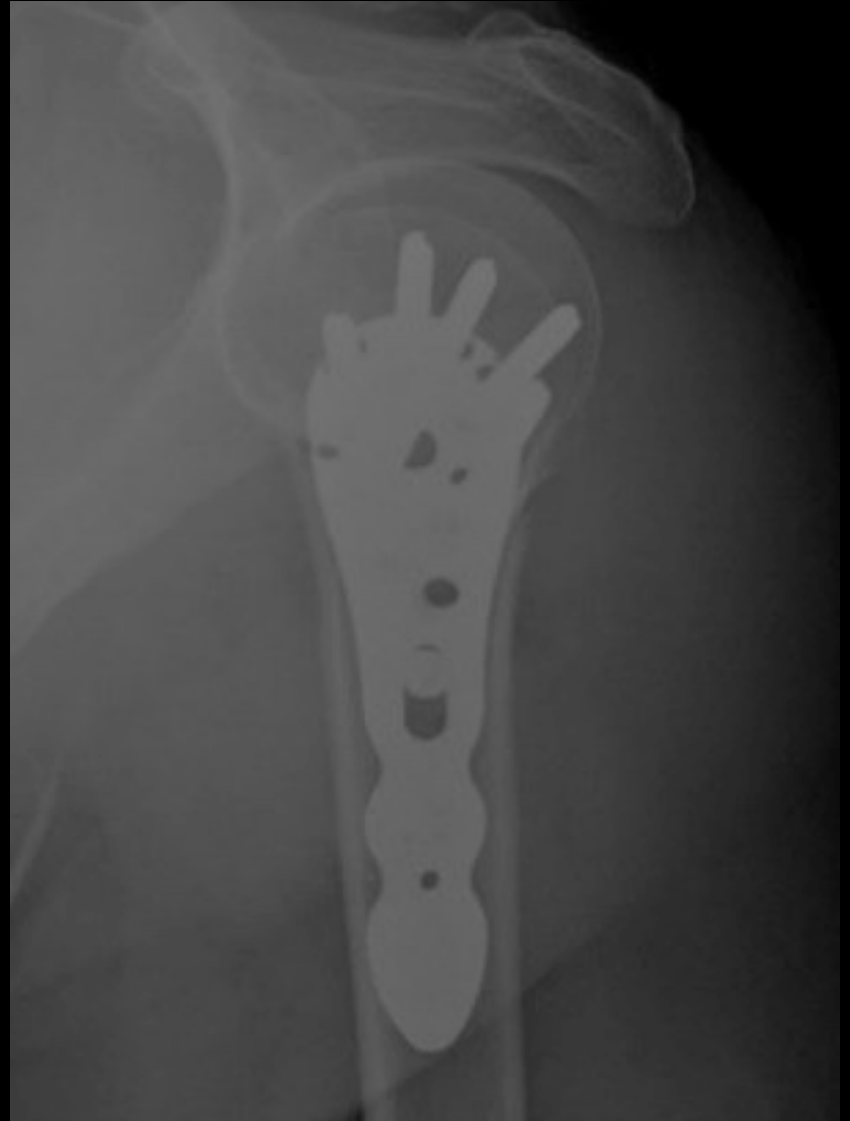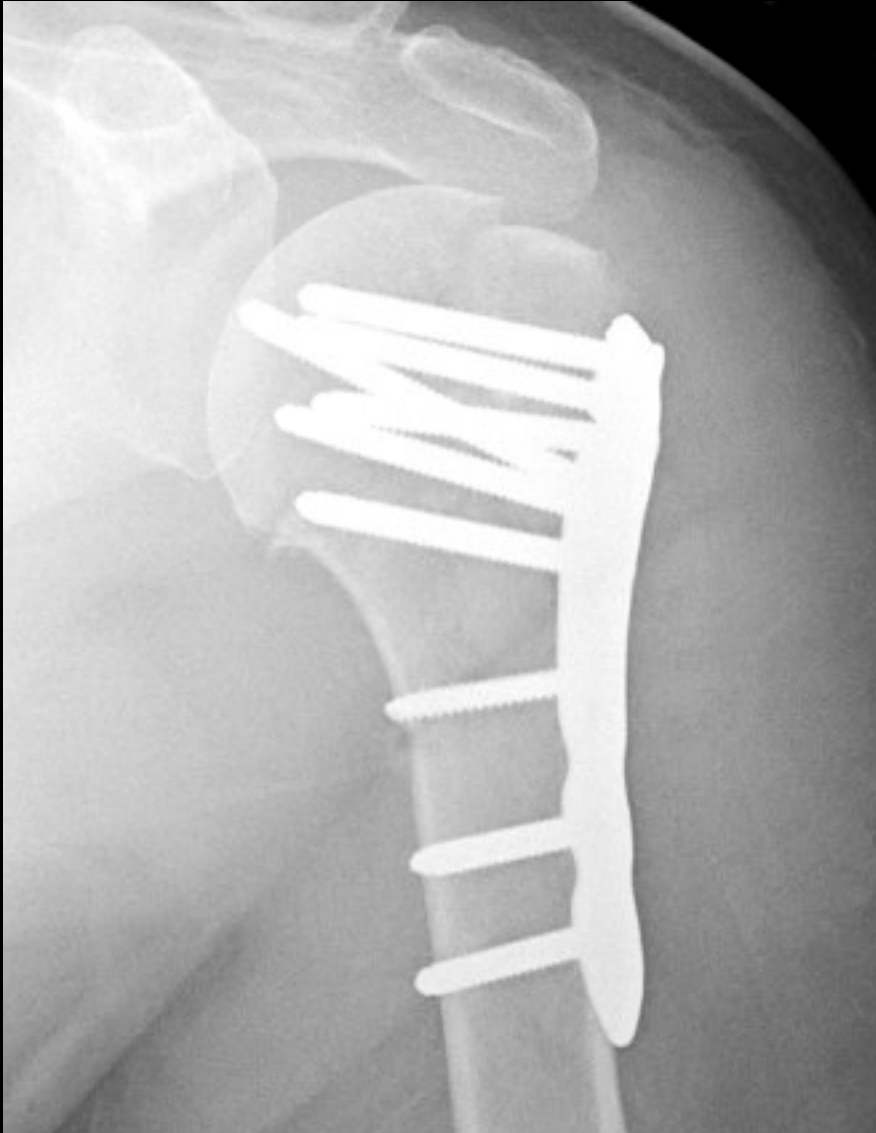
# 3 months



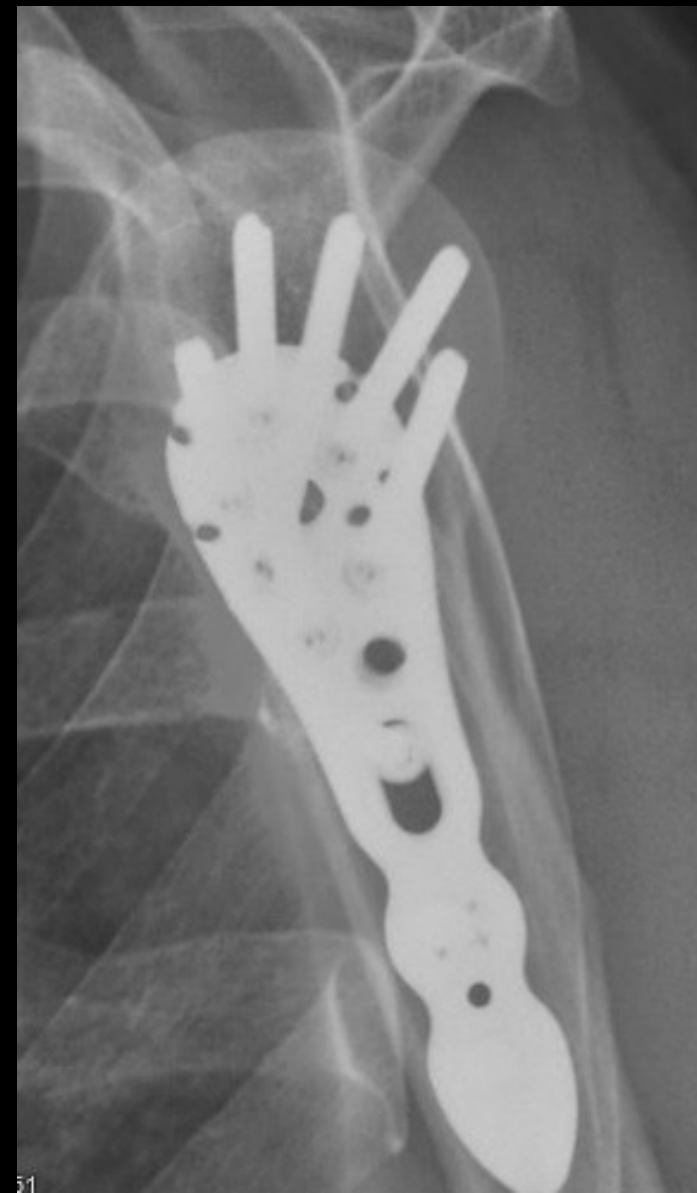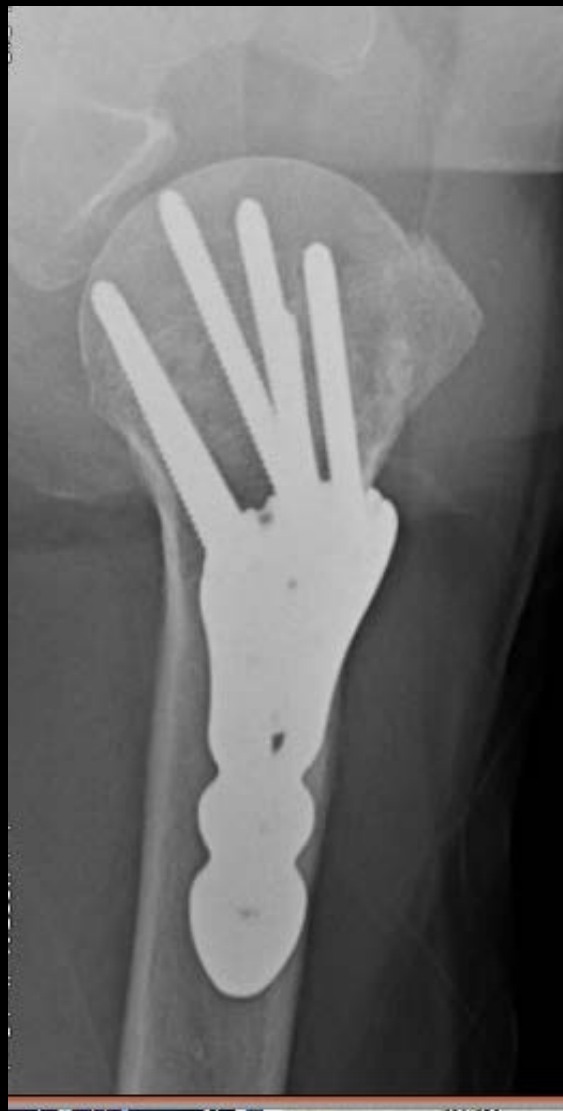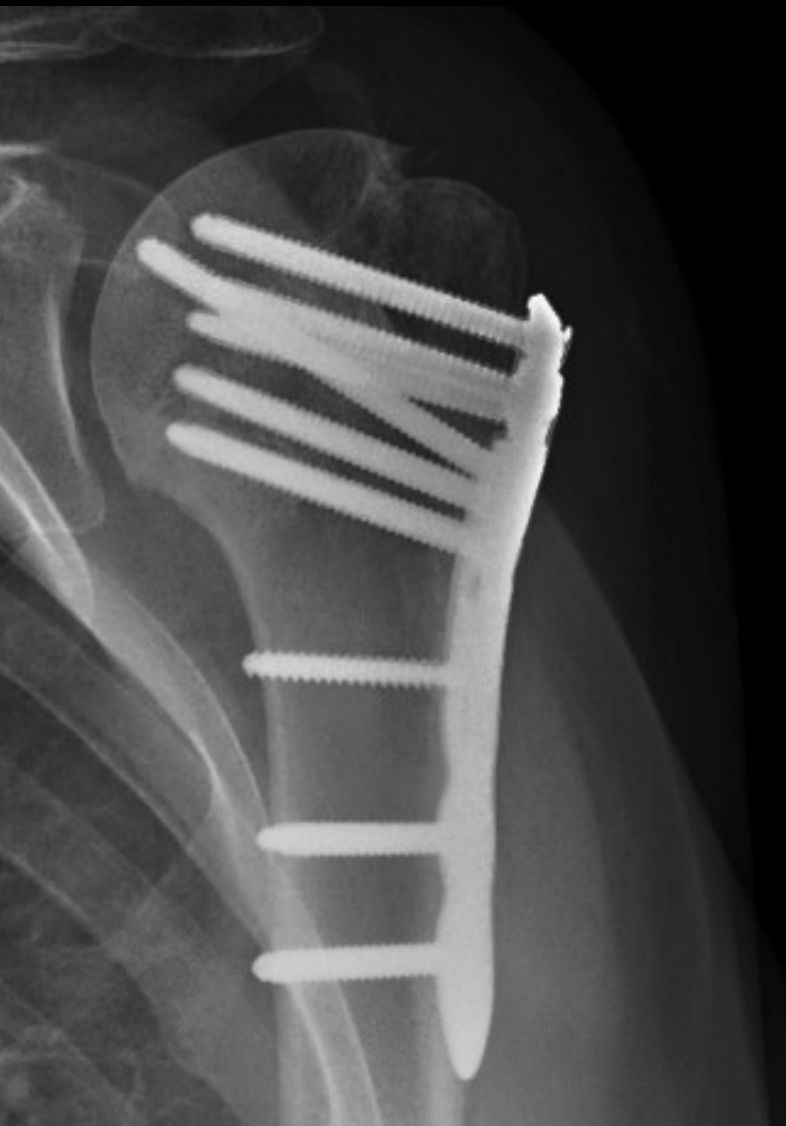58 y/o female, s/p fall tripped over a dog



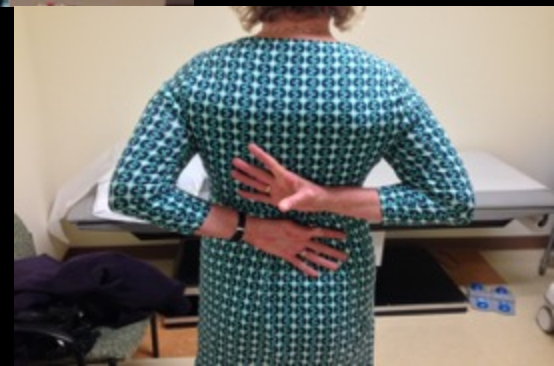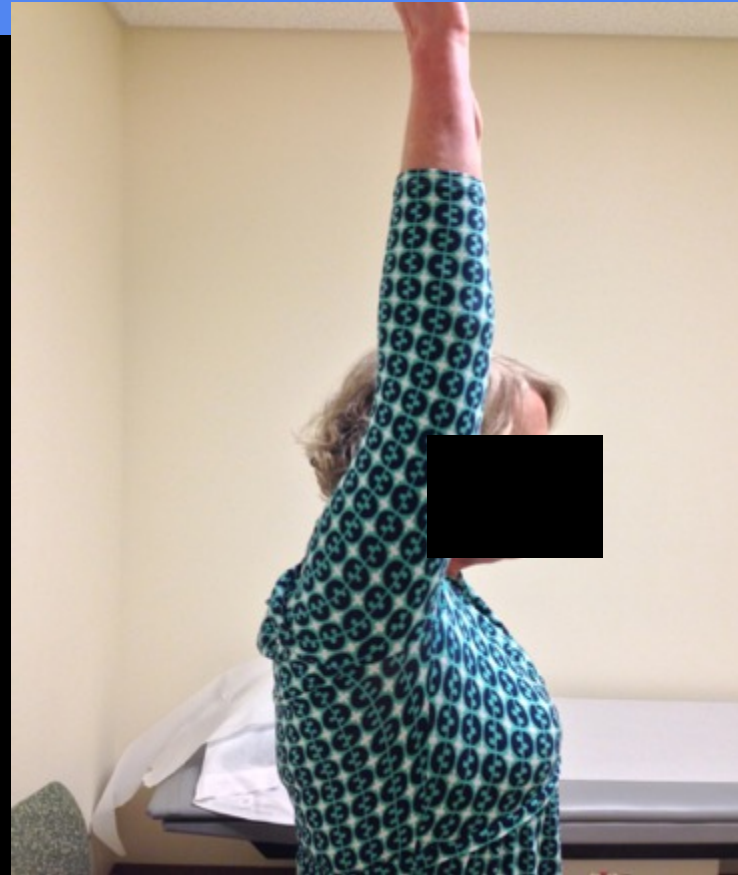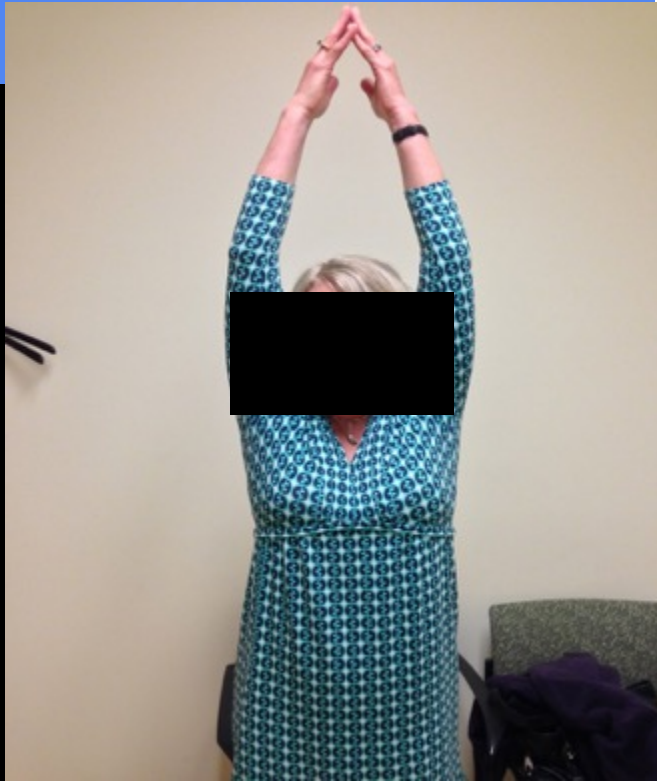58 y/o female



58 y/o female

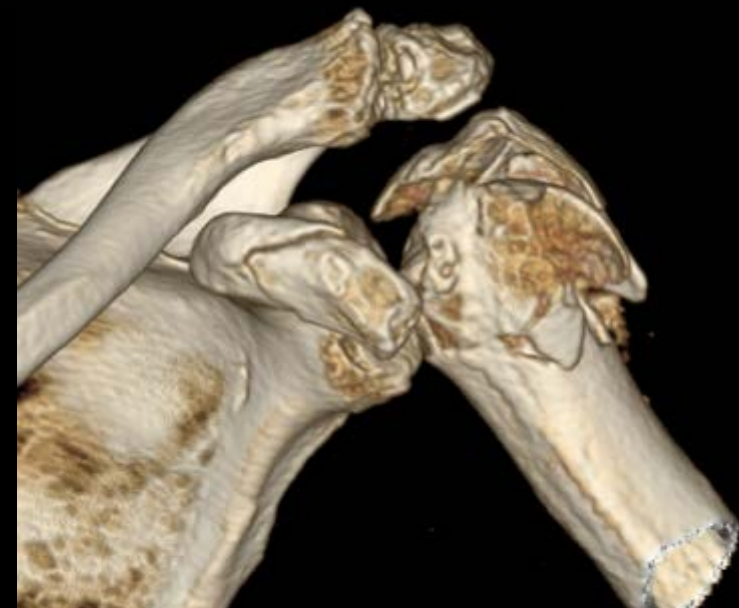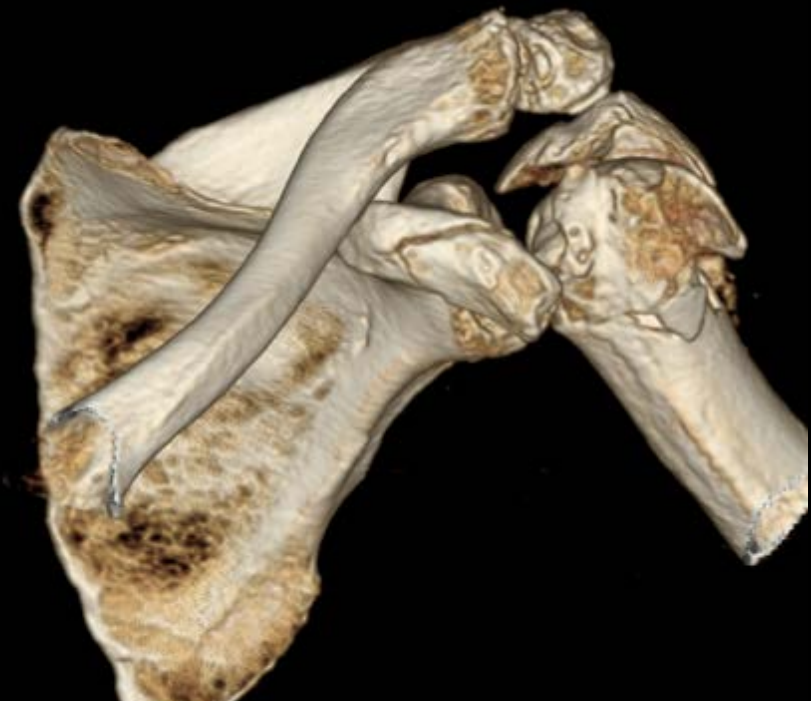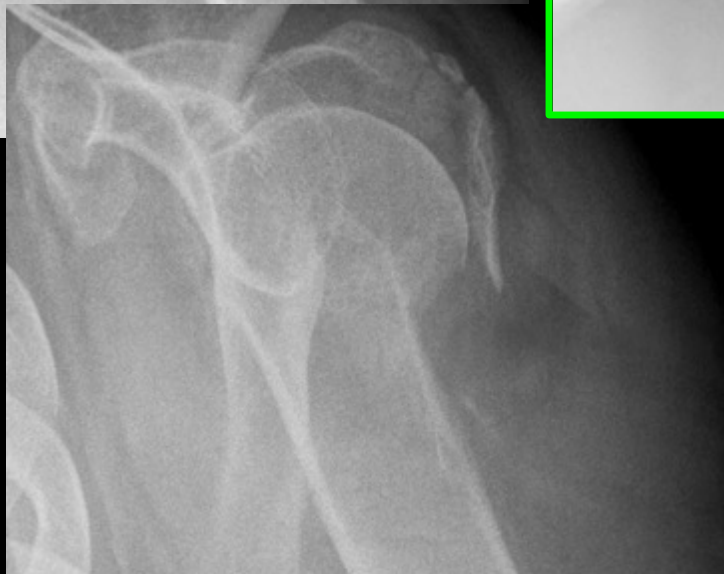


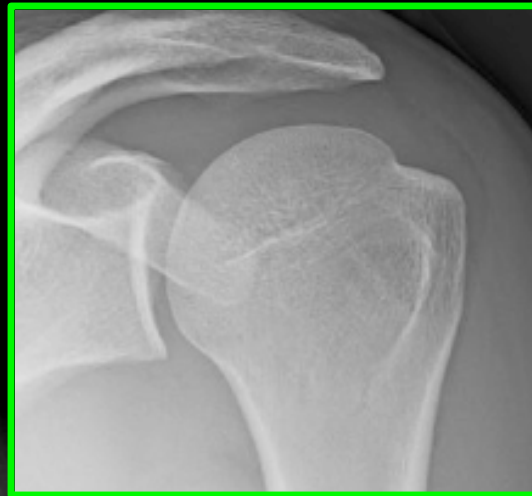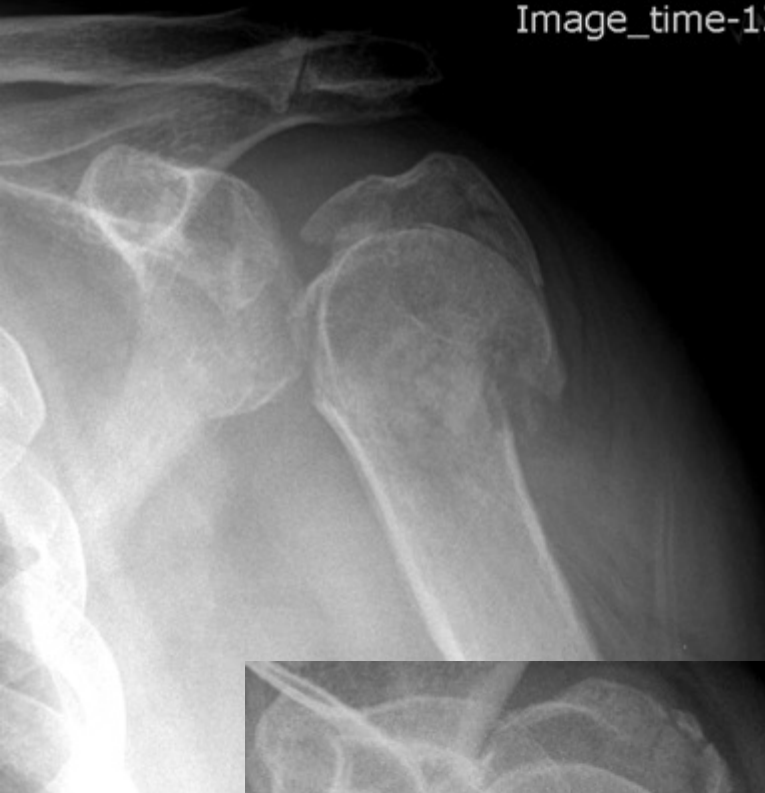# 58 y/o female

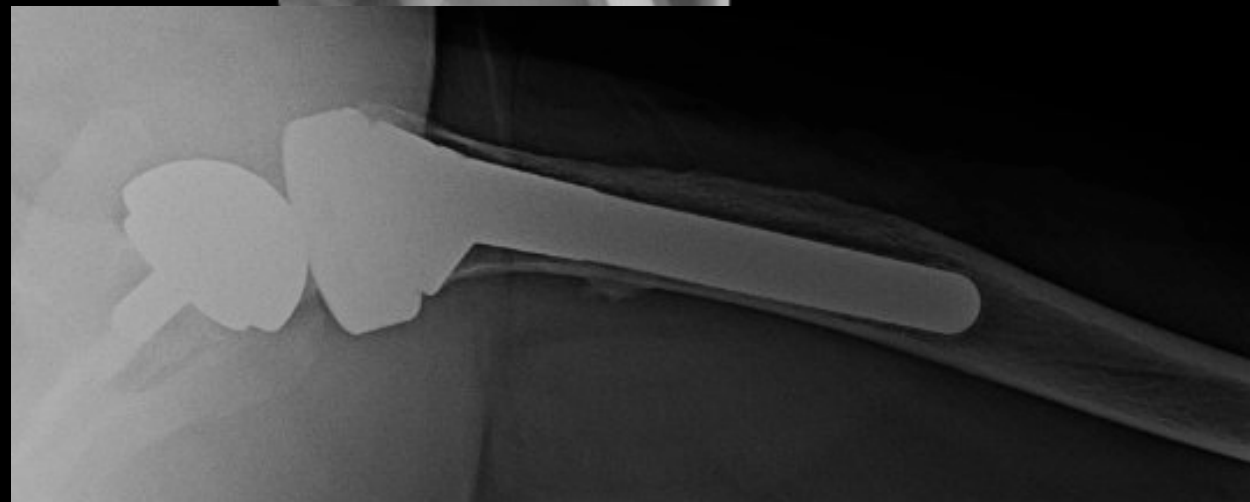
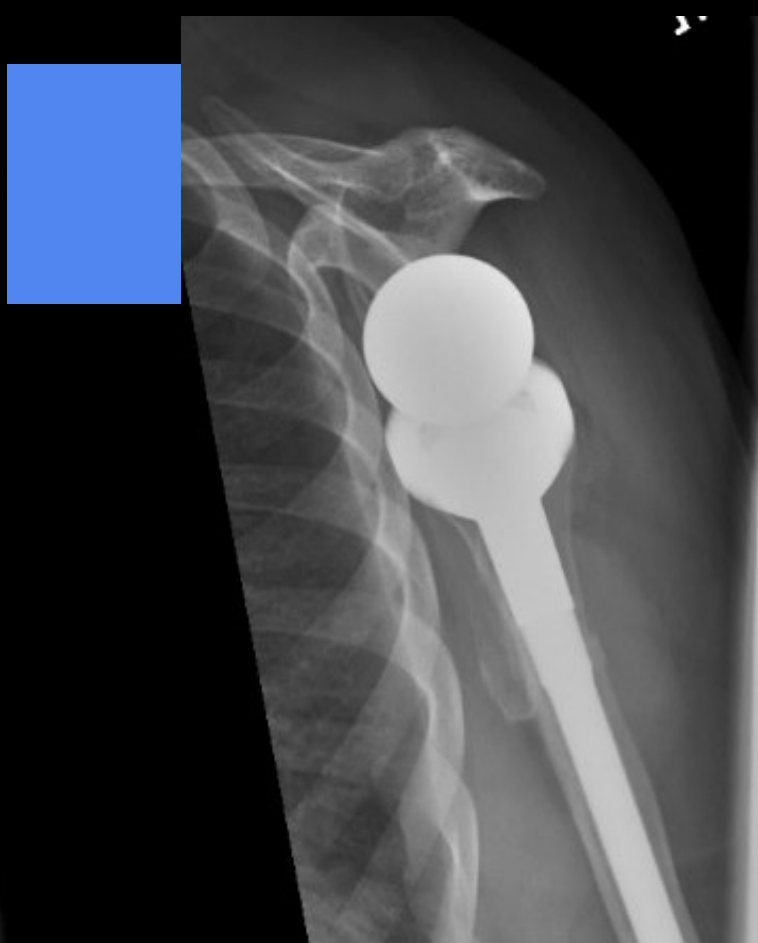
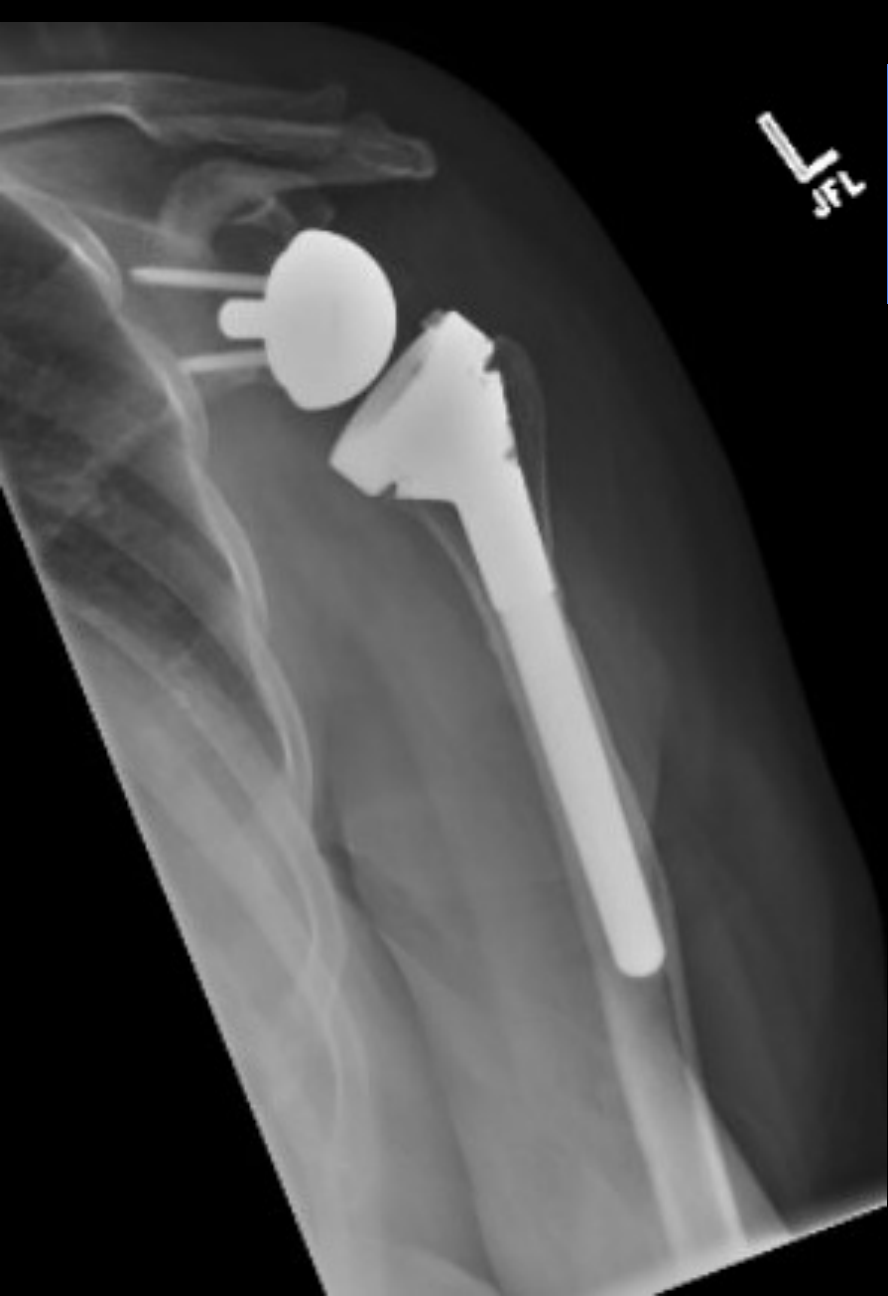

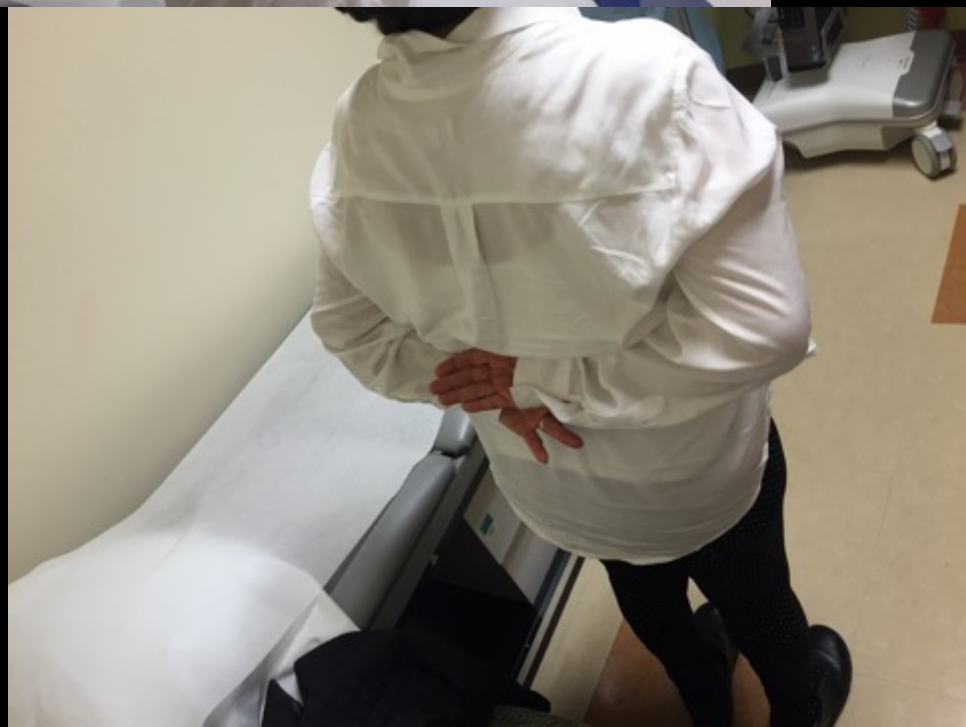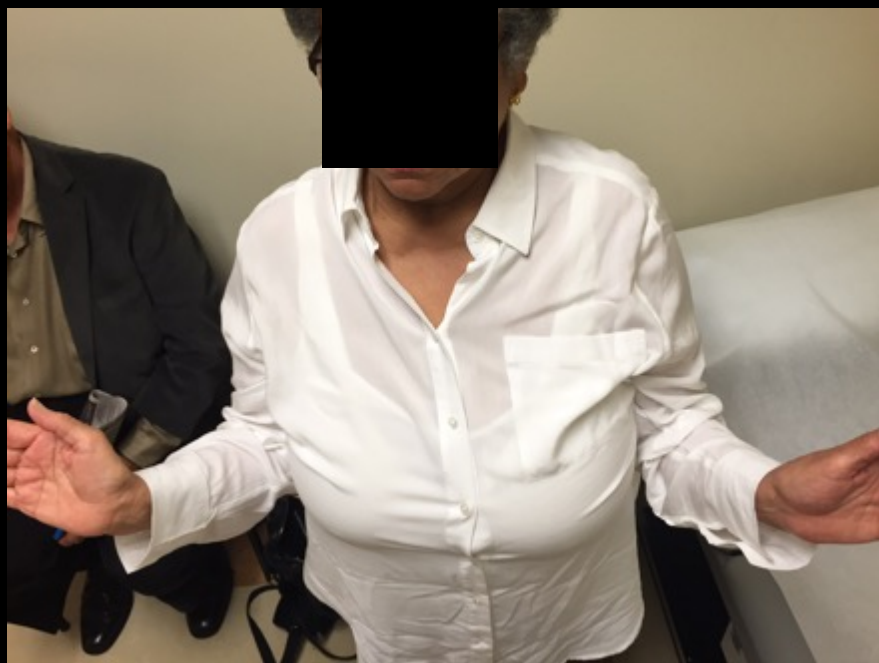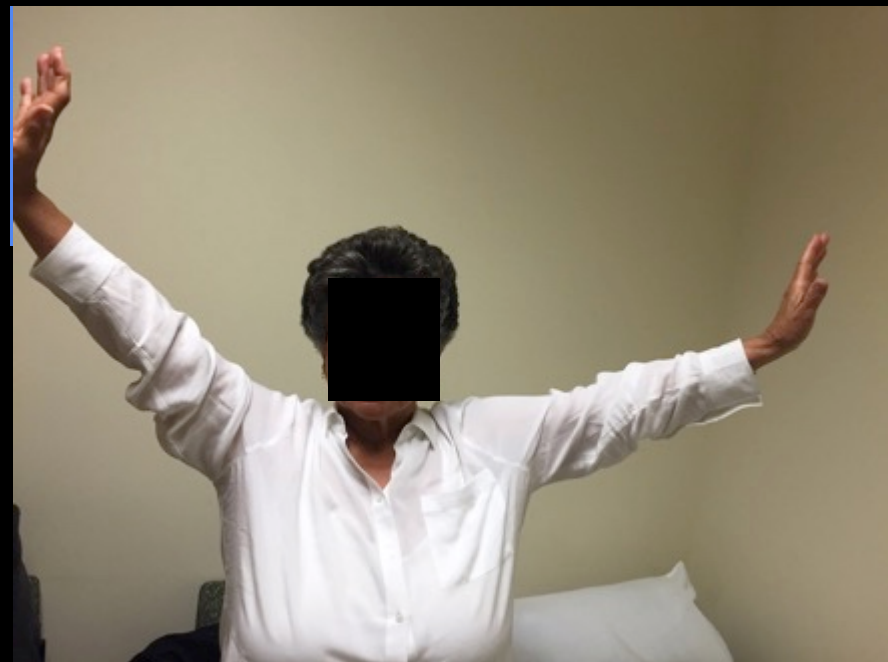66 y/o, DM

Image\_time-1

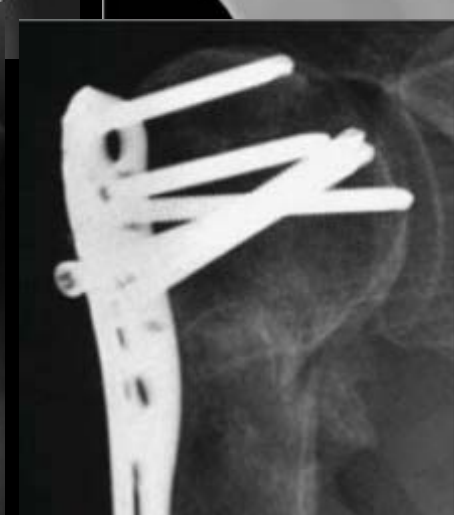
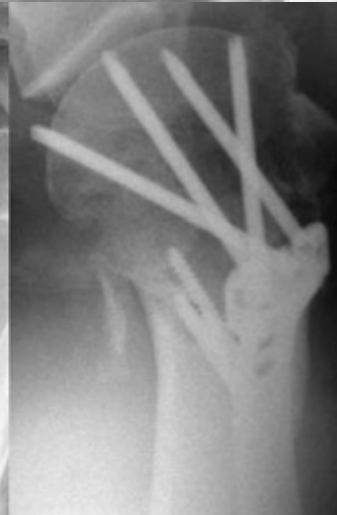
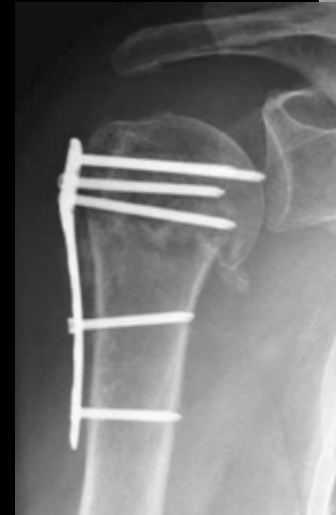
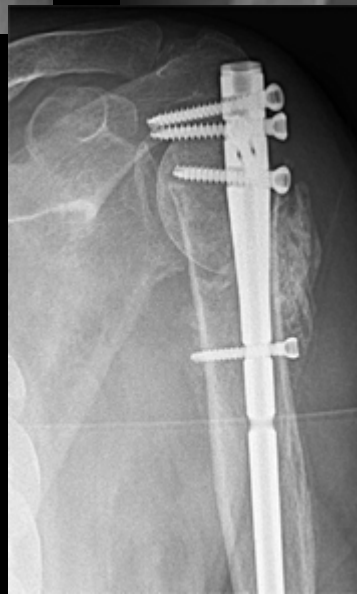
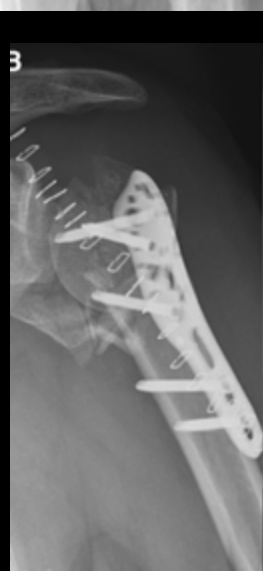
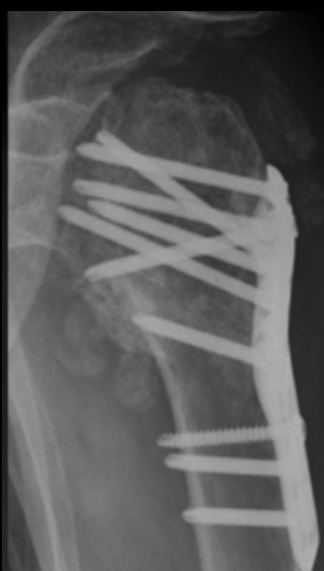
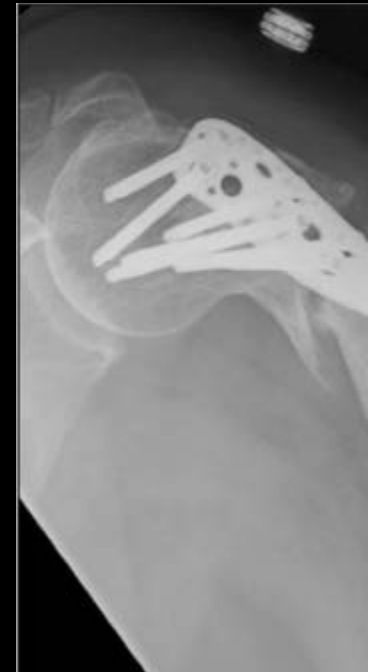
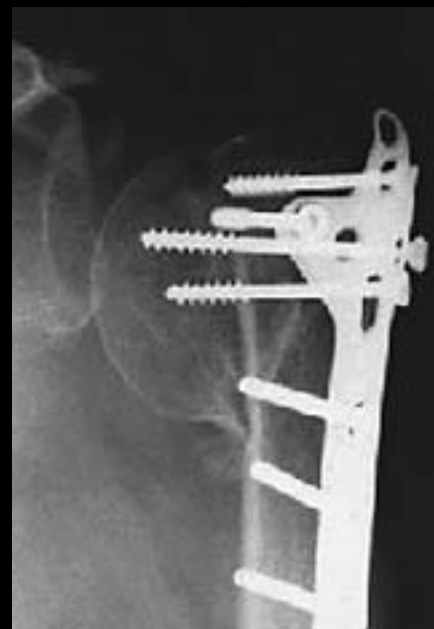
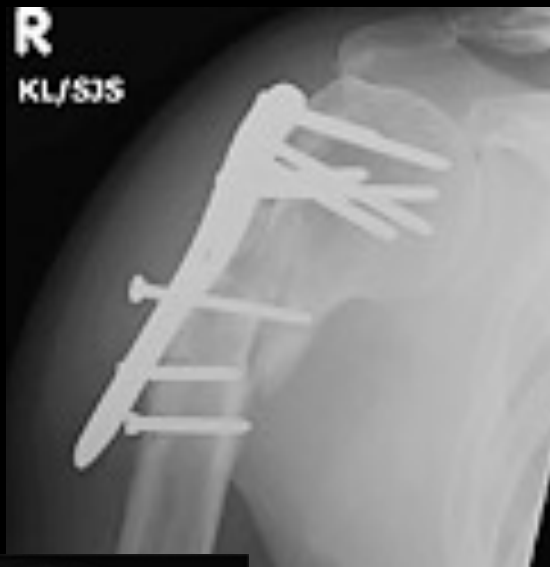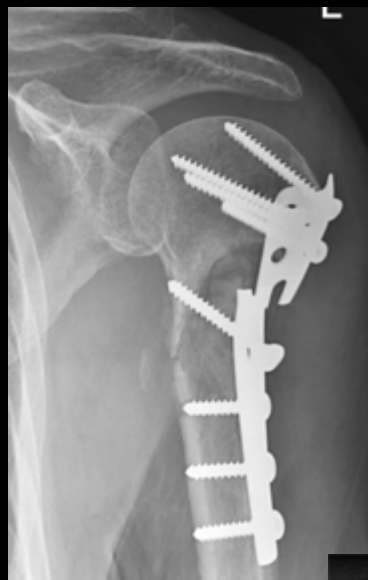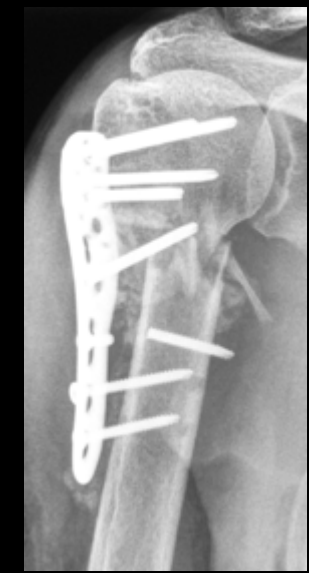# Proximal Humerus Fx's

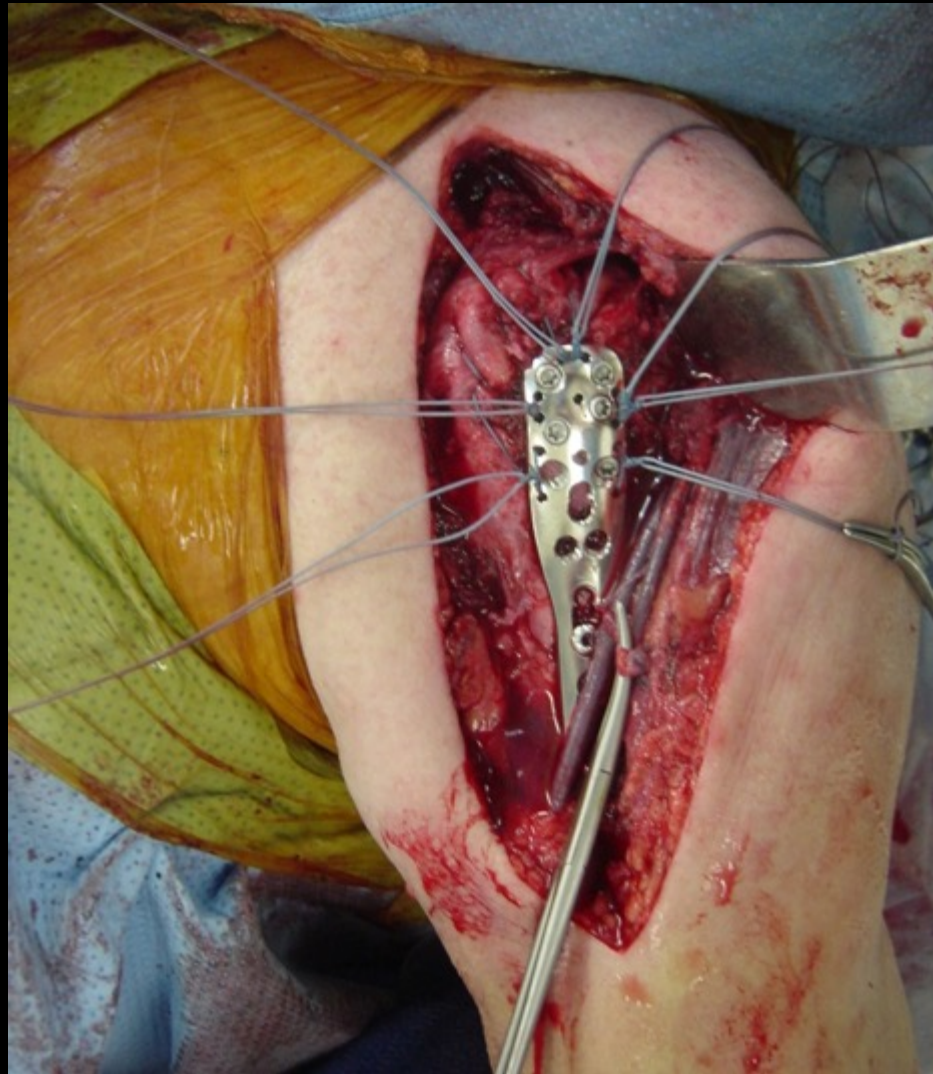


# My 50 – 50 rule

● 50 %

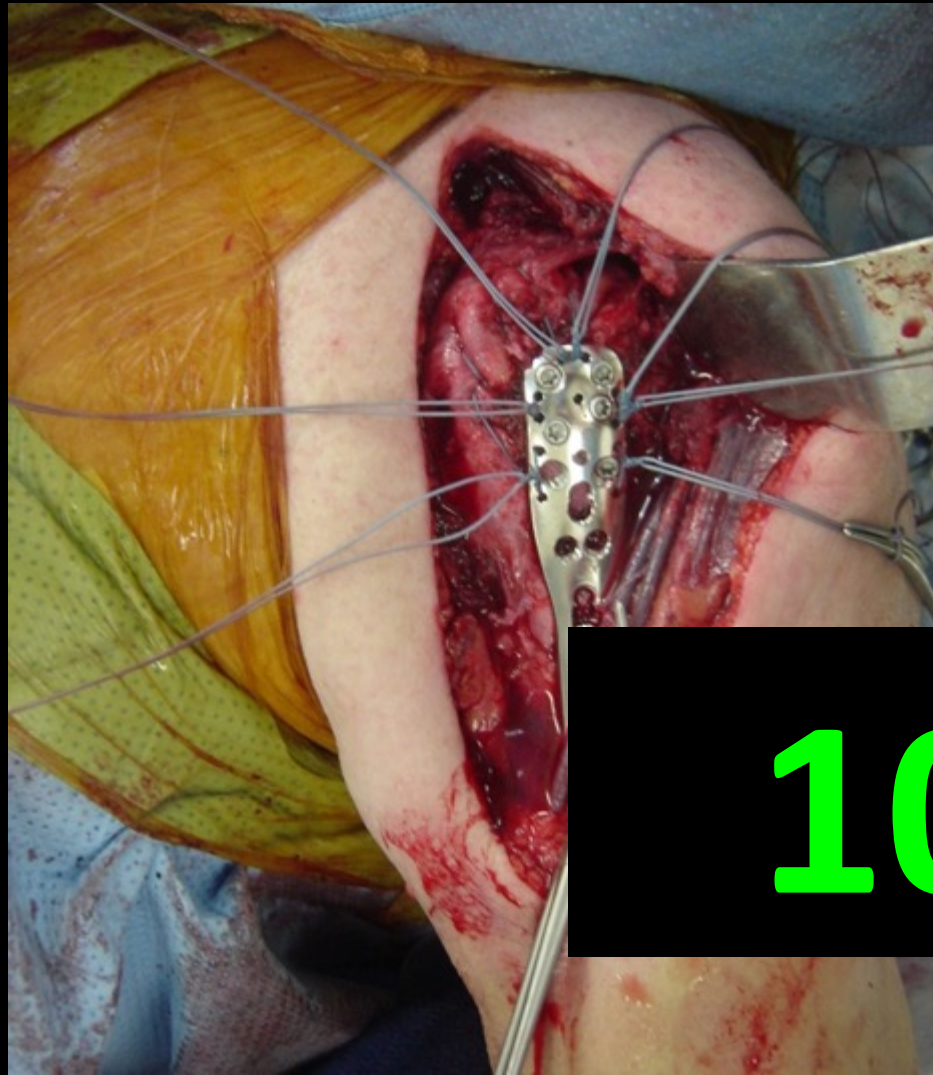
● 50%

# My 50 – 50 rule

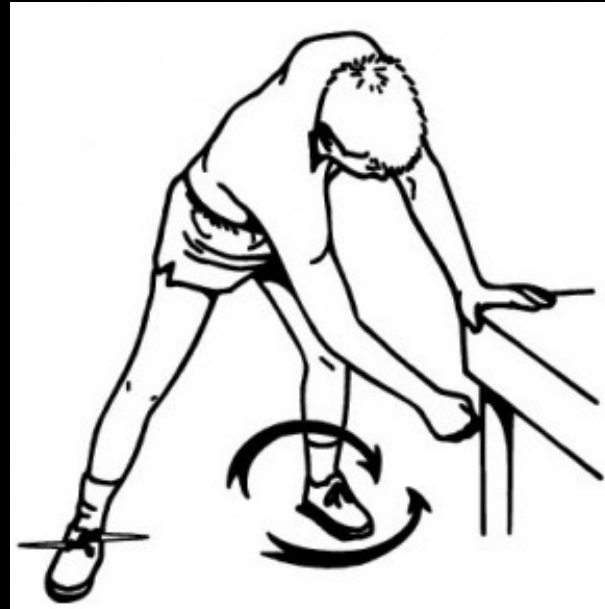


● 50%

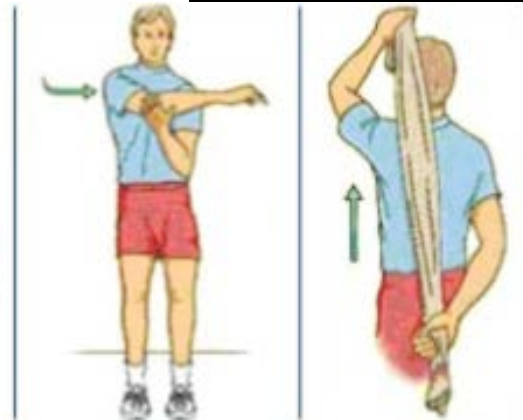# My 50 – 50 rule

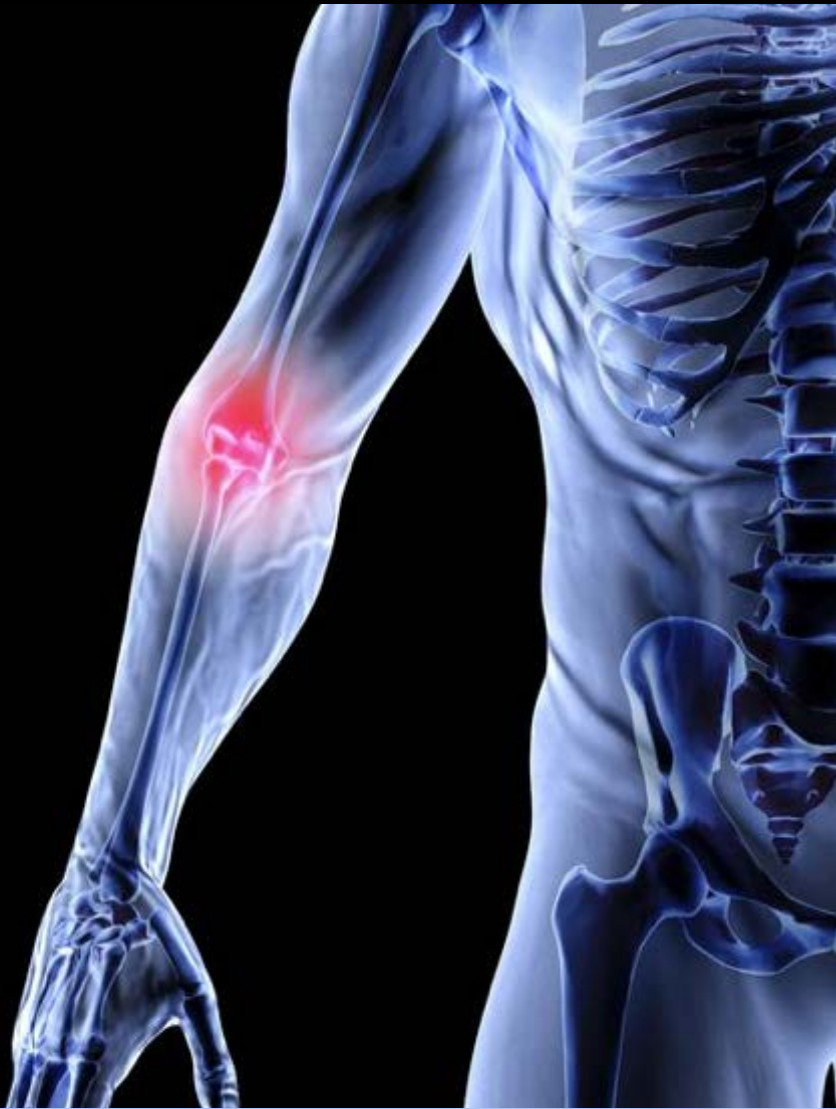


+



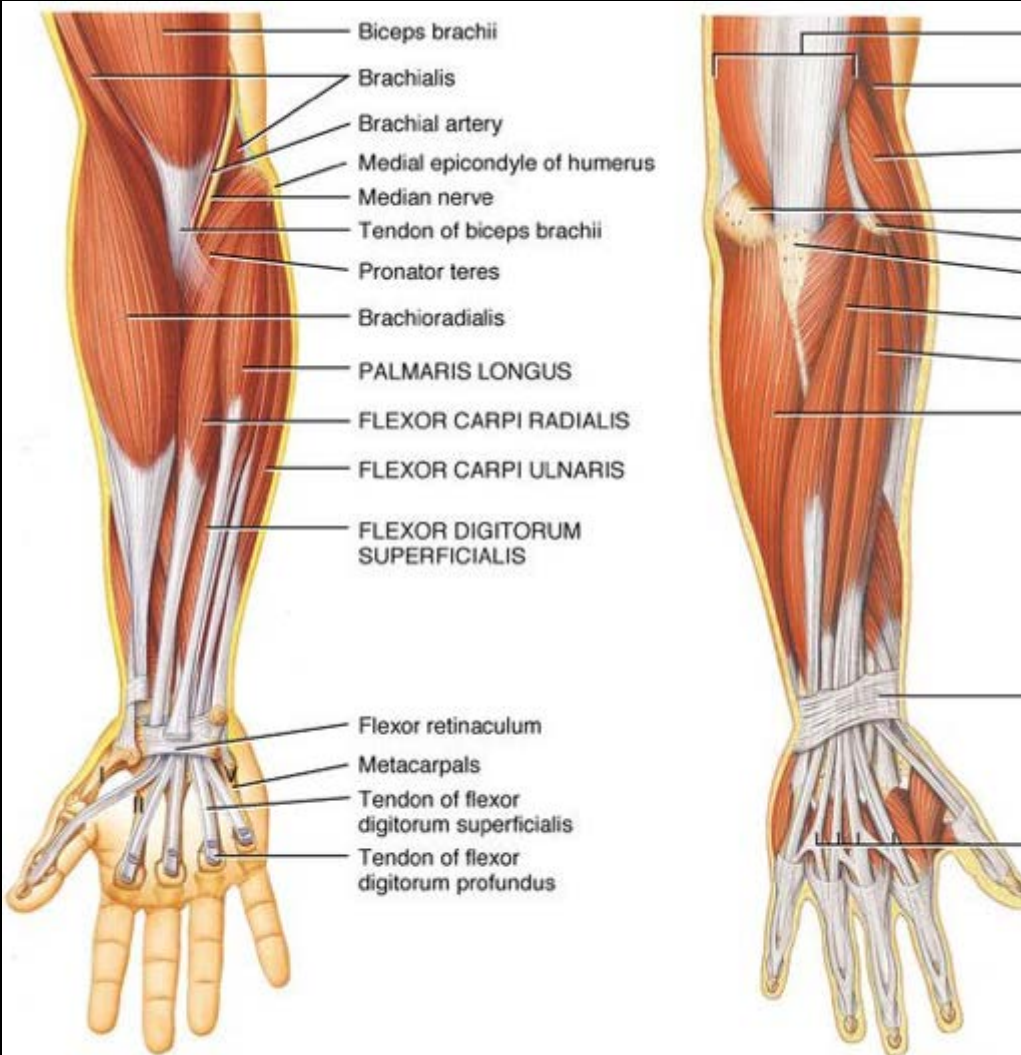
100 %



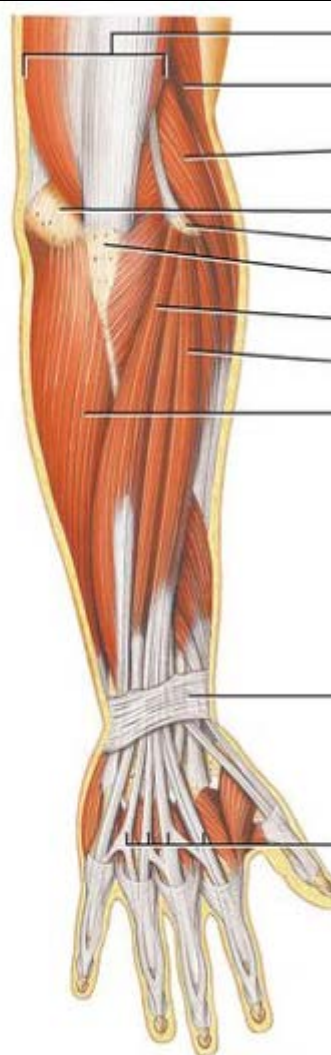


**ELBOW**

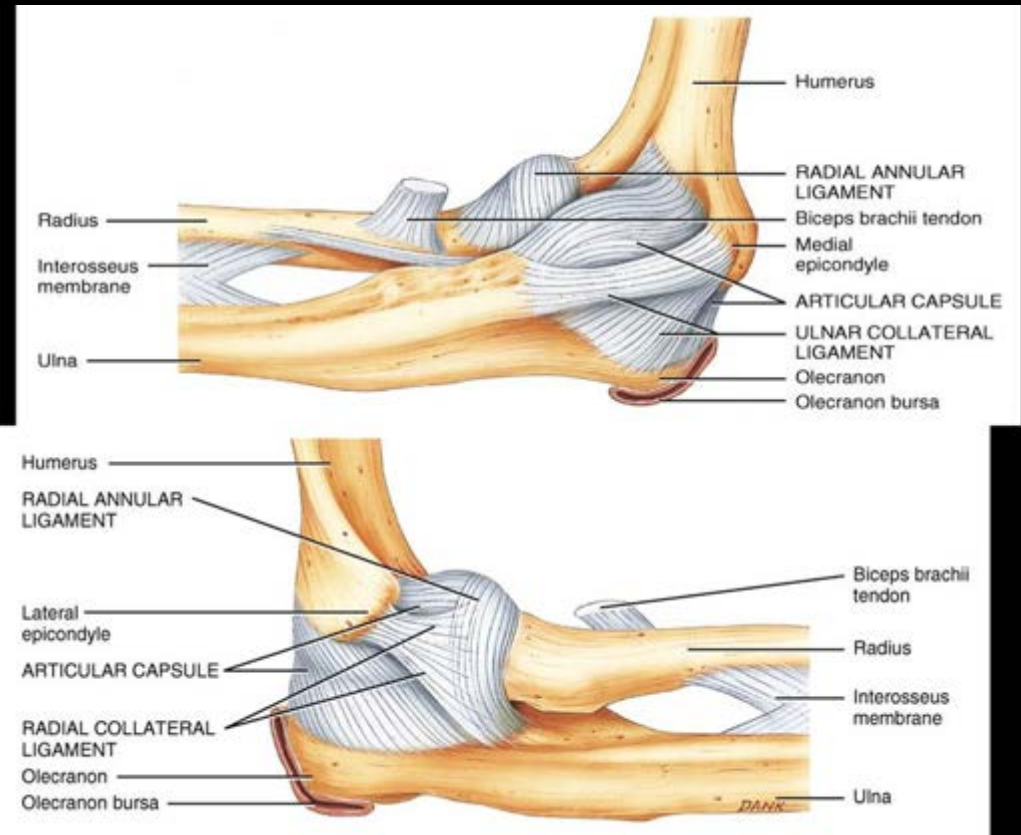
# Elbow



(a) Anterior superficial view

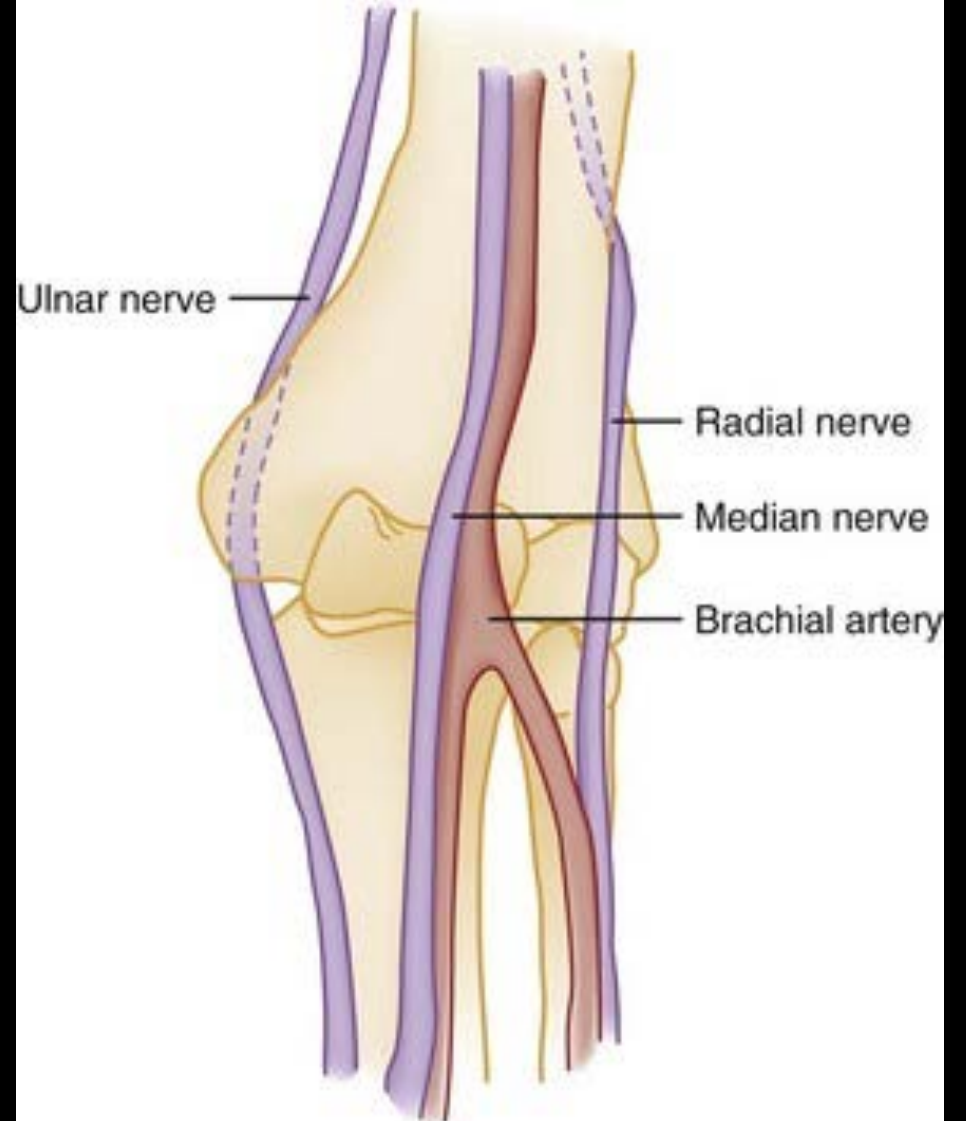
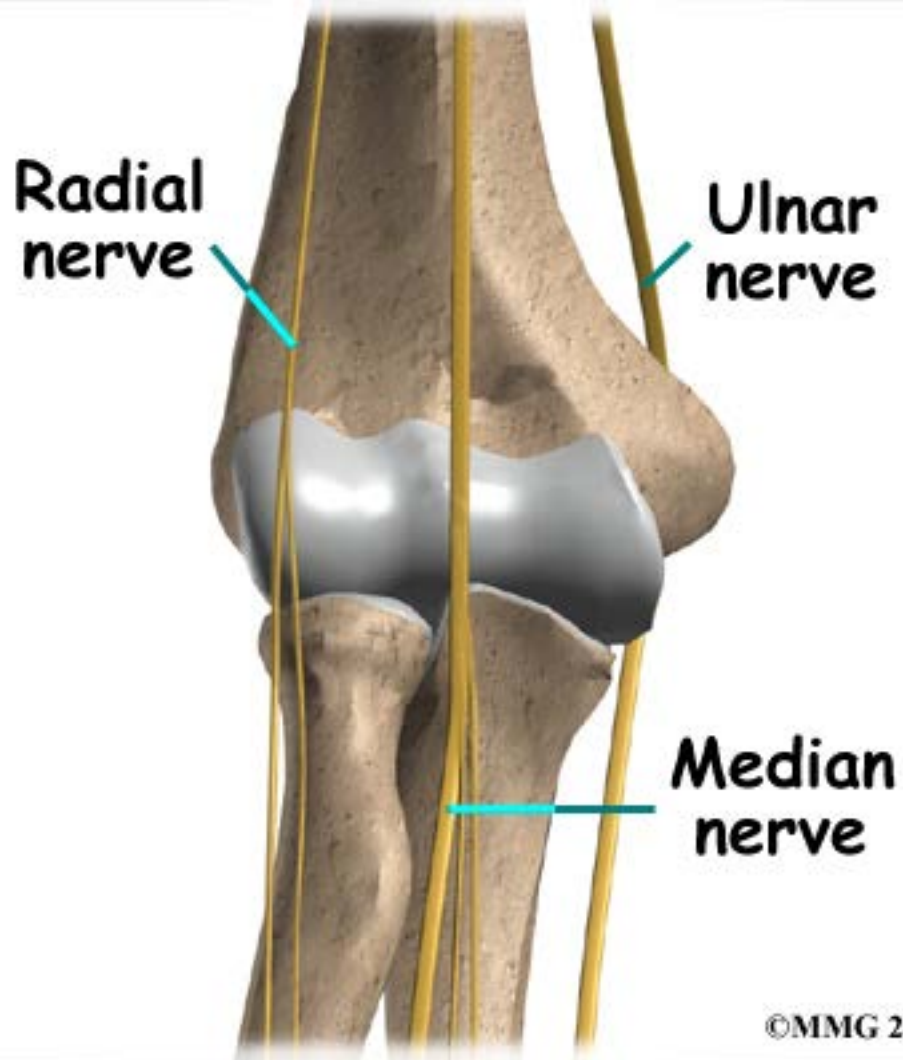


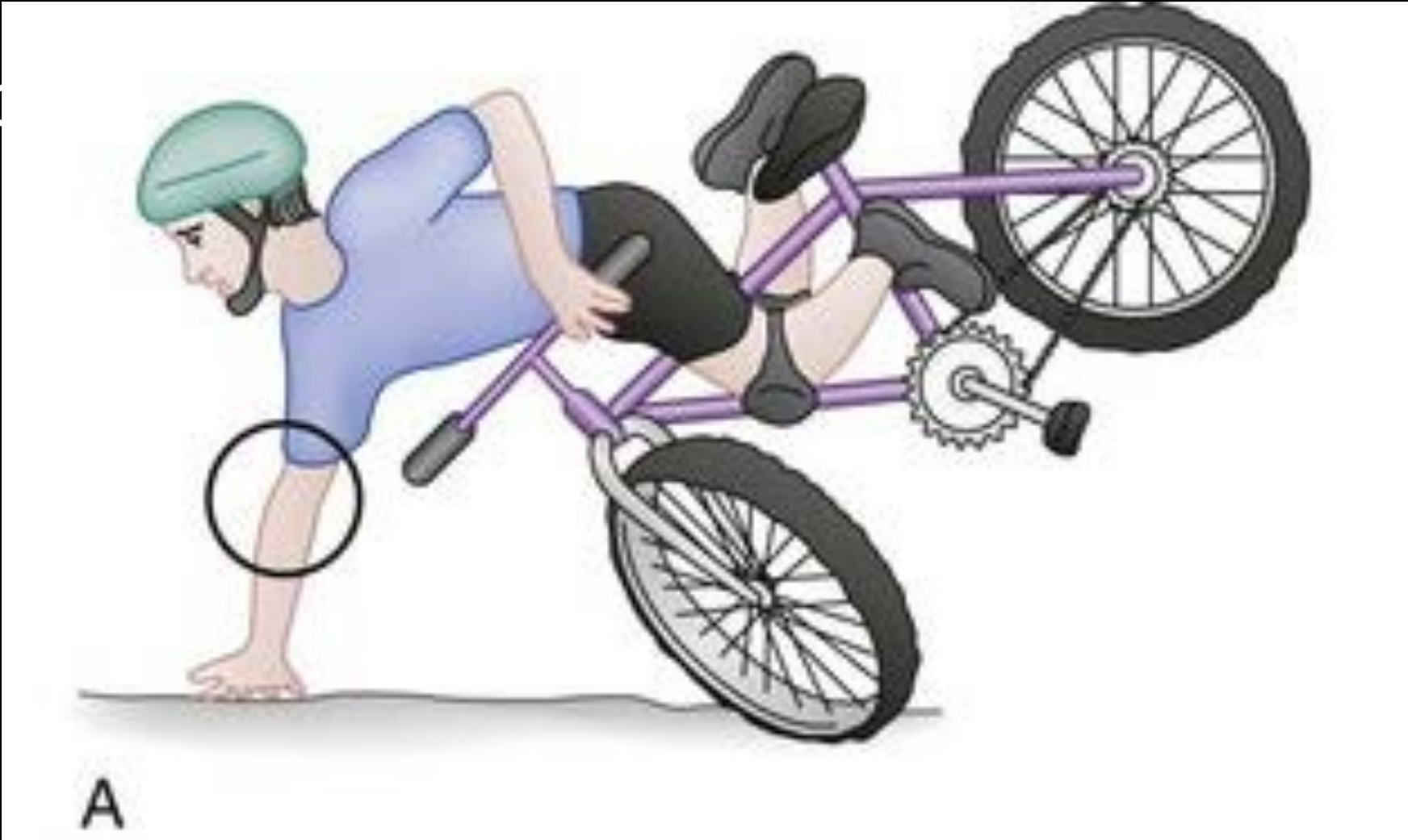(b) Posterior superficial view





# Elbow

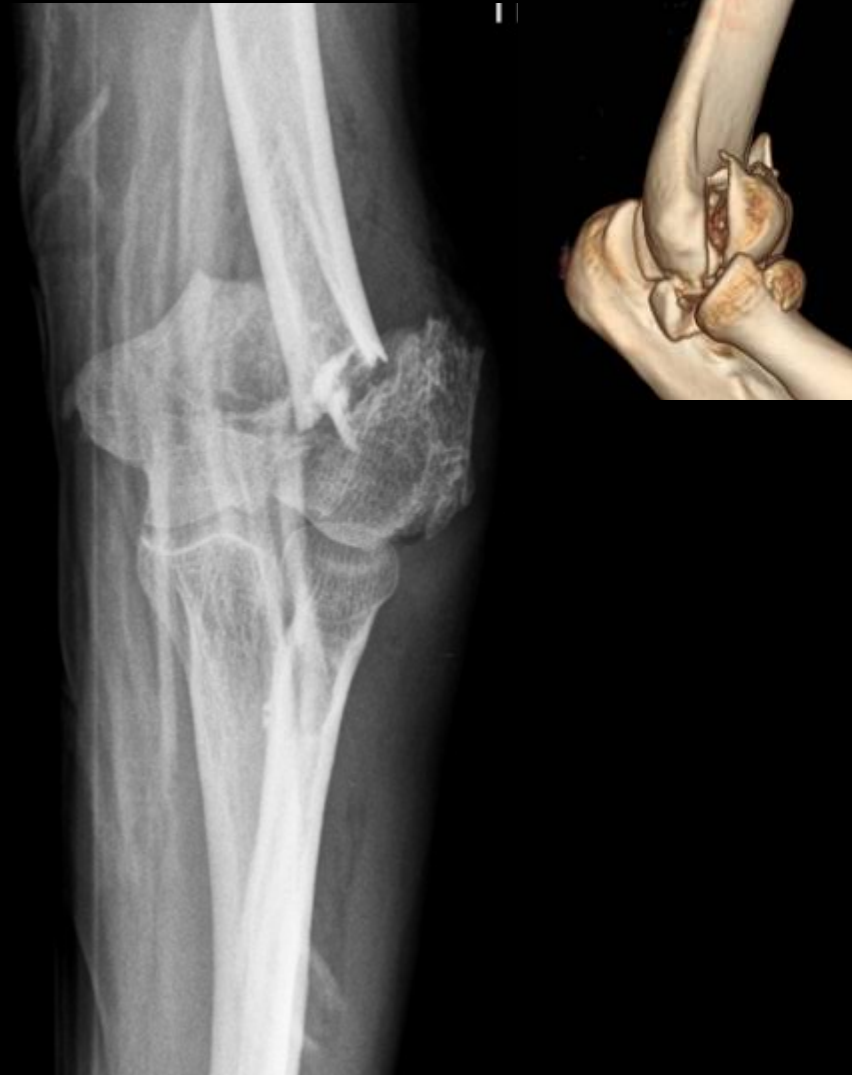



A

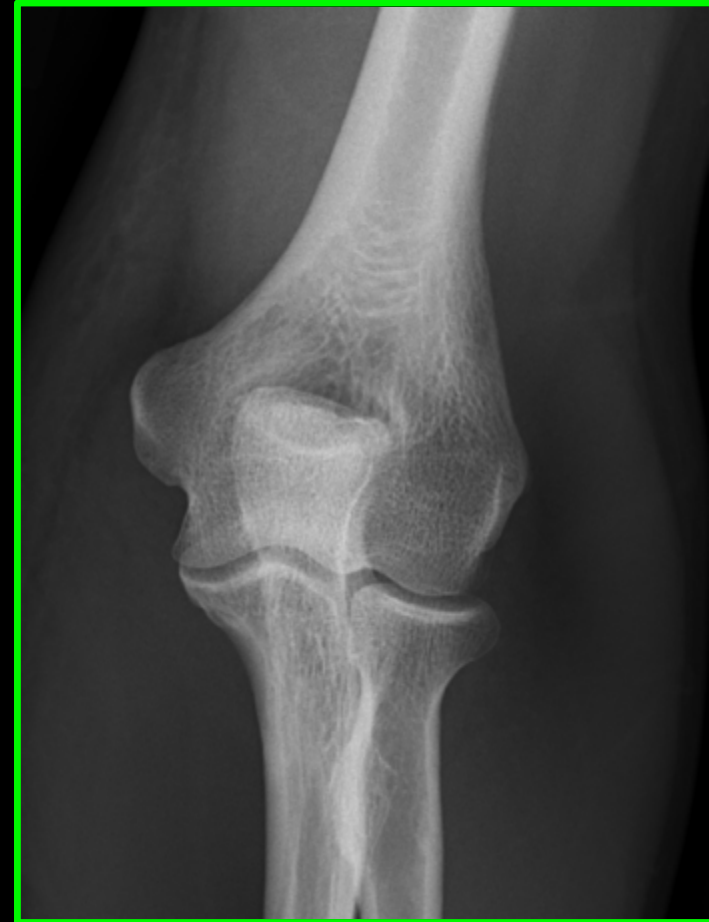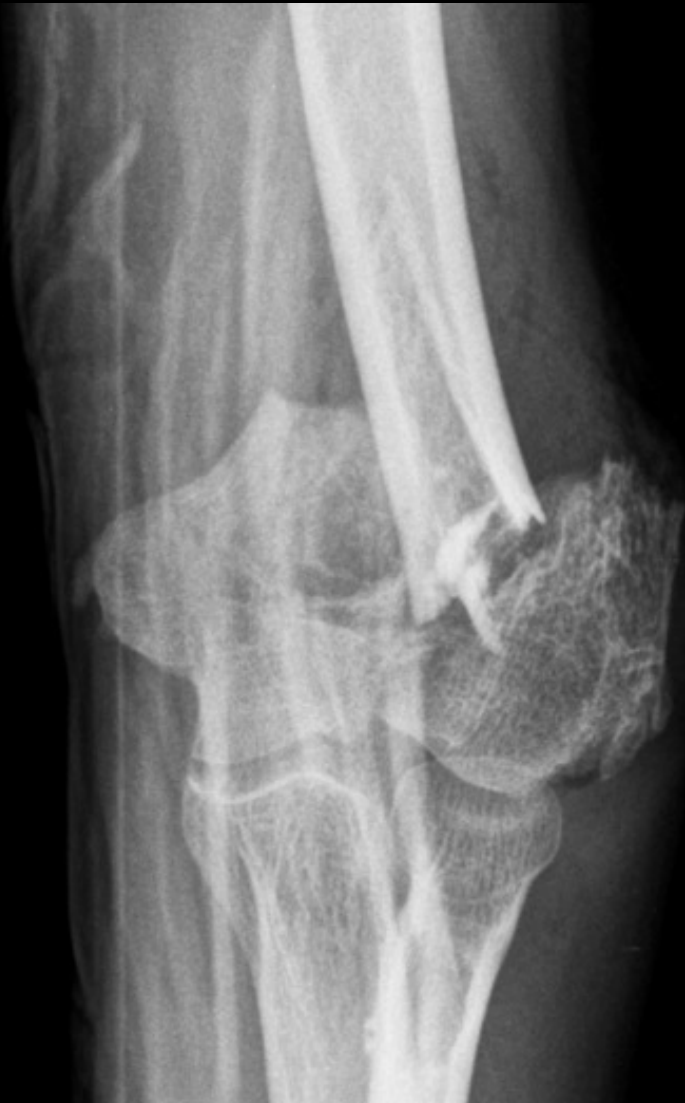# Distal Humerus Fx

- Fall
- MCA, MVA
- Treatment: Surgery

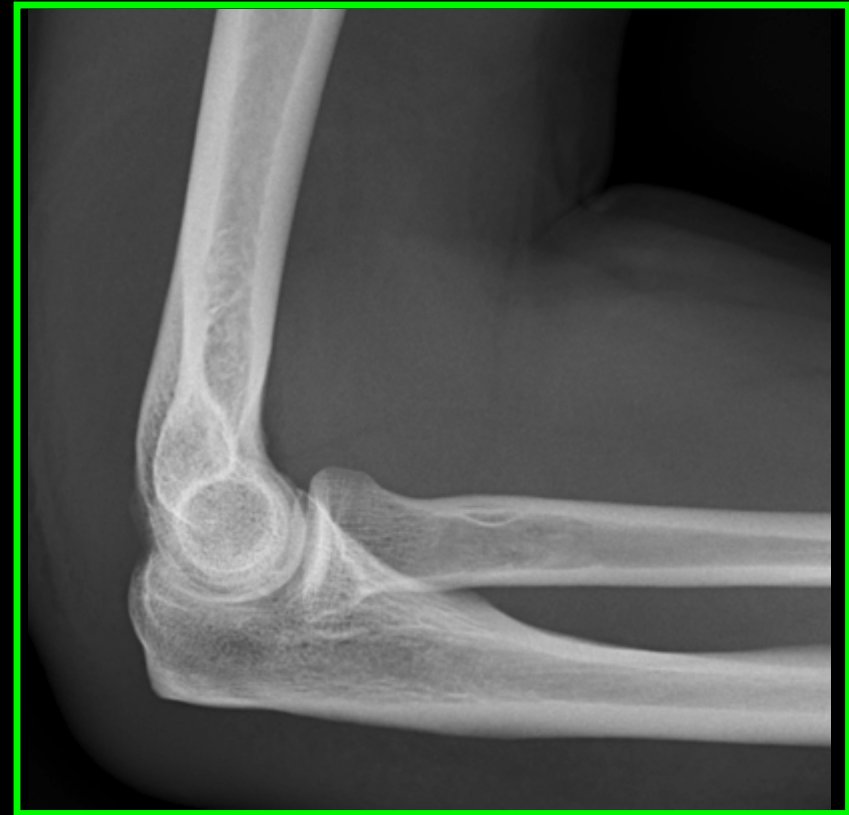
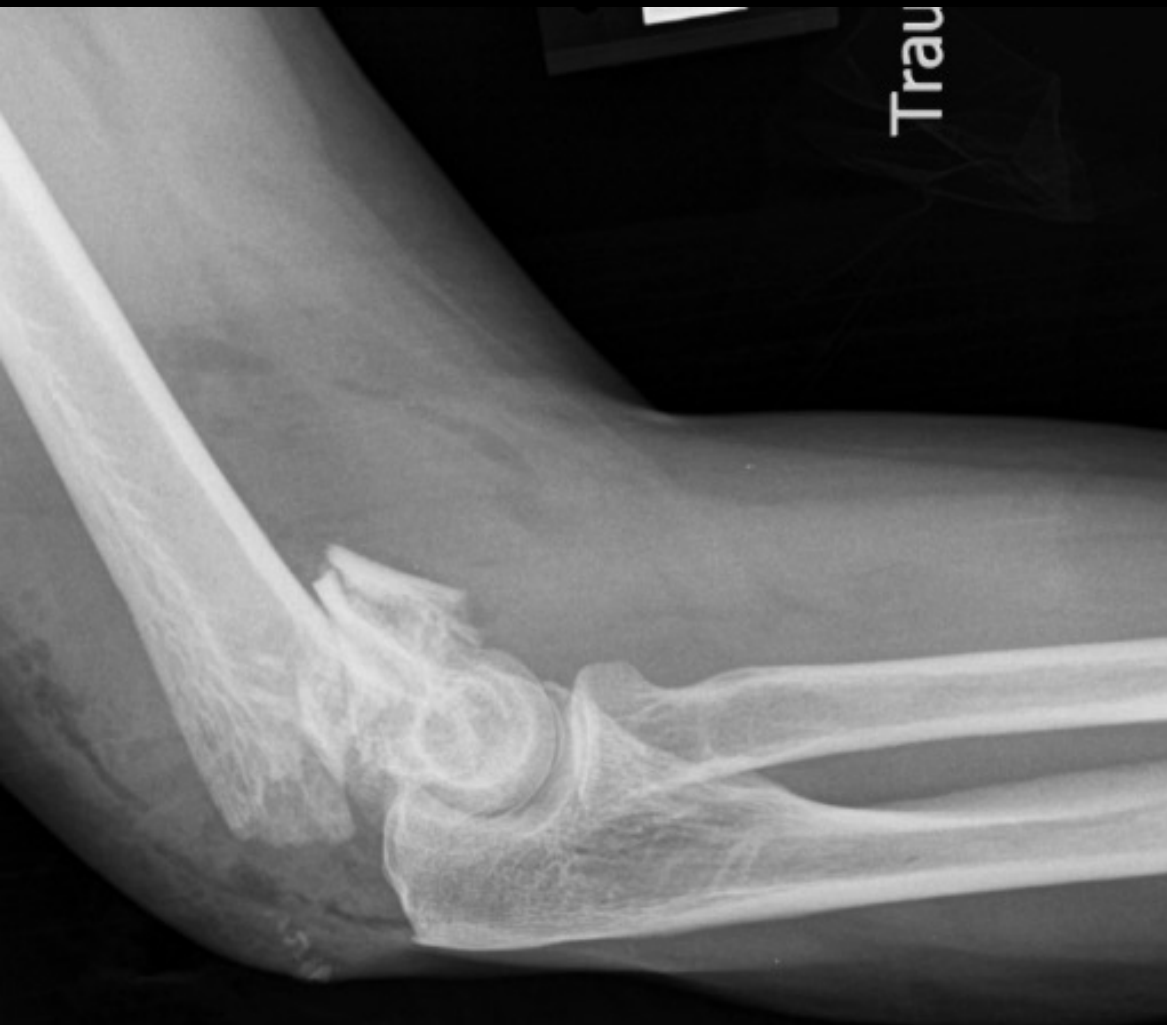
54 y/o female

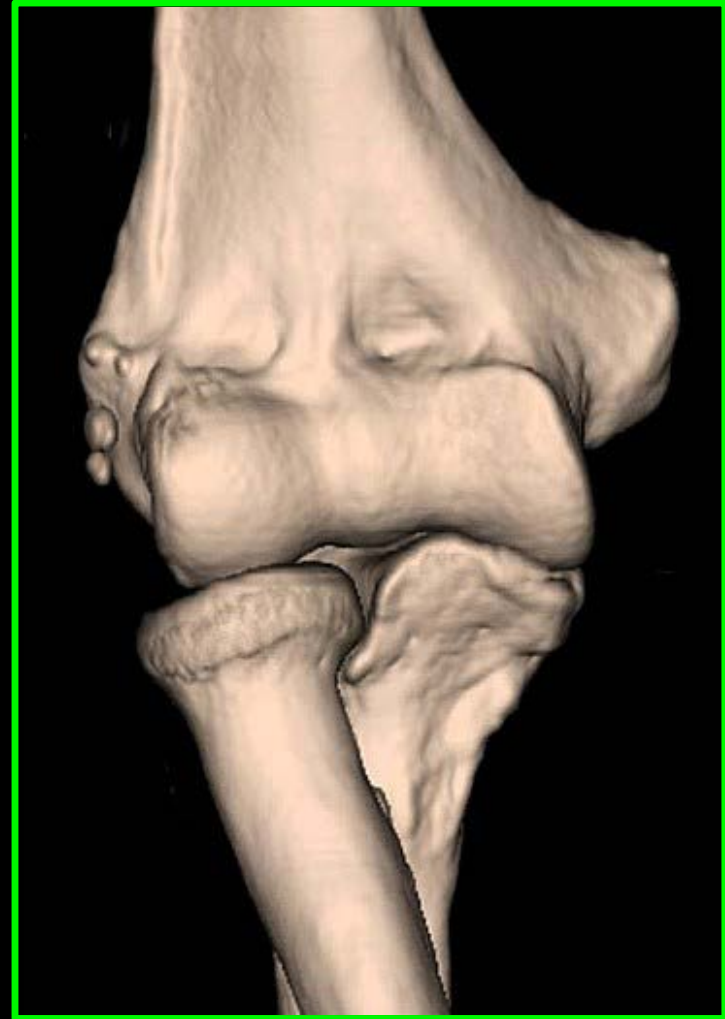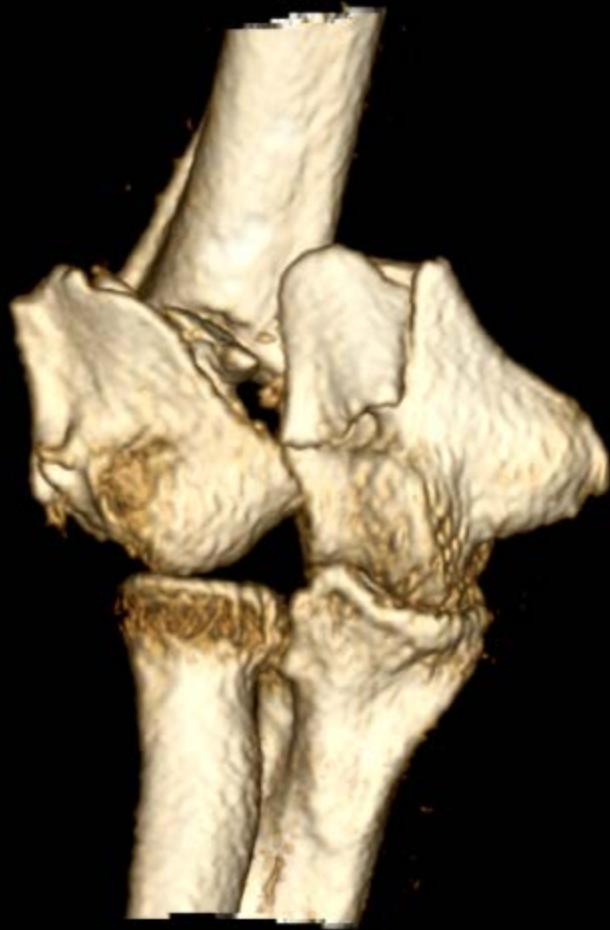11 aul



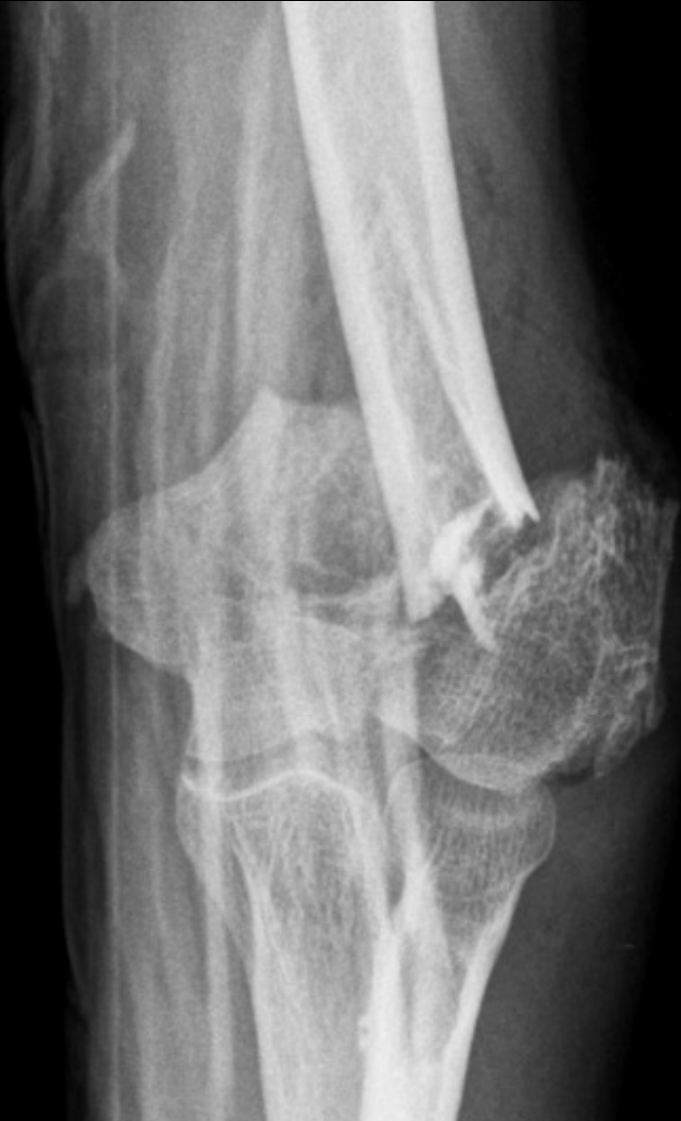54 y/o female



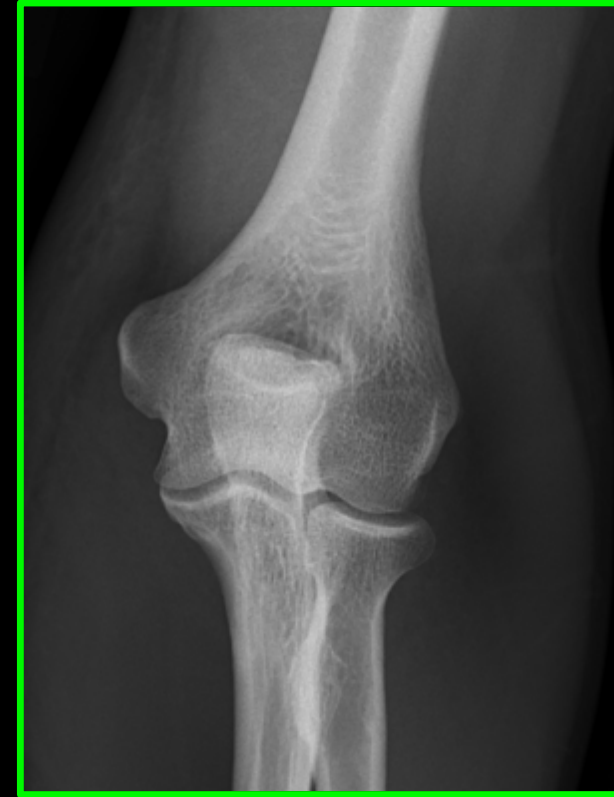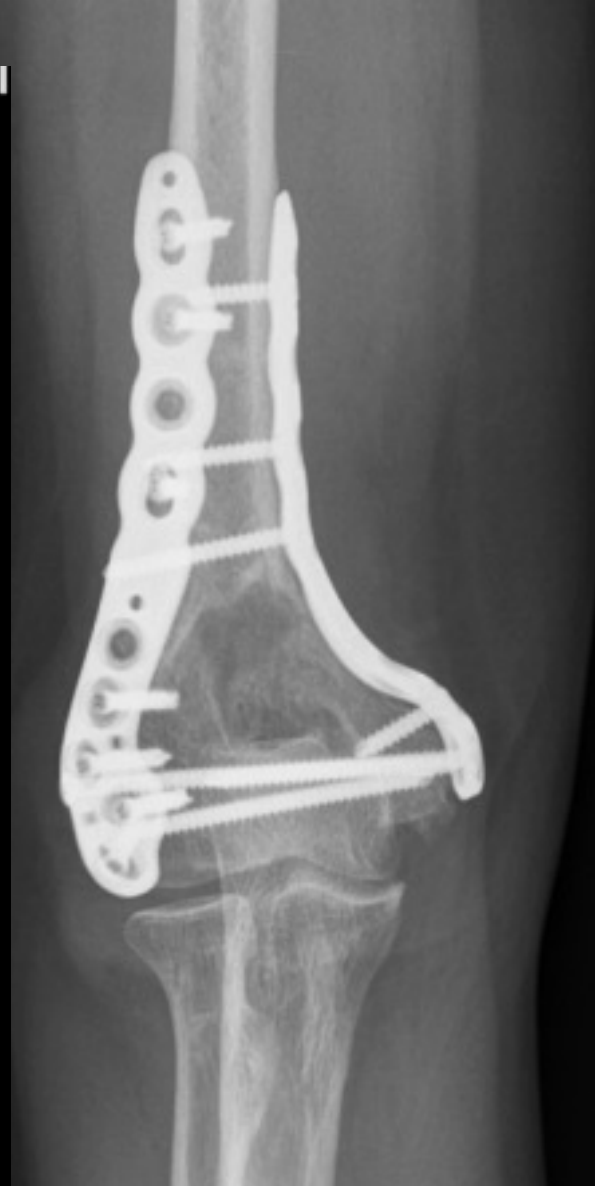54 y/o female



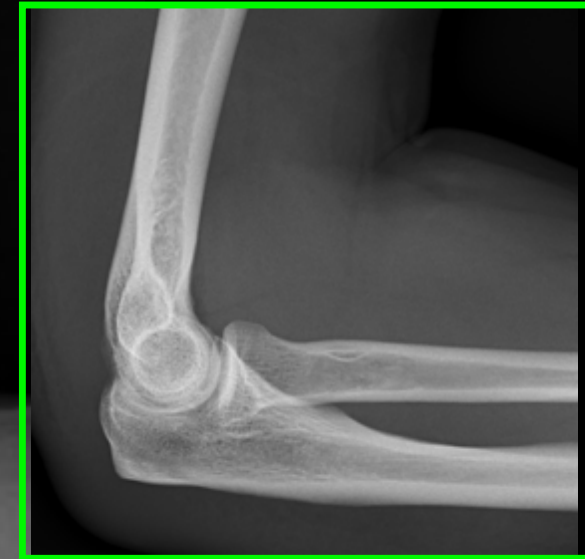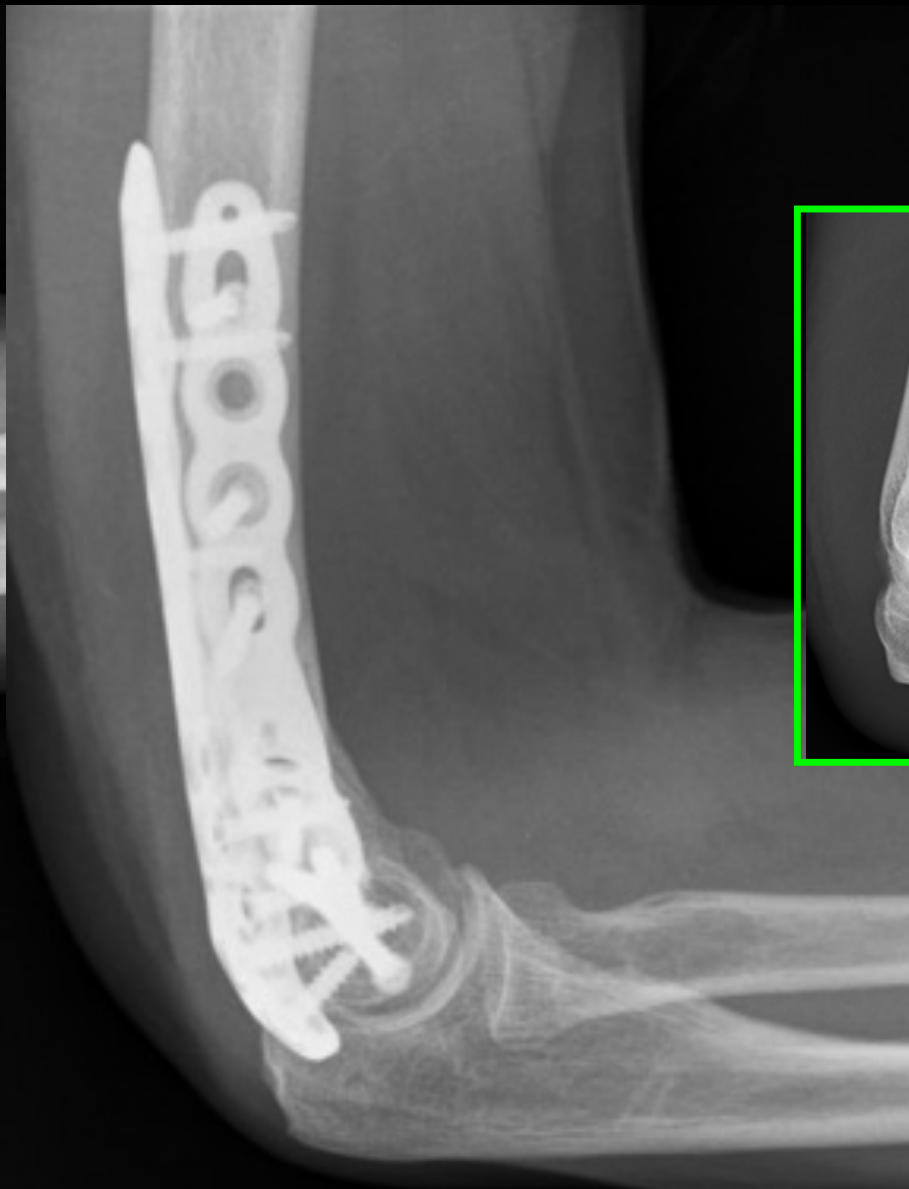
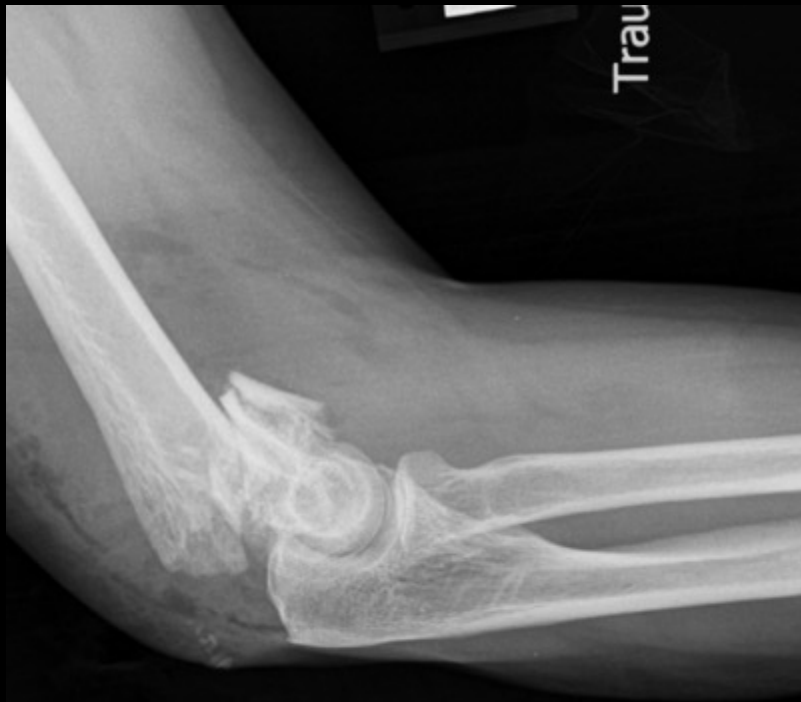54 y/o female



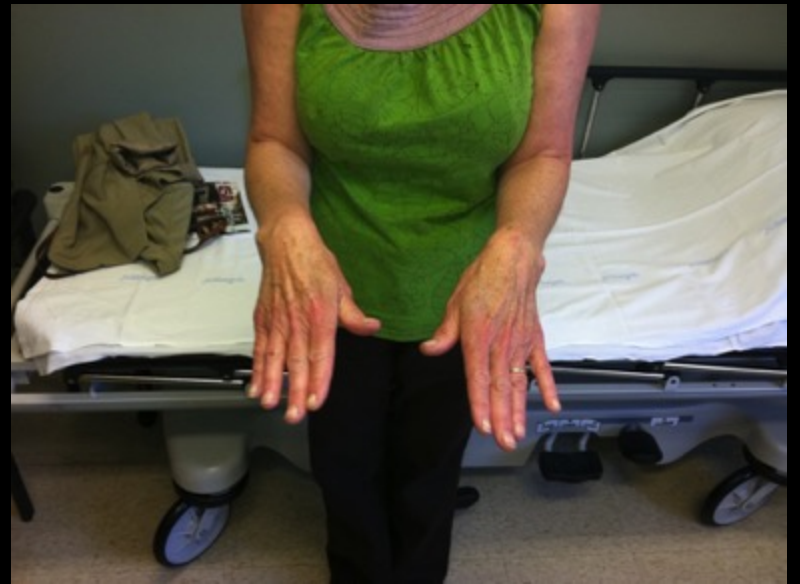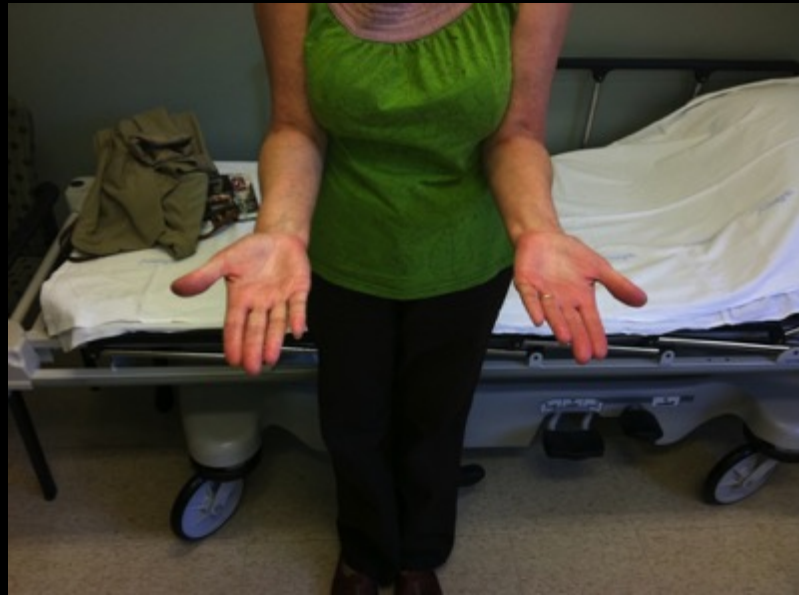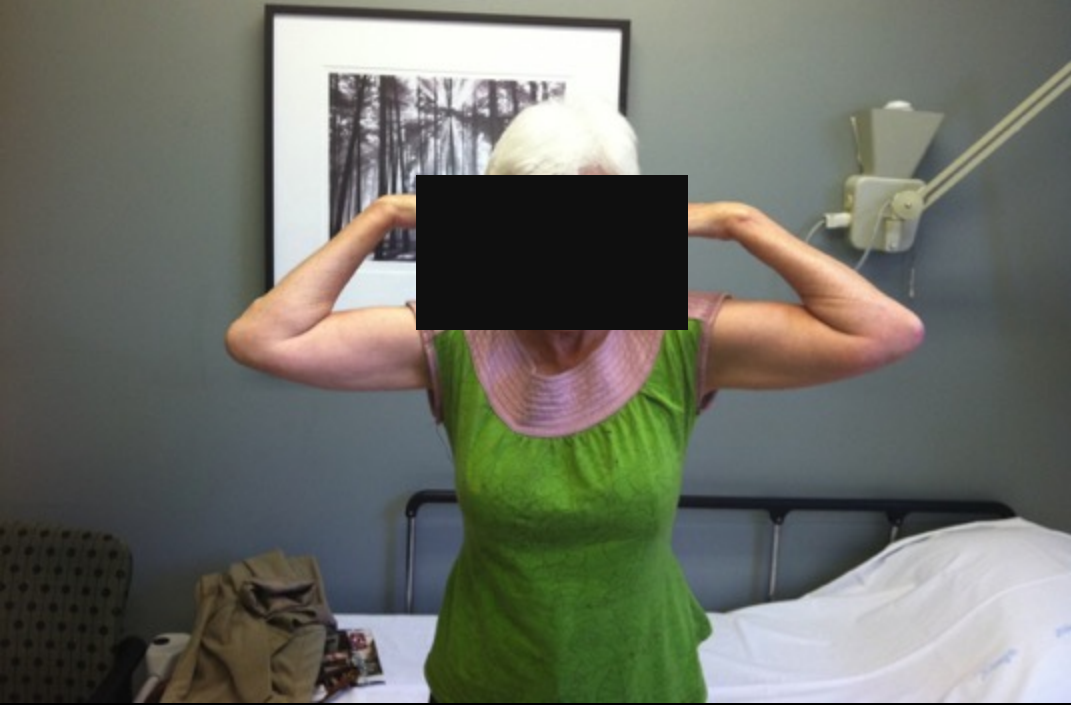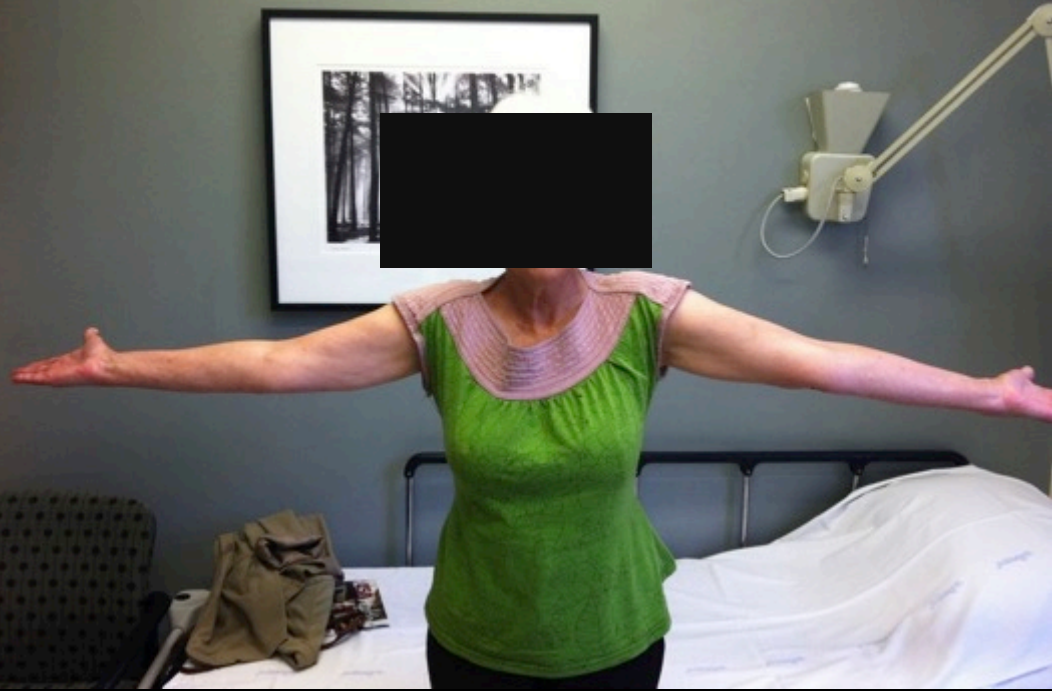11 au1



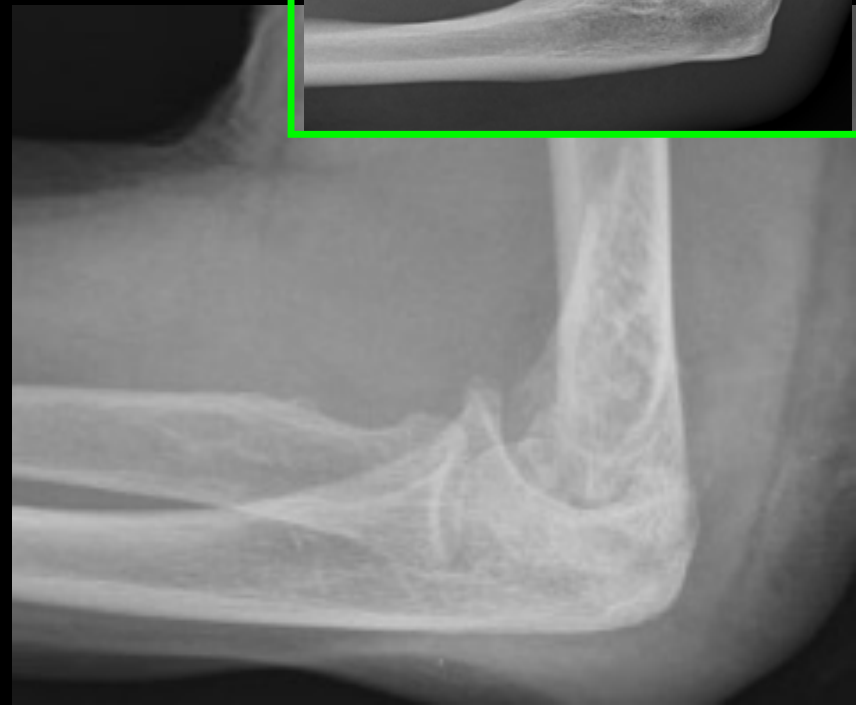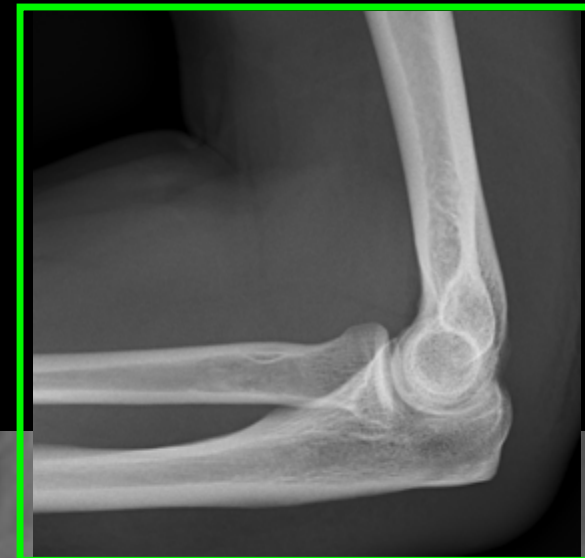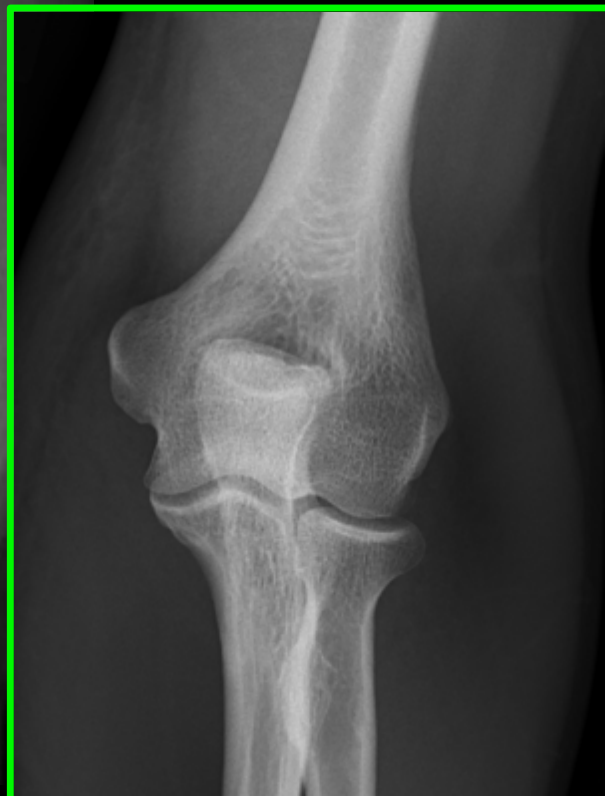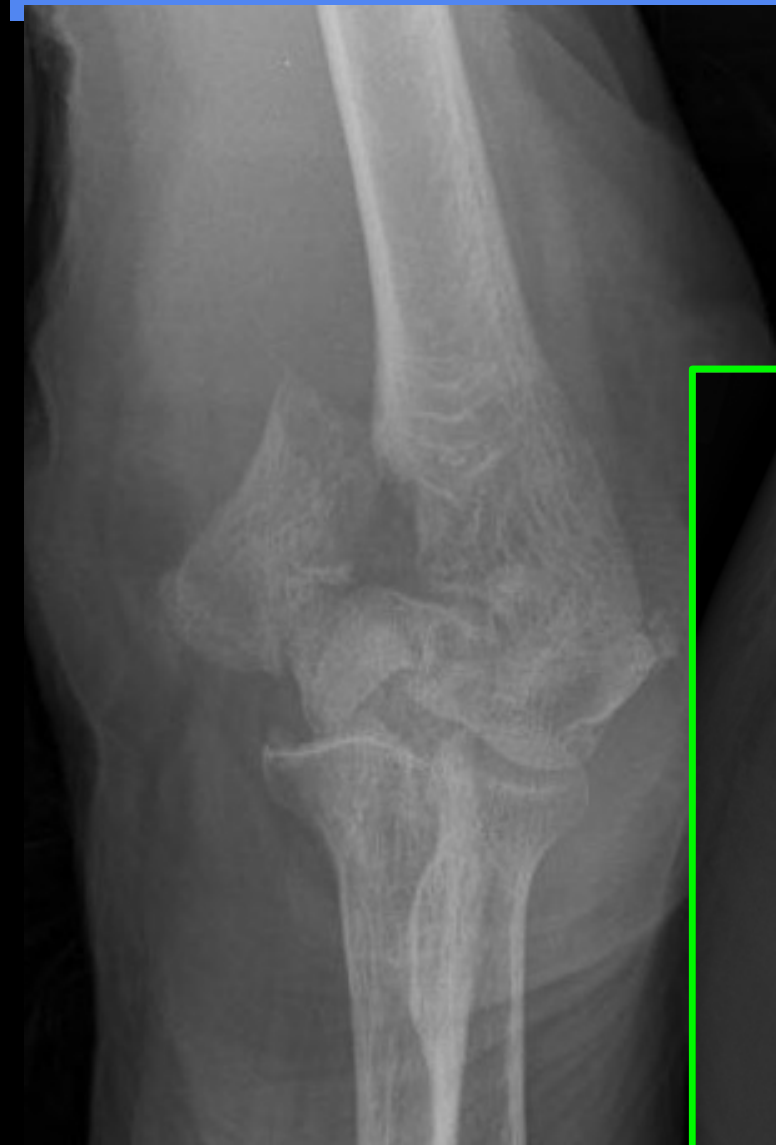54 y/o female



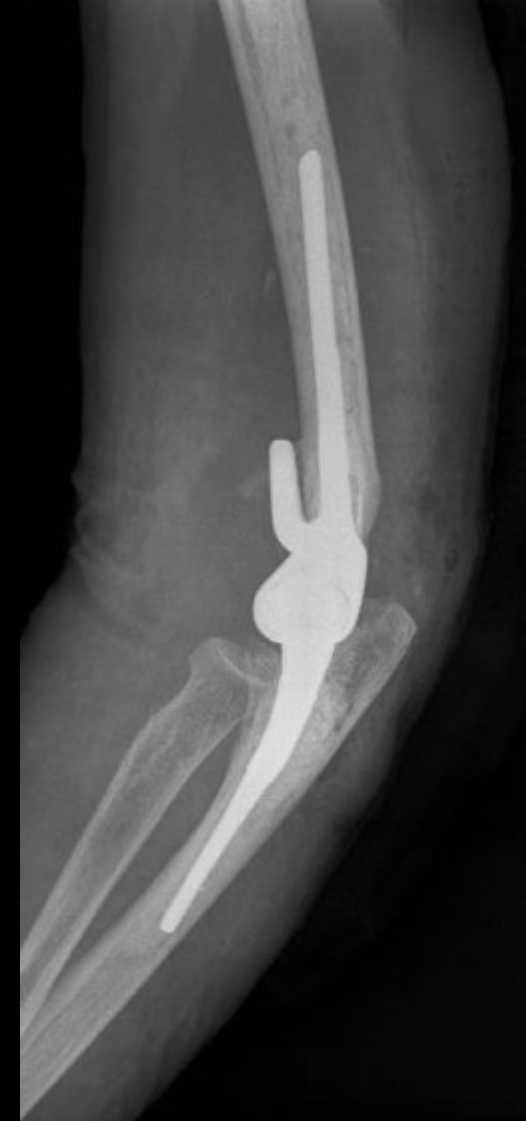
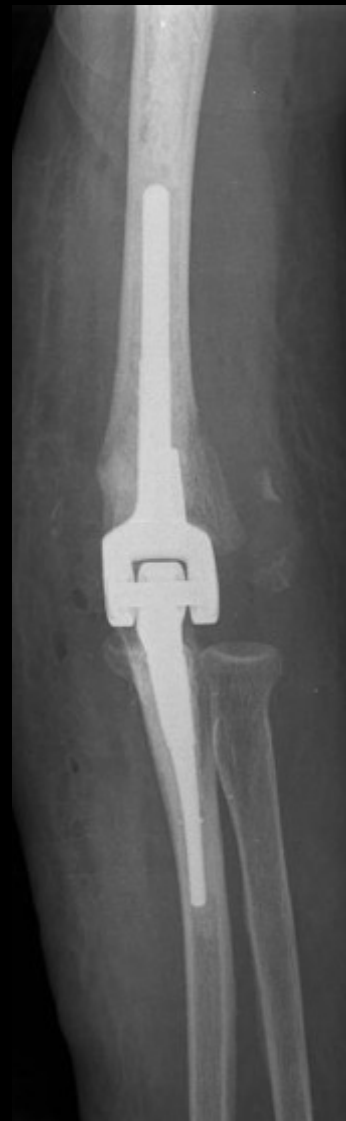
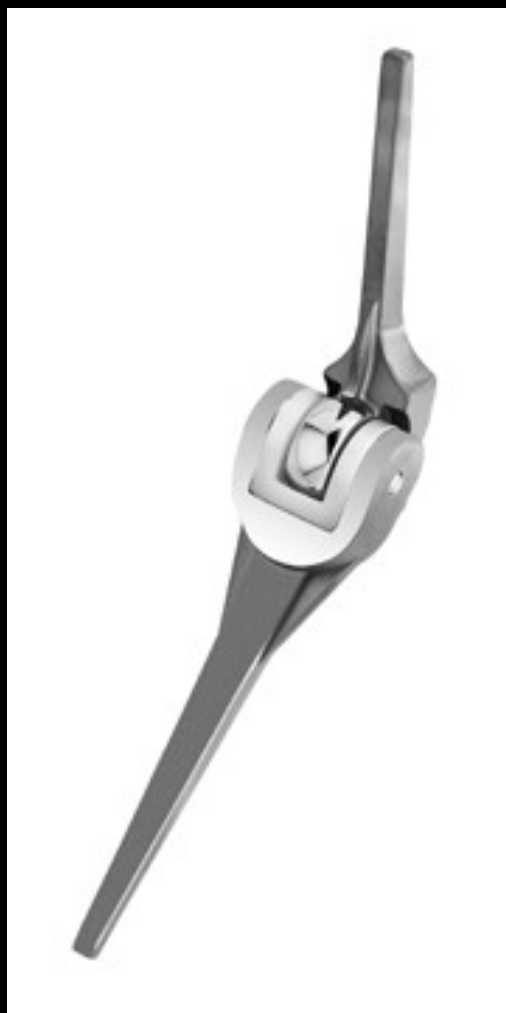
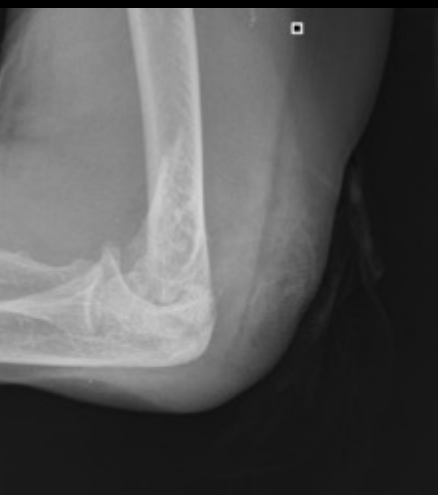
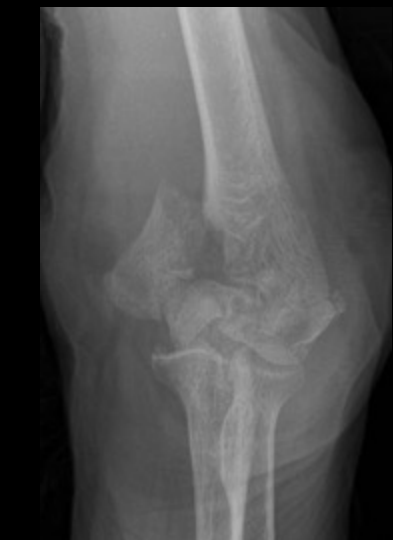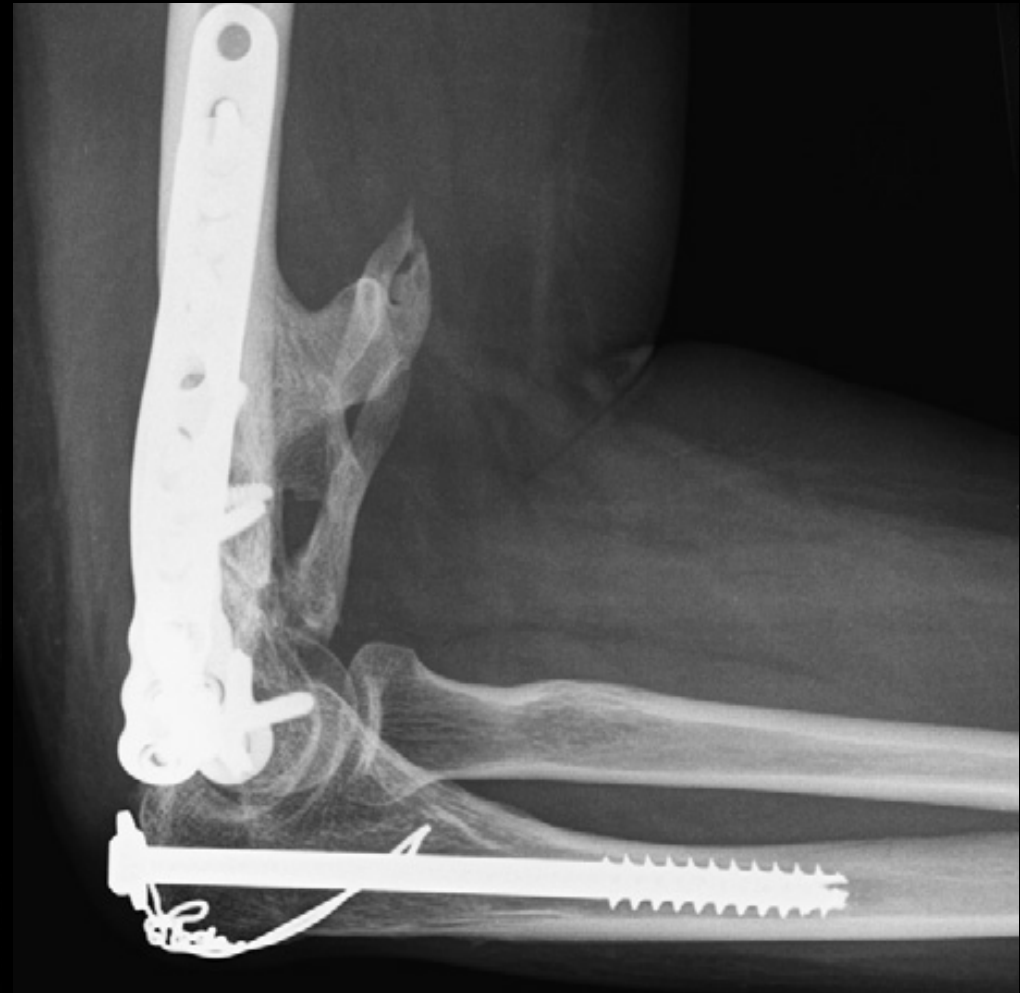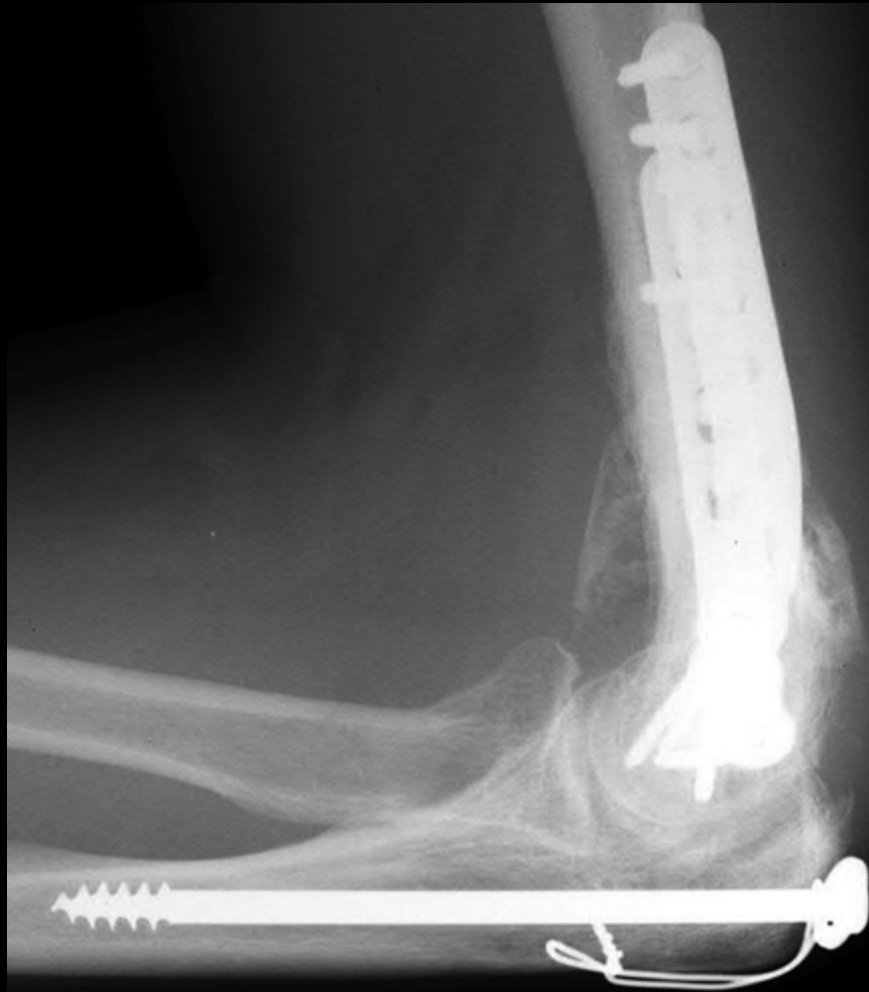94 y/o, s/p fall

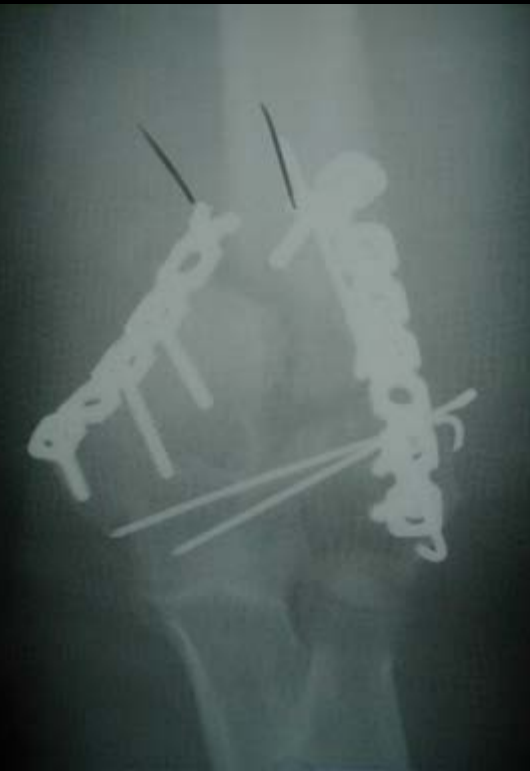
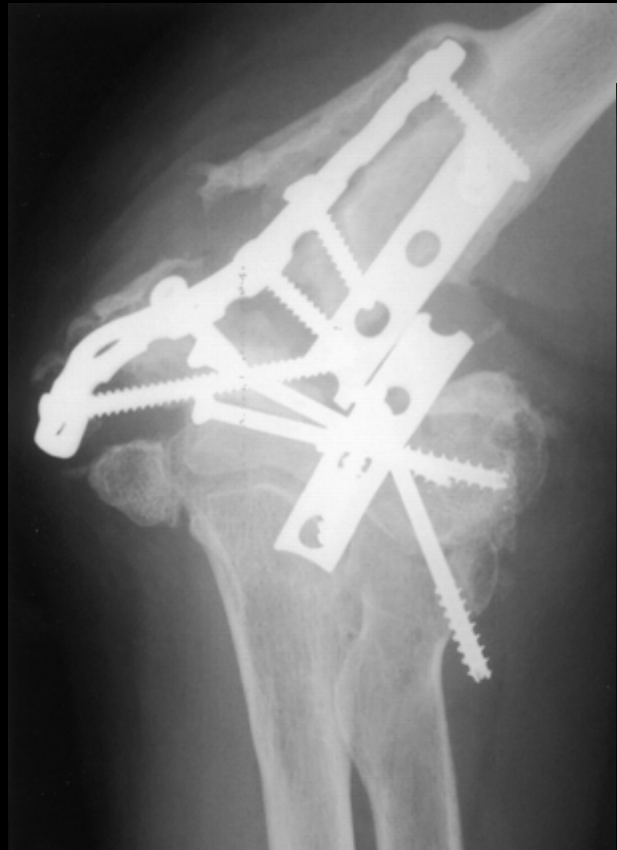
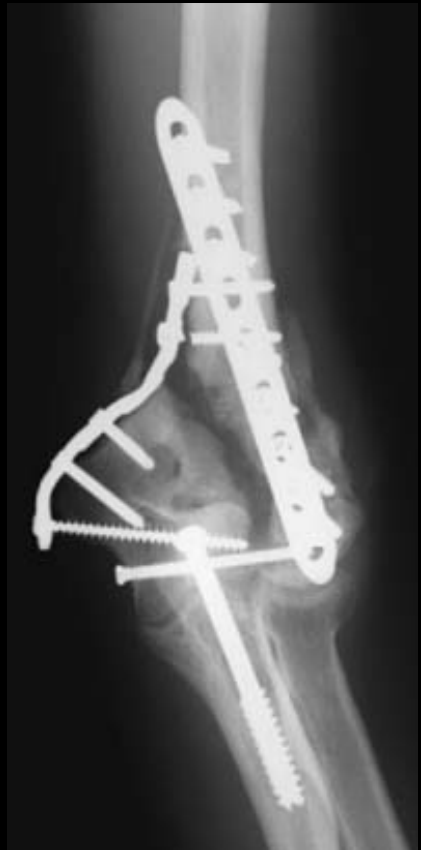
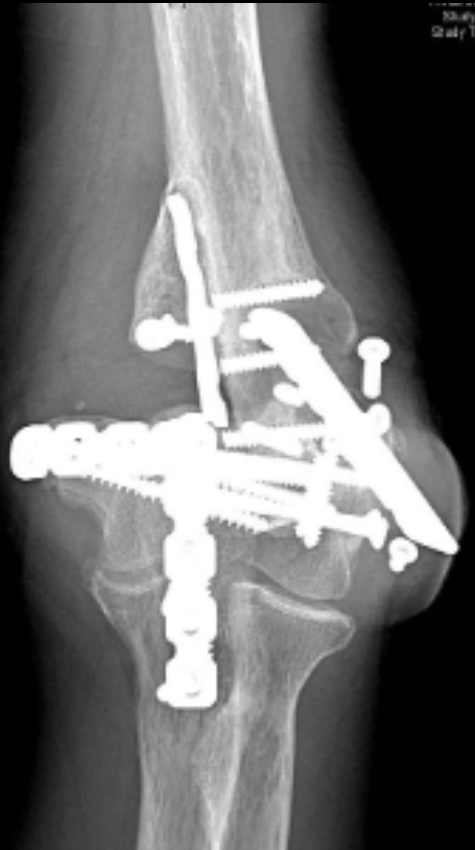94 y/o, s/p fall



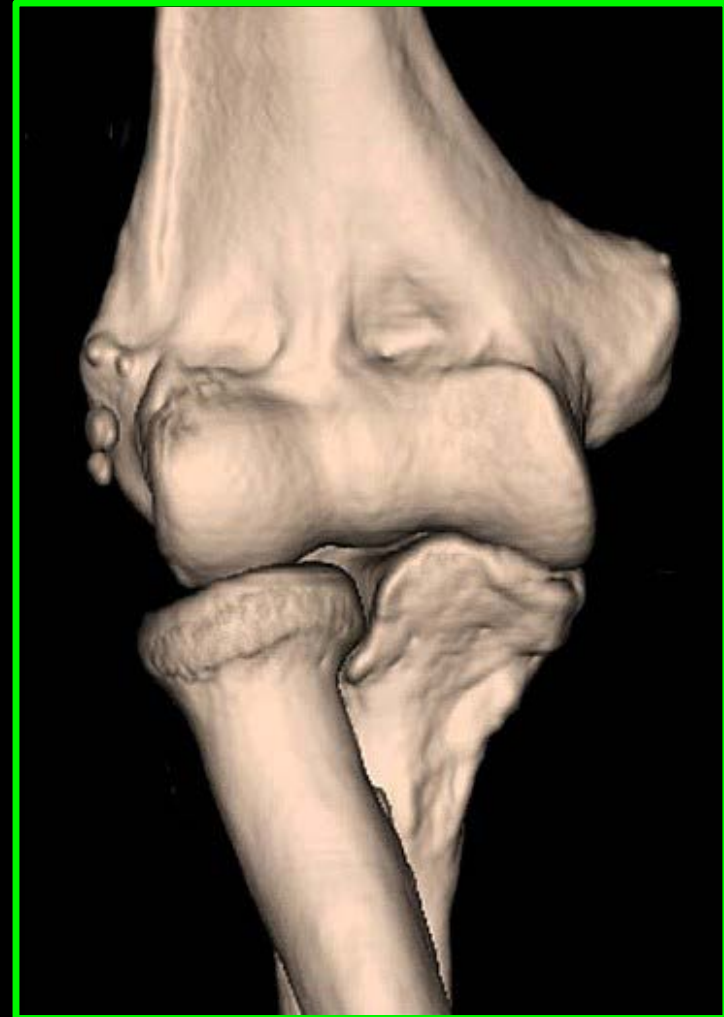# HO: Heterotopic Ossification

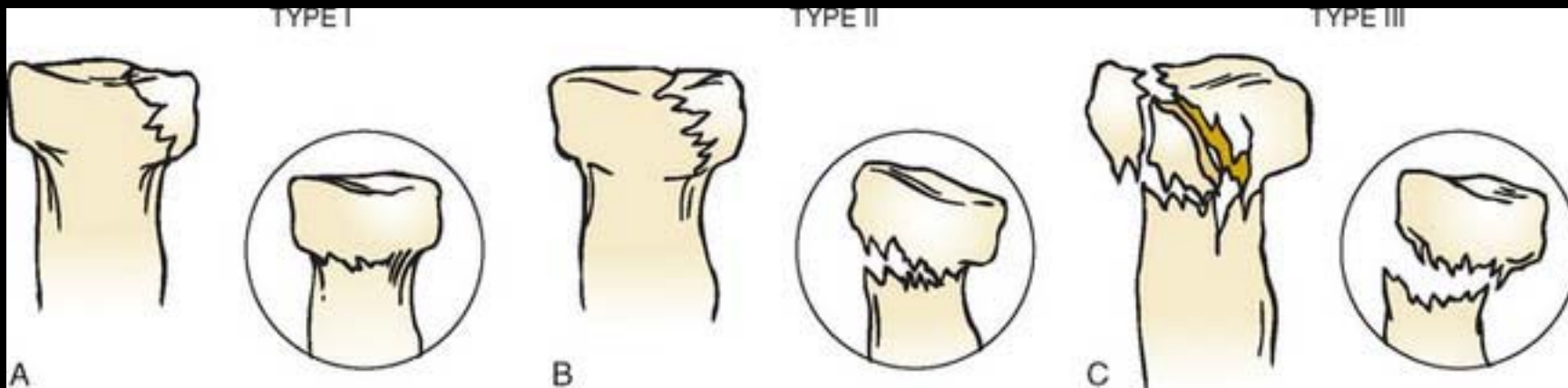
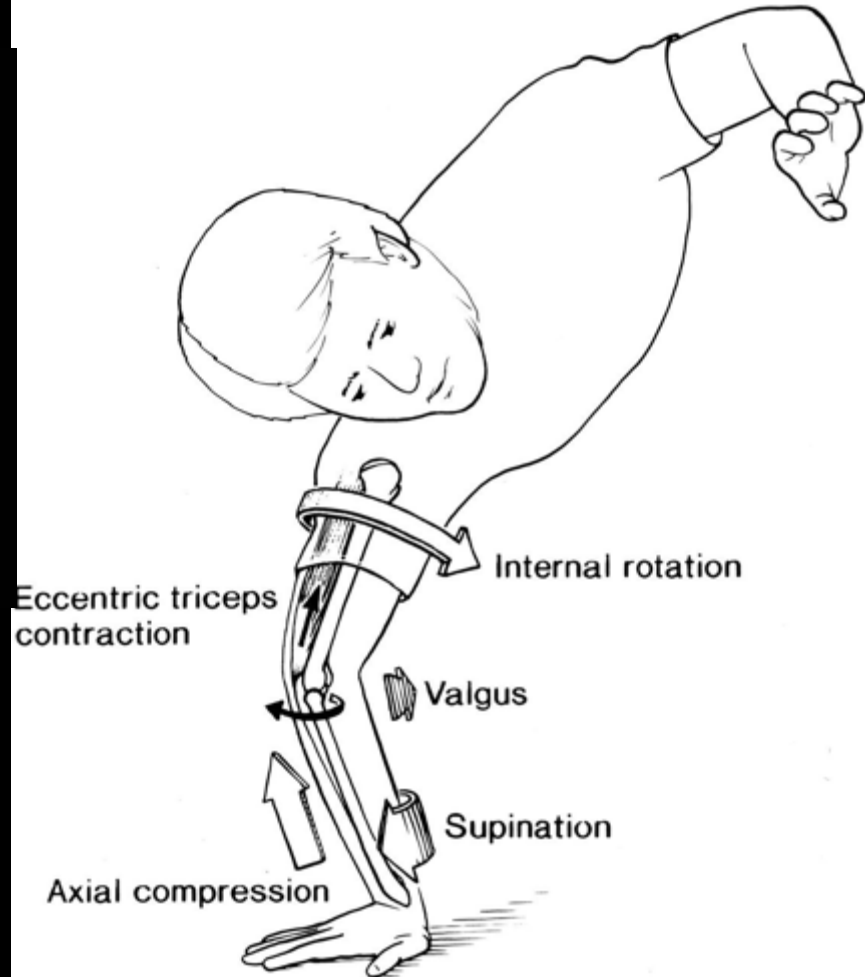
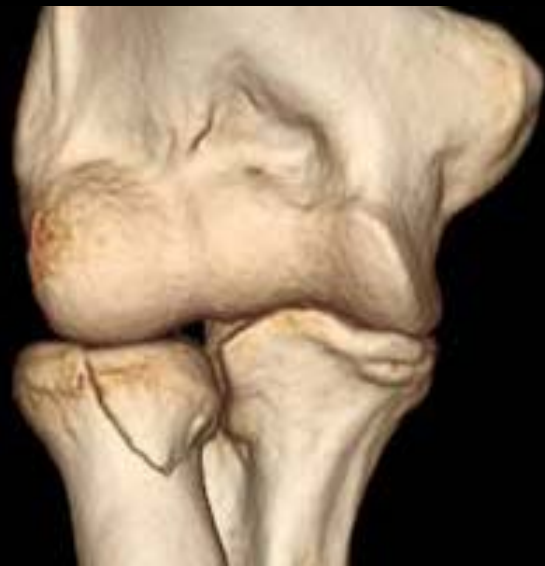
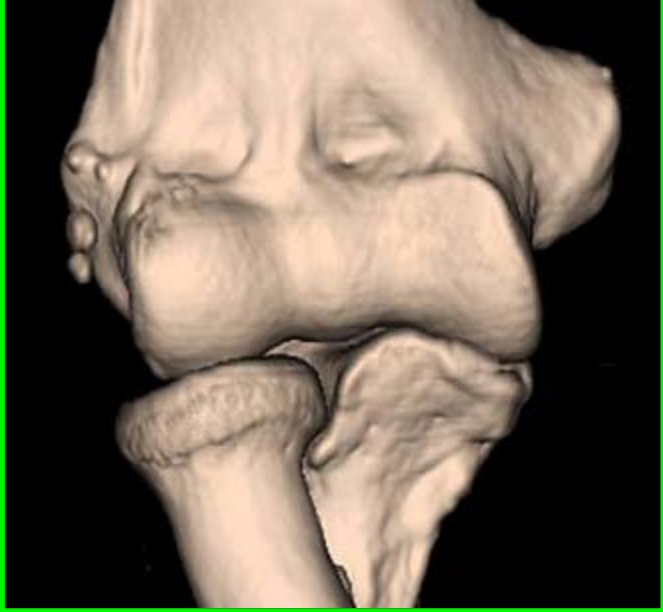


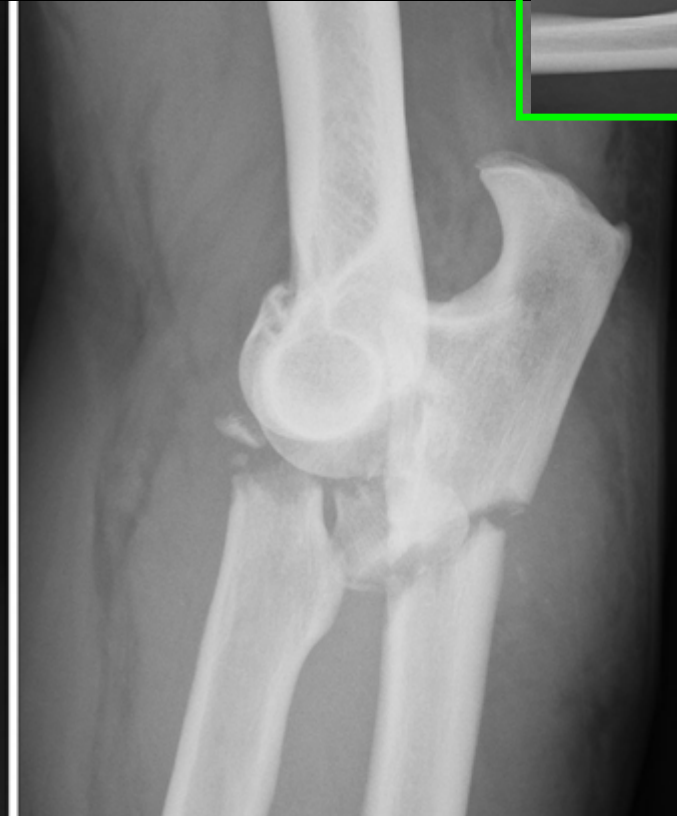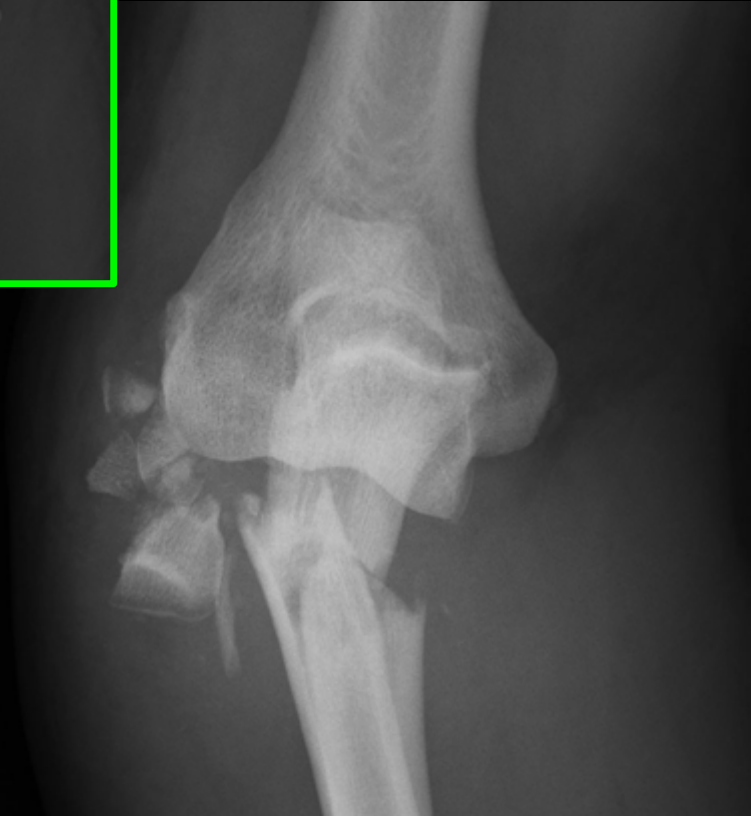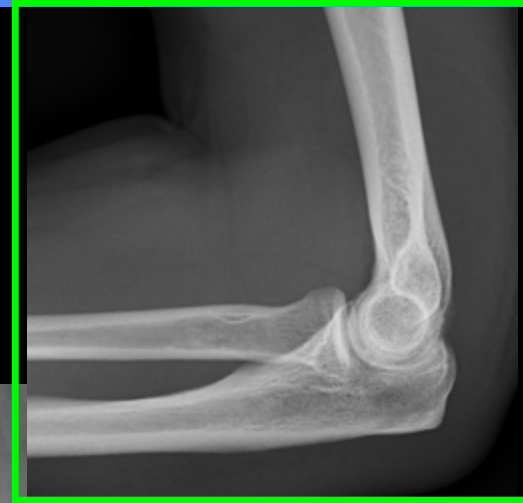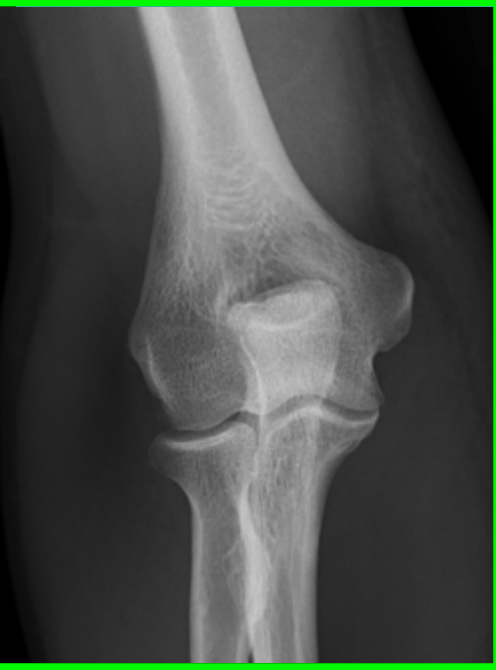# Radial Head/Neck

- Fall
- All ages
- Effects forearm pronsupination





# Radial Head/Neck Fx



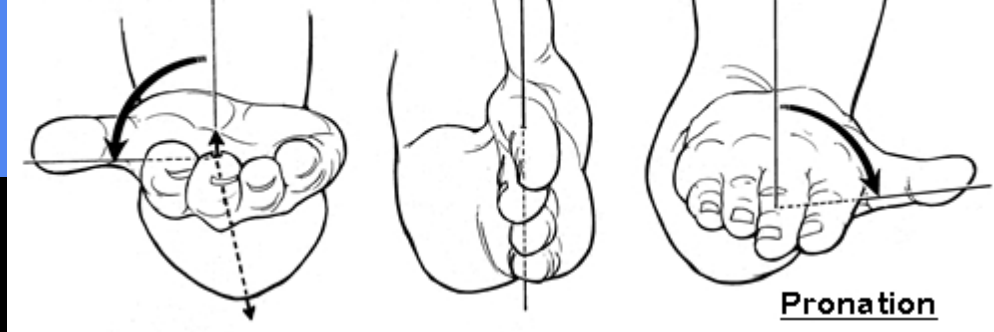


# Radial Head/Neck

Supination

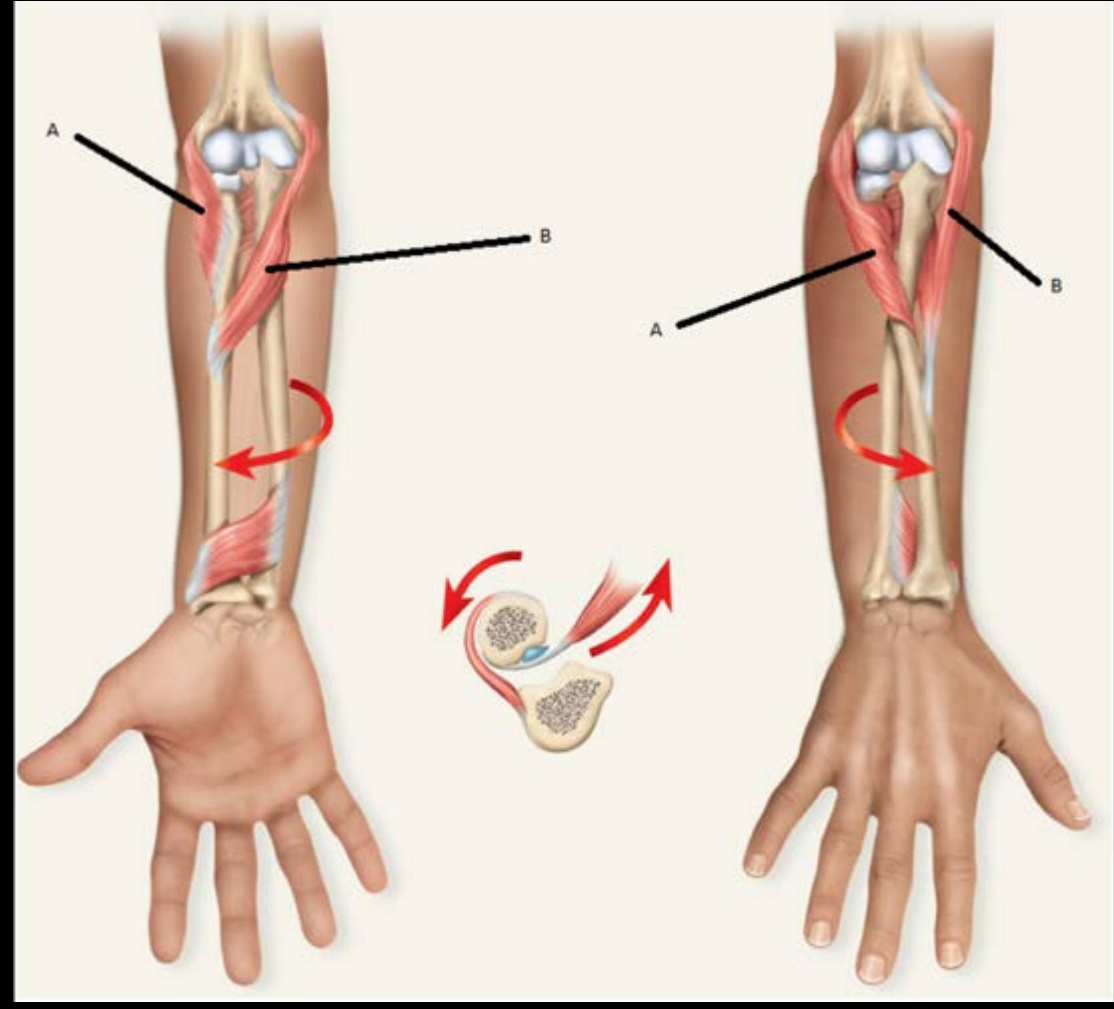
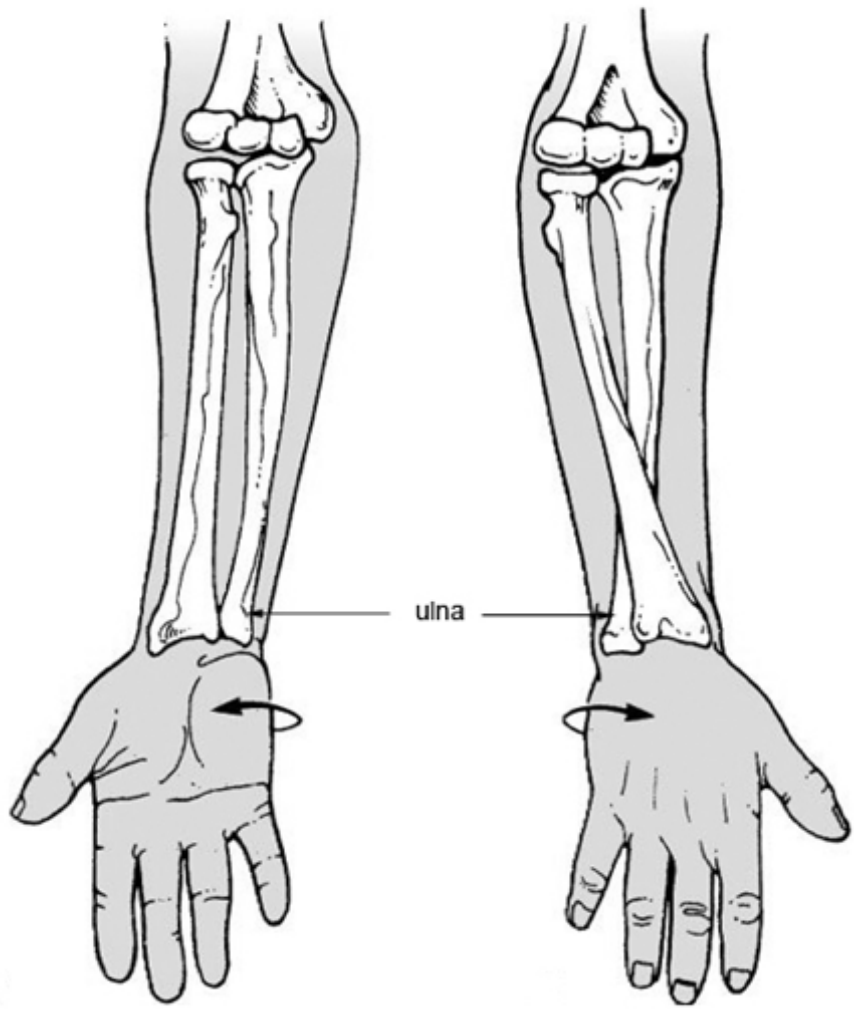
Neutral

Pronation

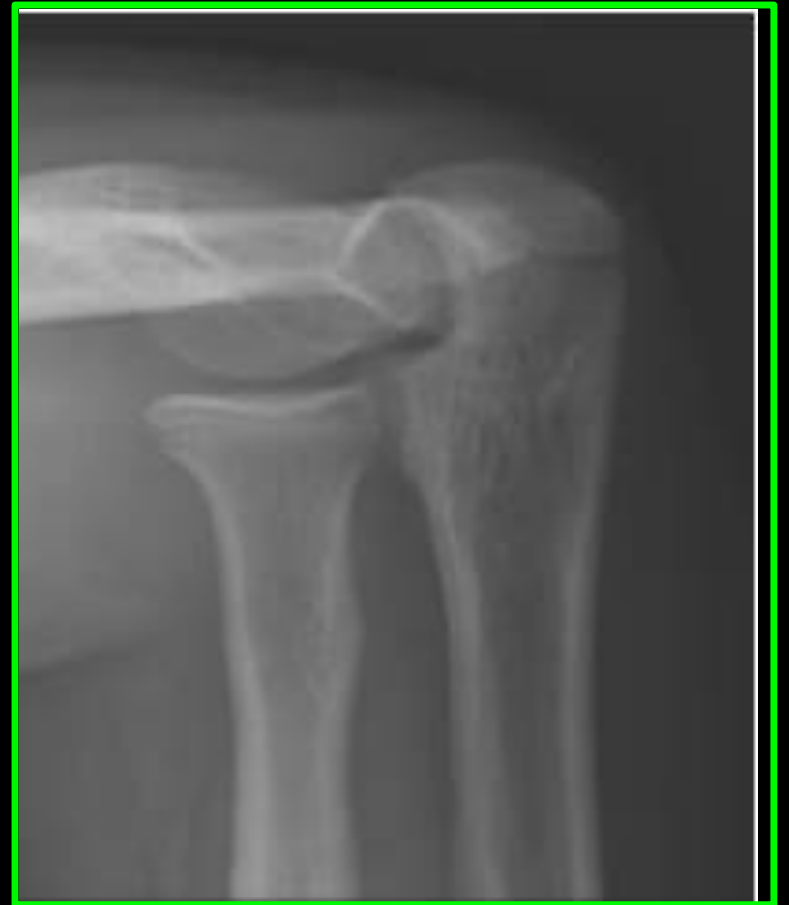
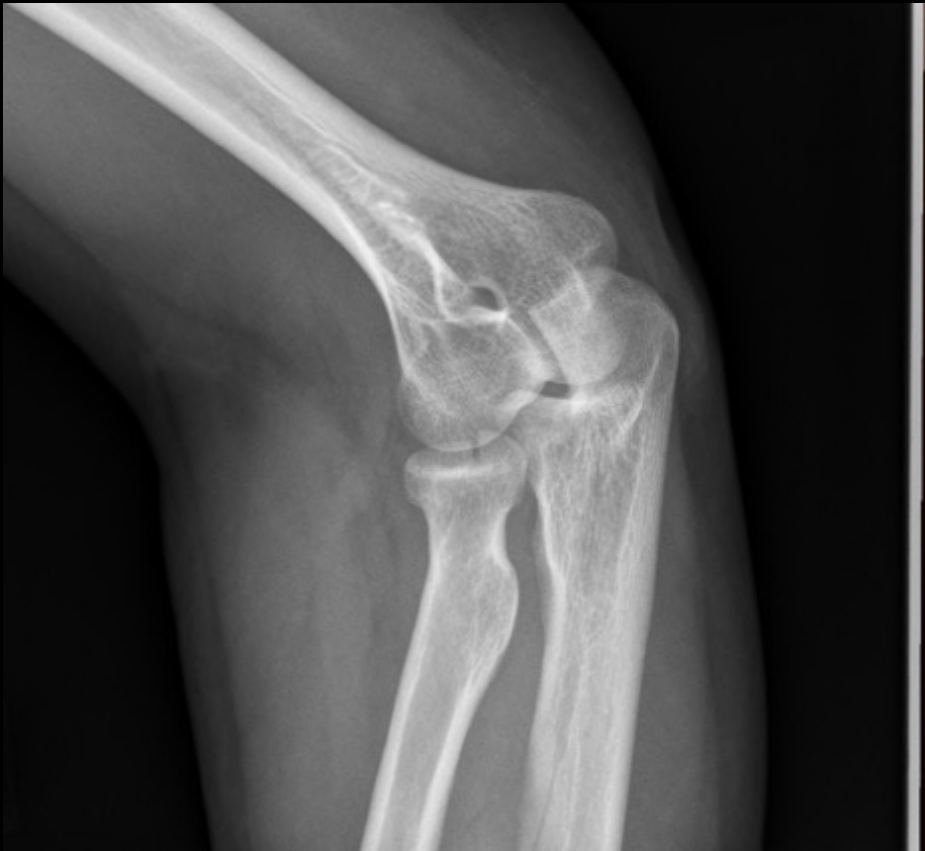
Supination

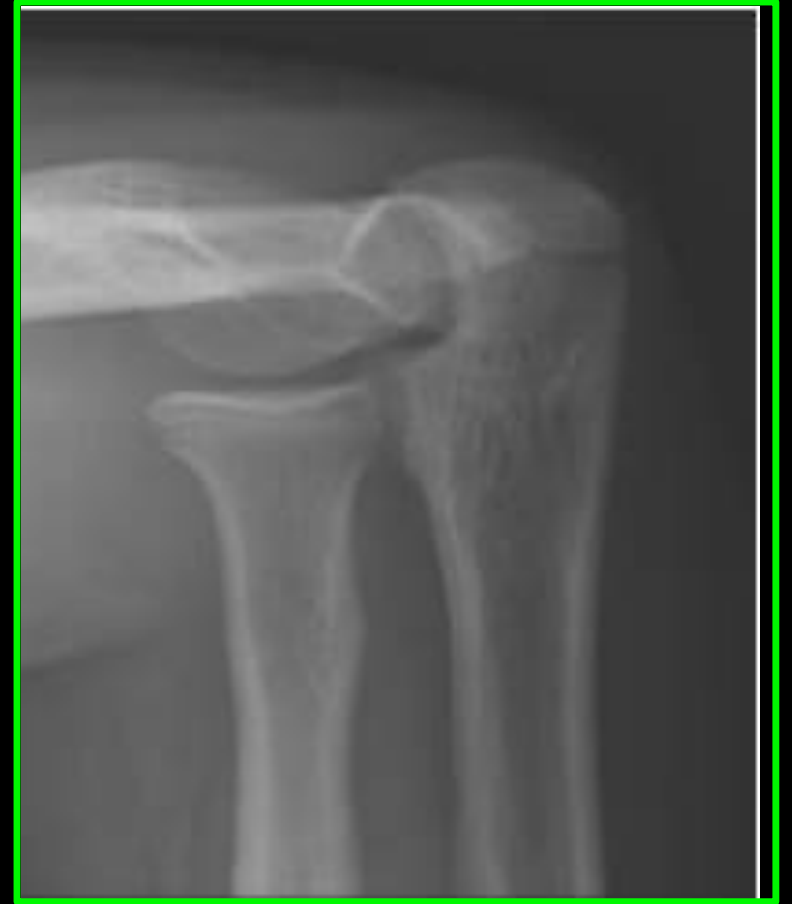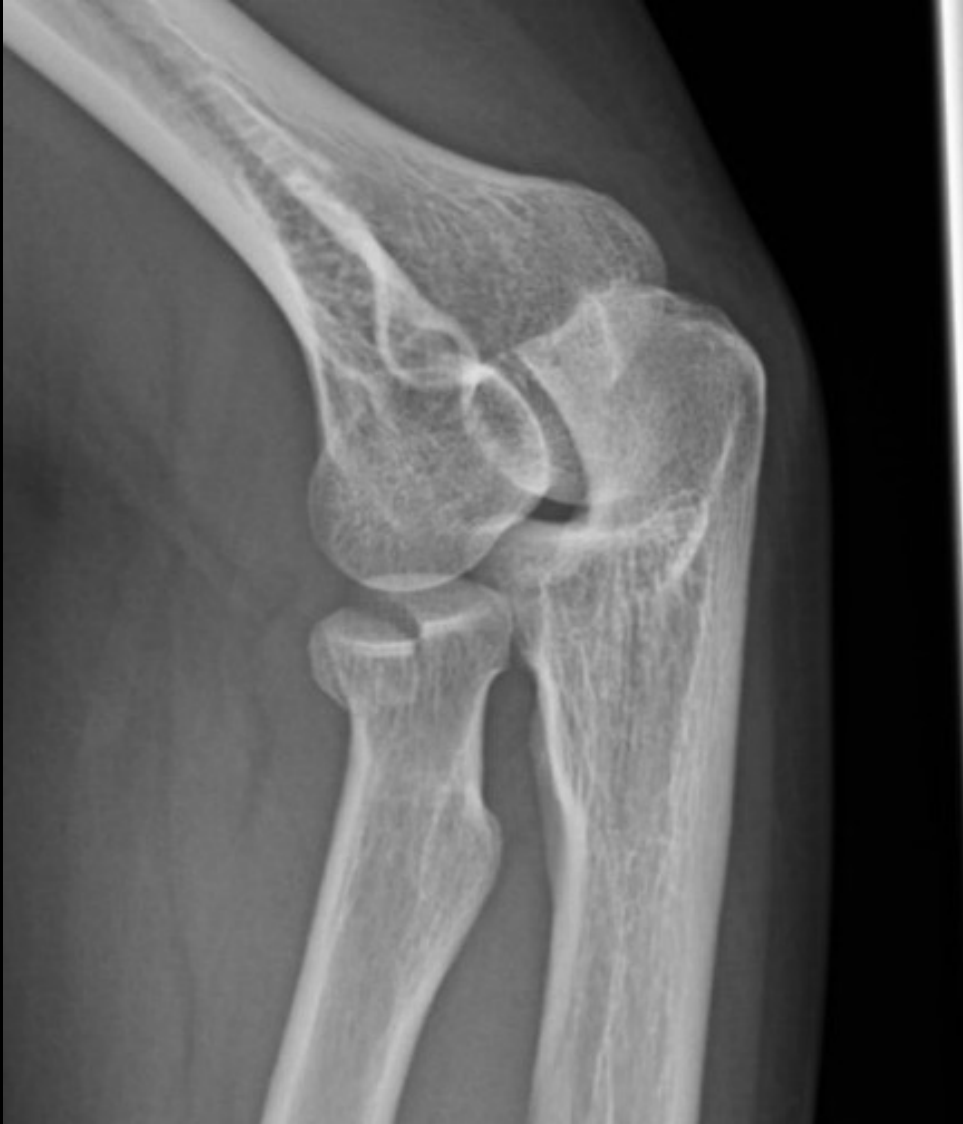Pronation



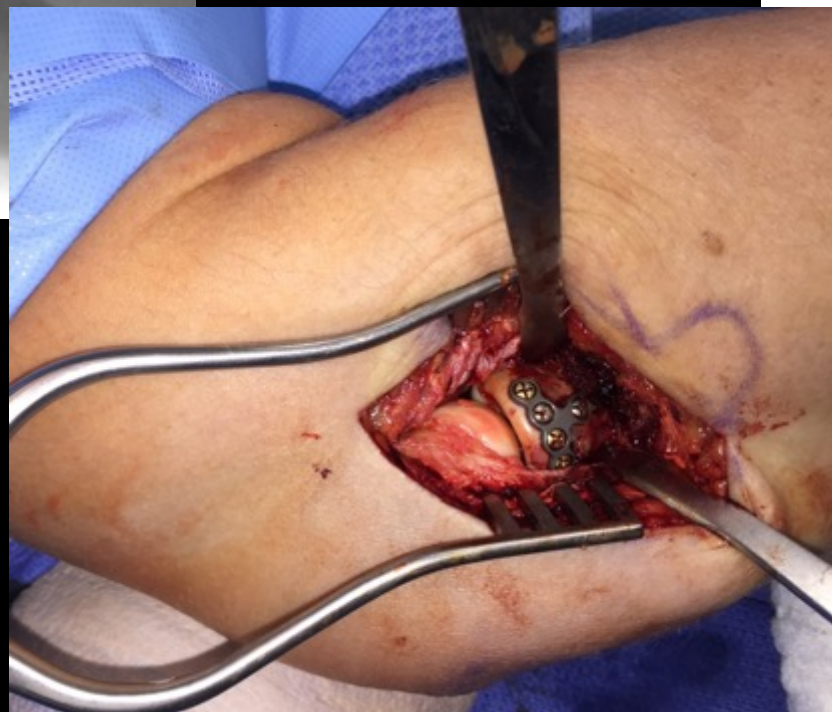
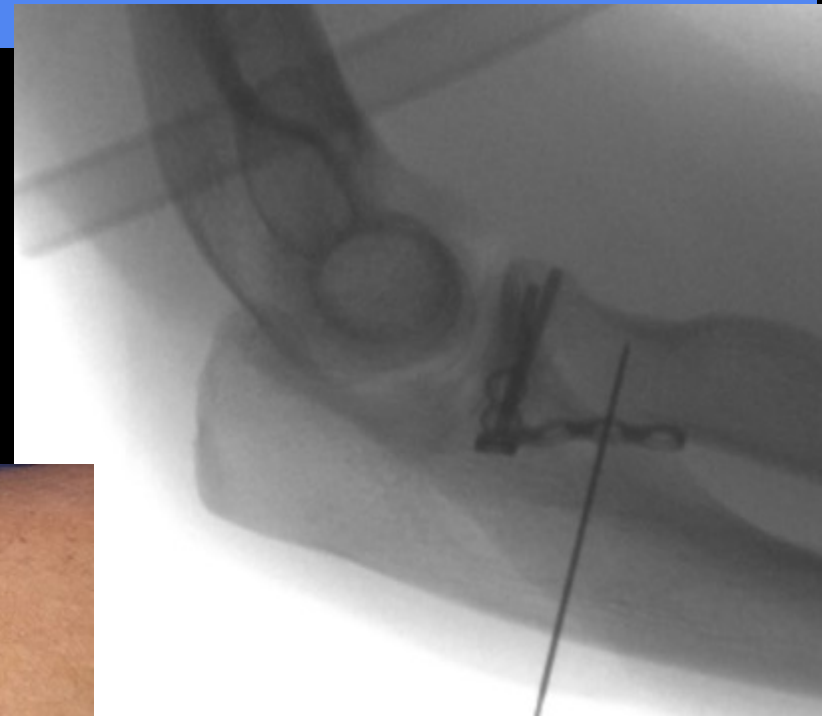
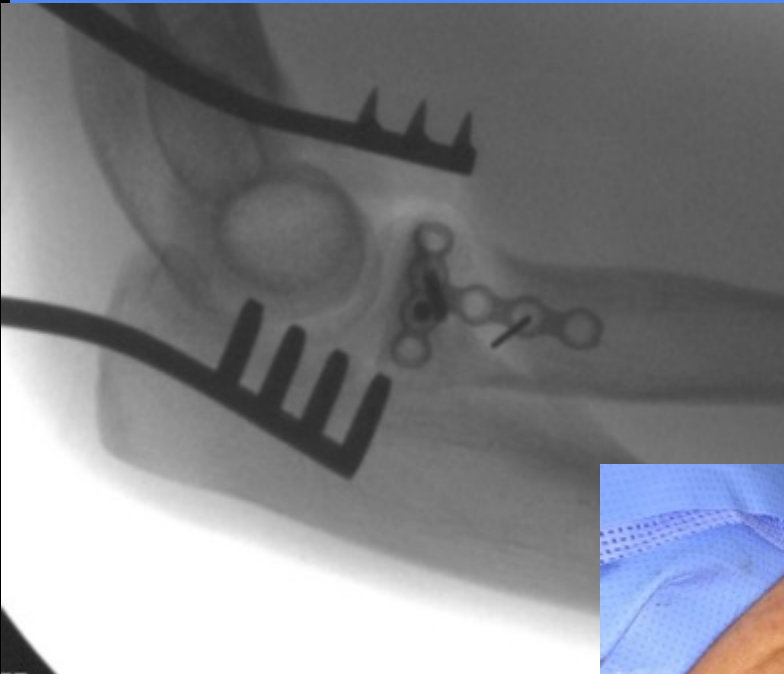
NW, 27 y/o female, s/p MVA, RHD, splinted  
in local ED, presented day #5



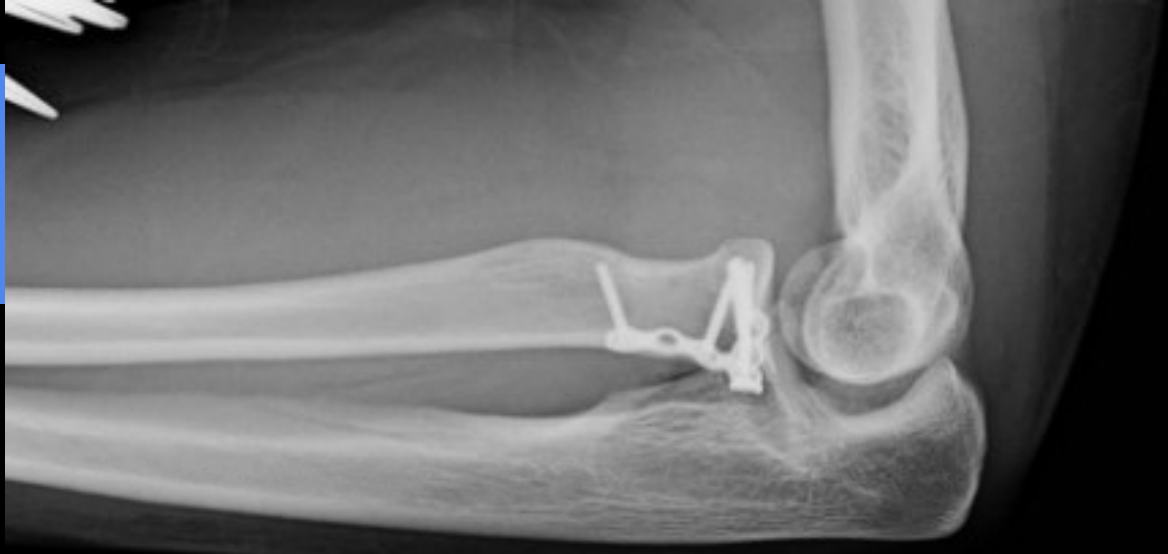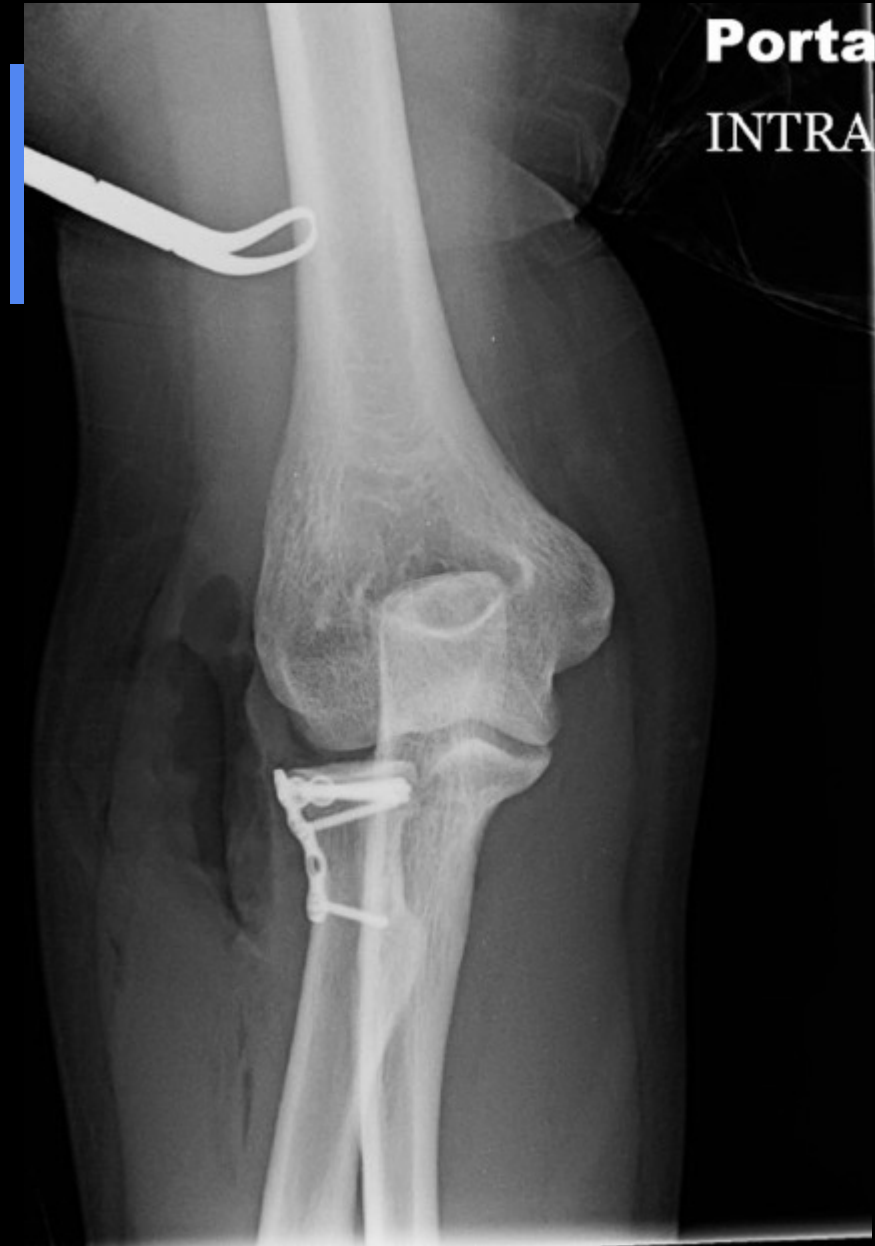1 week f/u



# Intraop

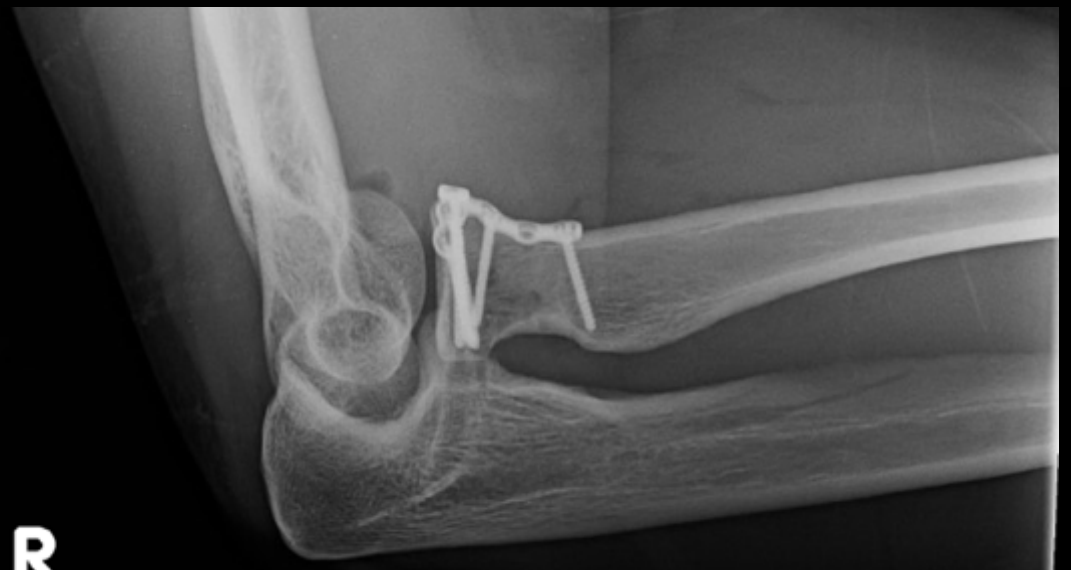

**Porta**  
**INTRA**

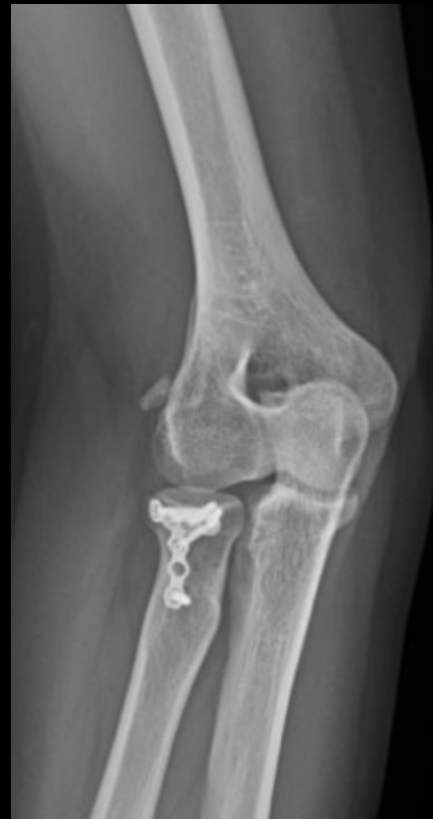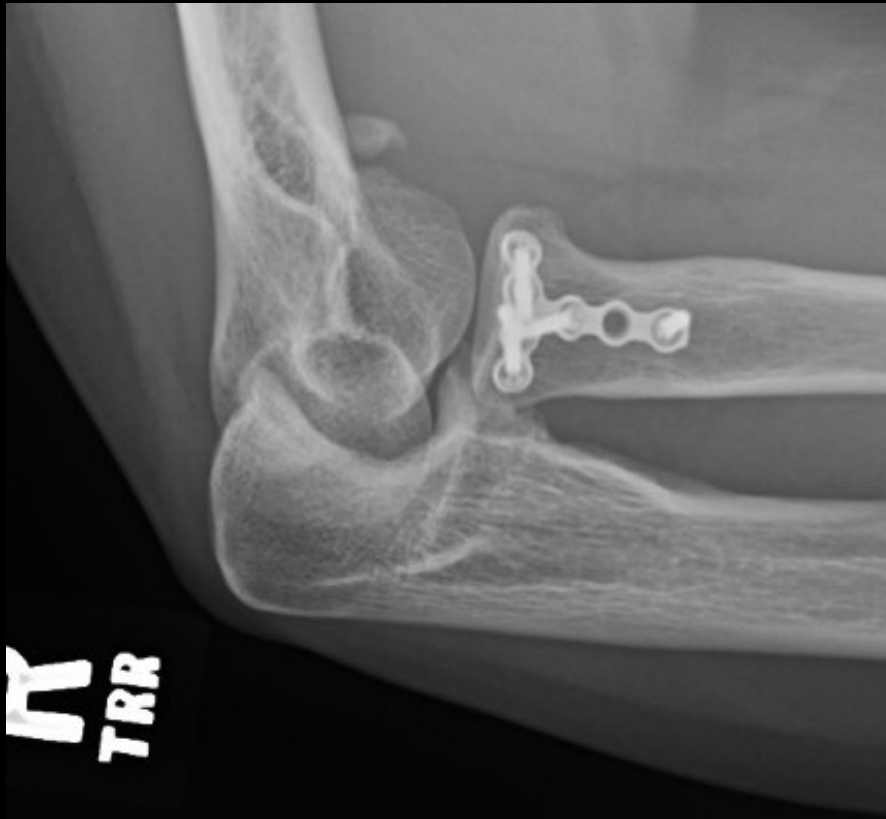


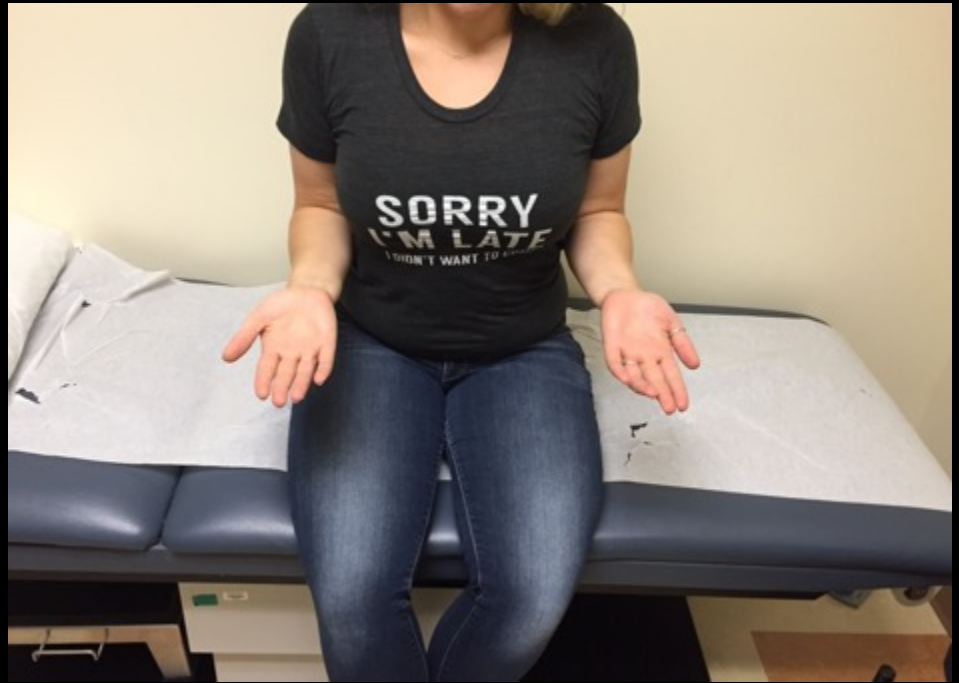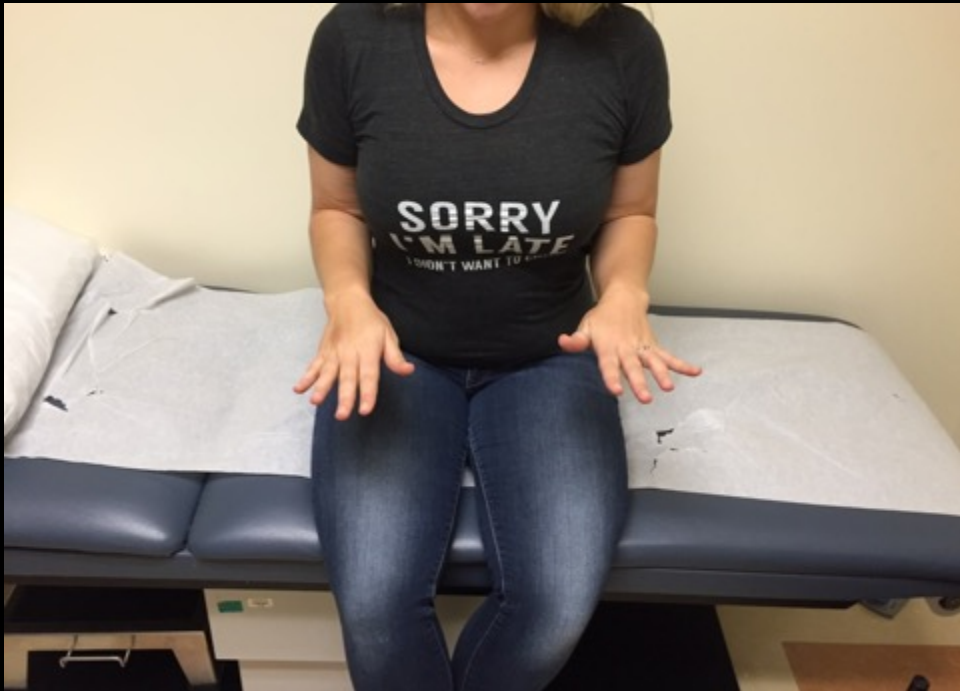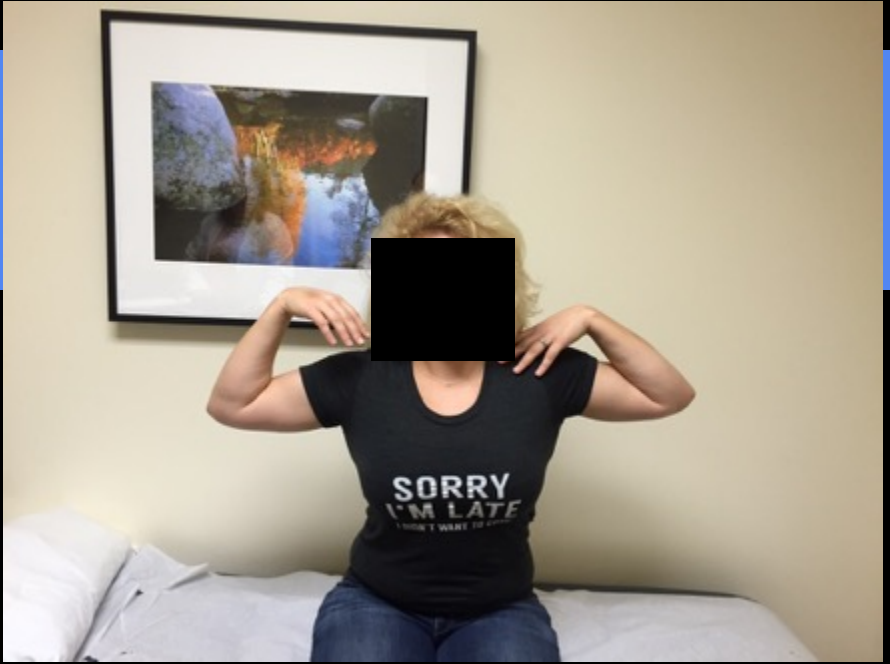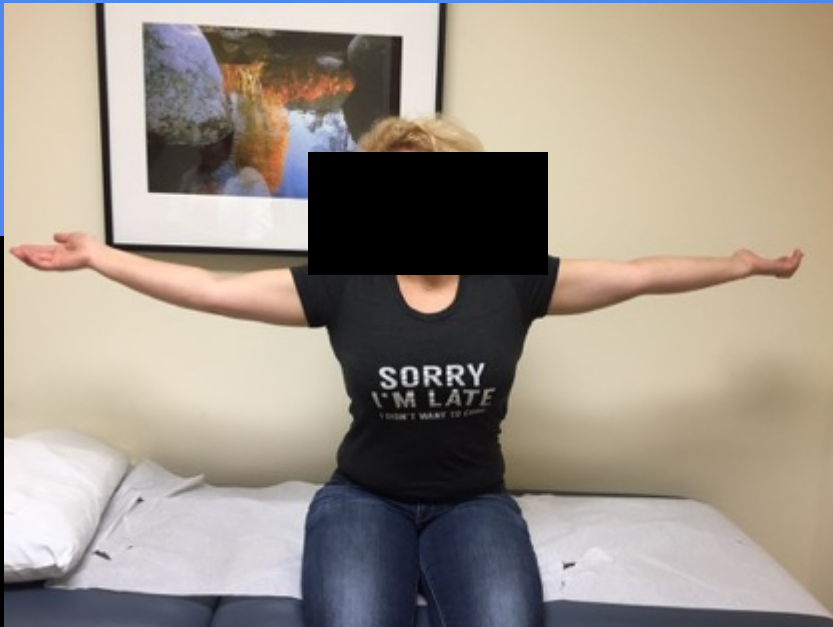**R**

**Portable**  
**INTRA-OP**

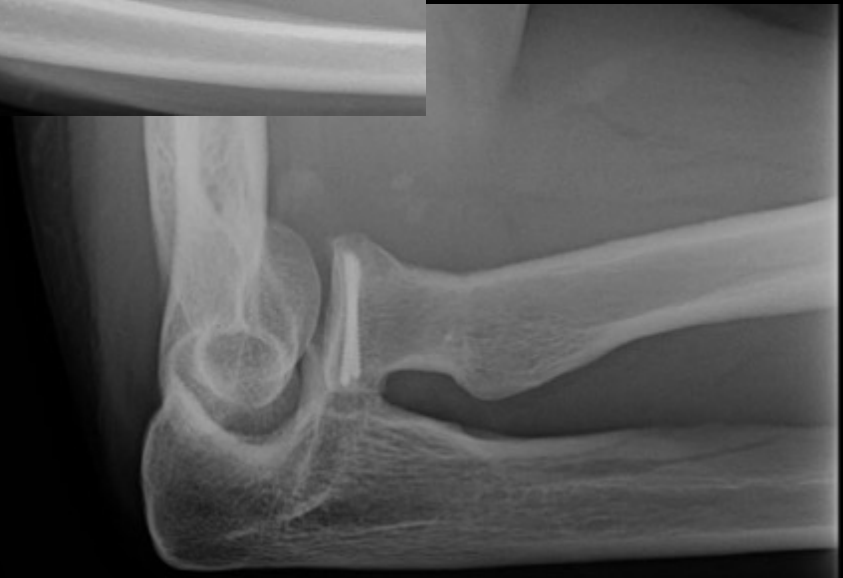
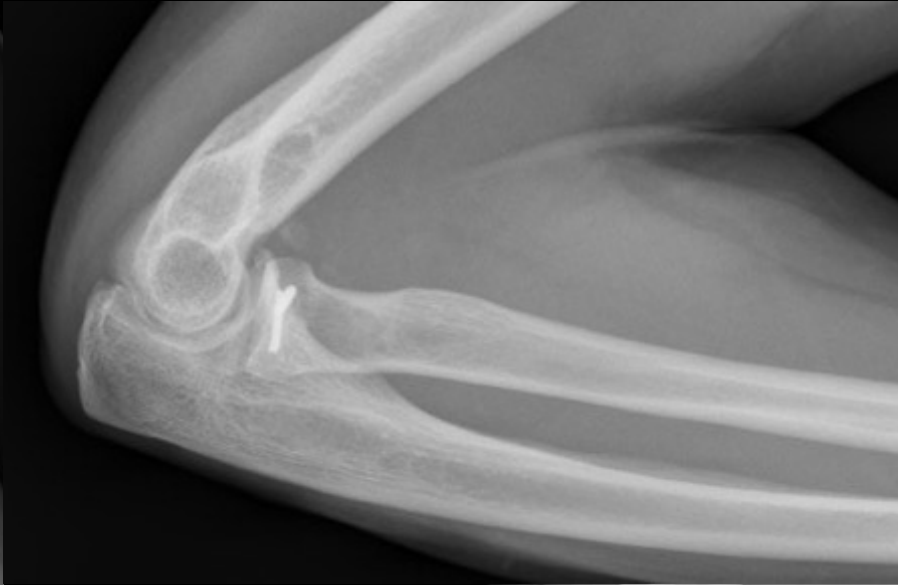
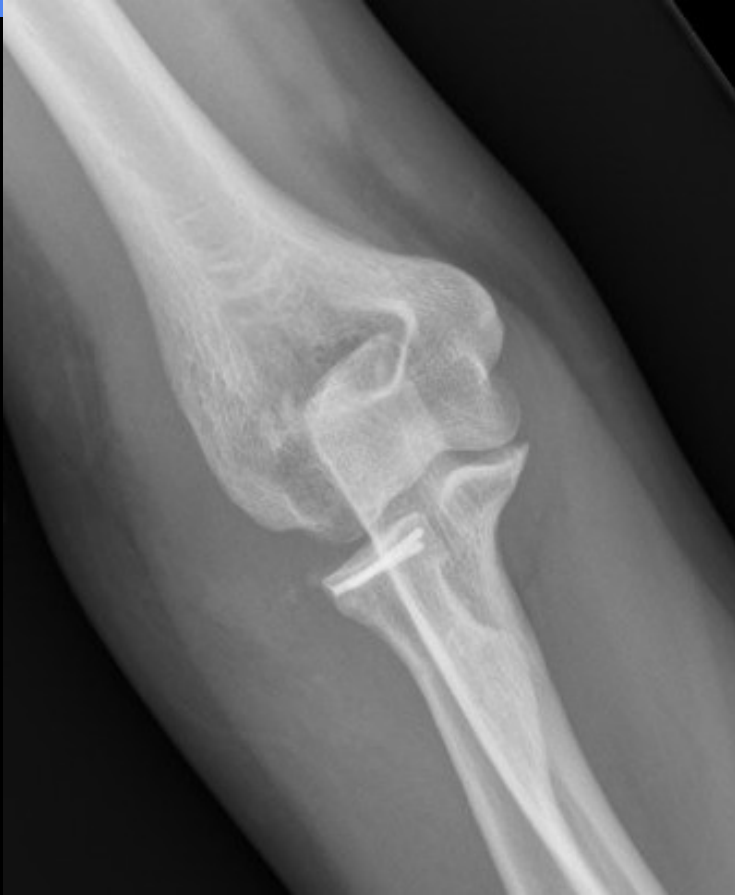# 9 months postop c/o pain with end-supination, end-pronation





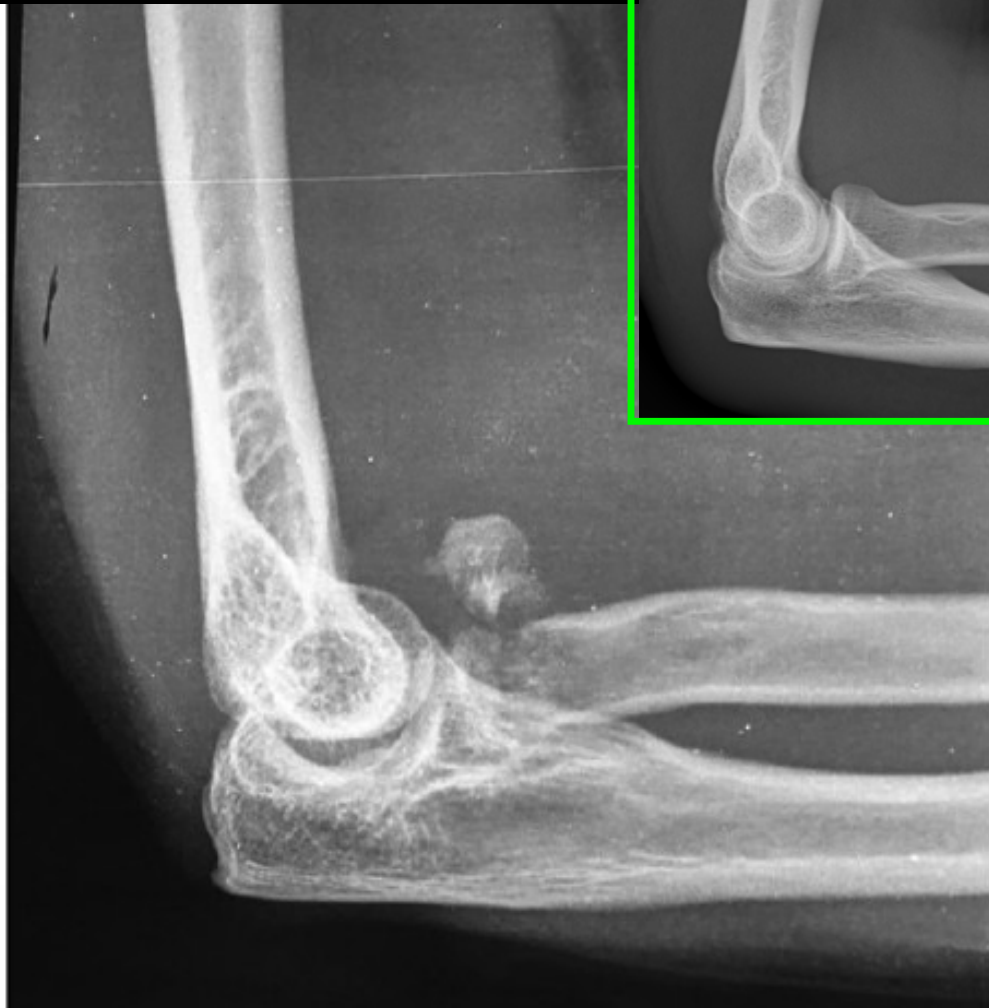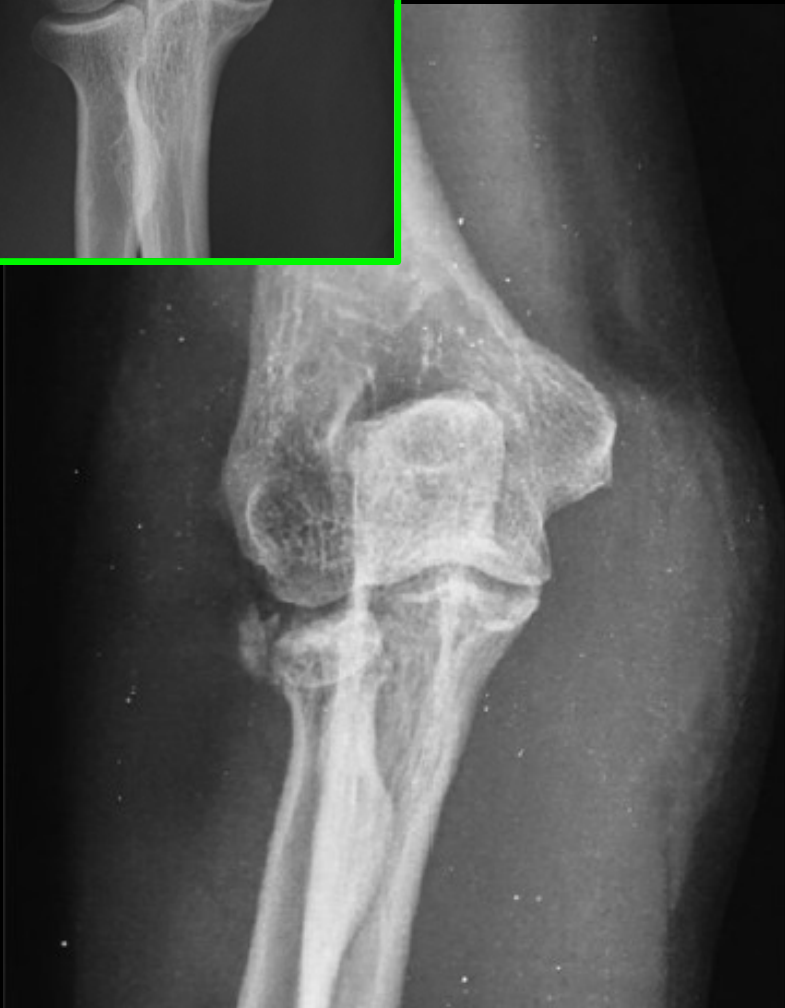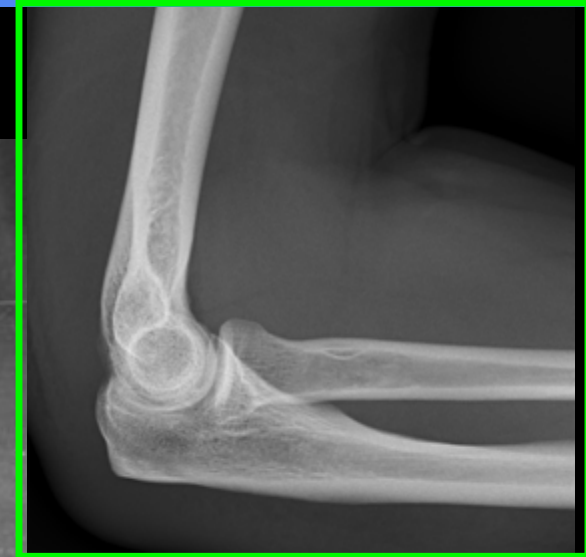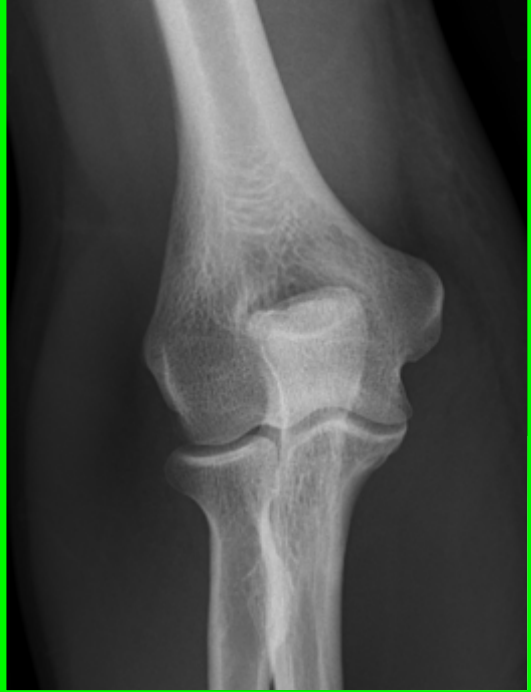1 yr postop



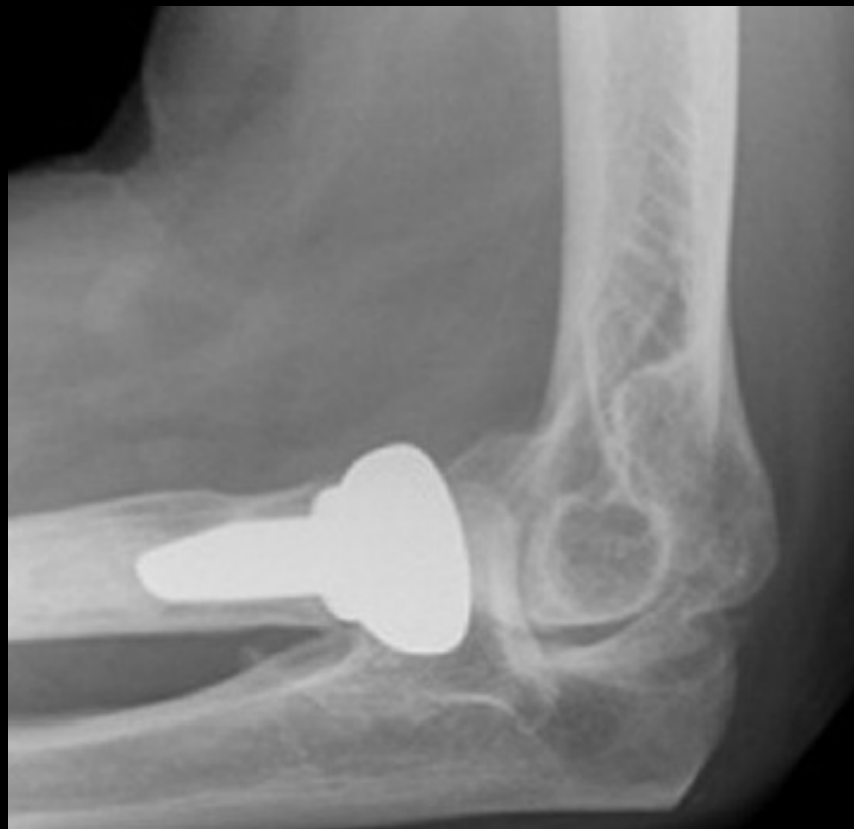
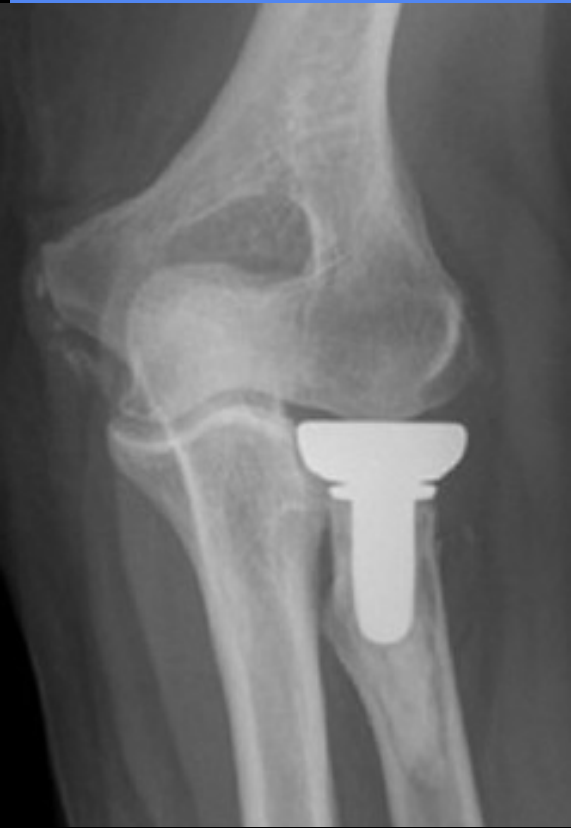R



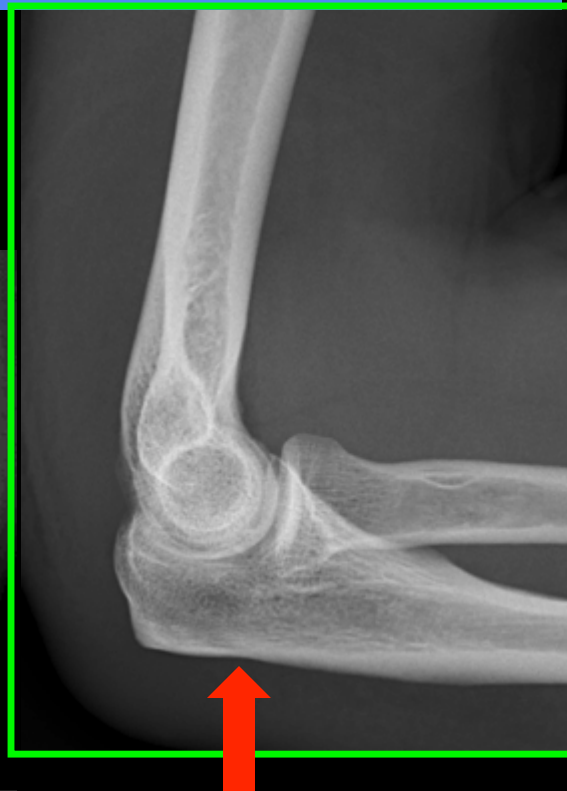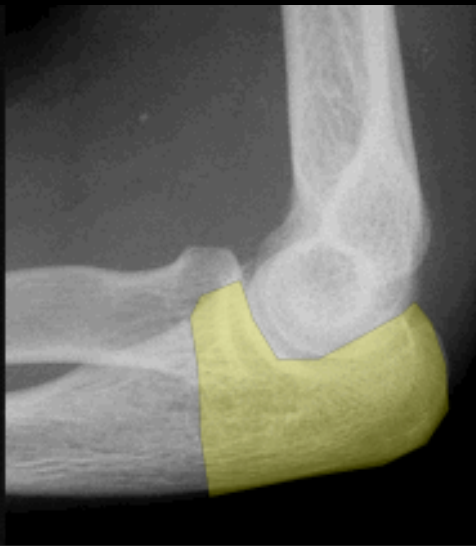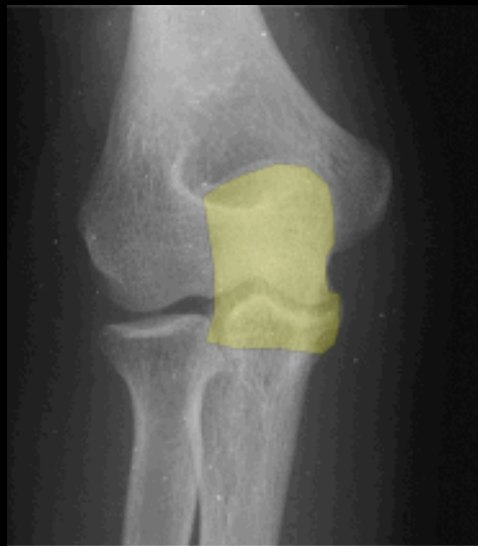
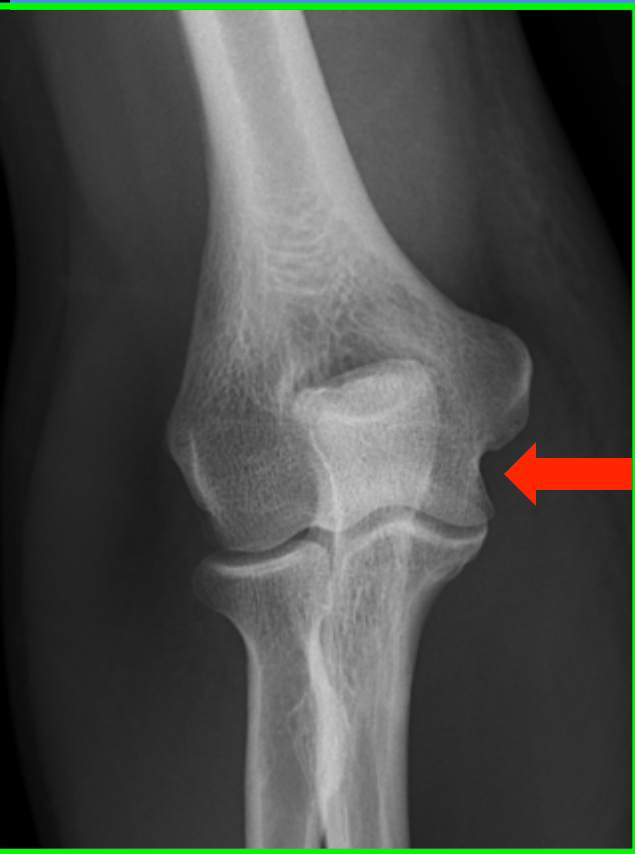34 y/o, fall of bike



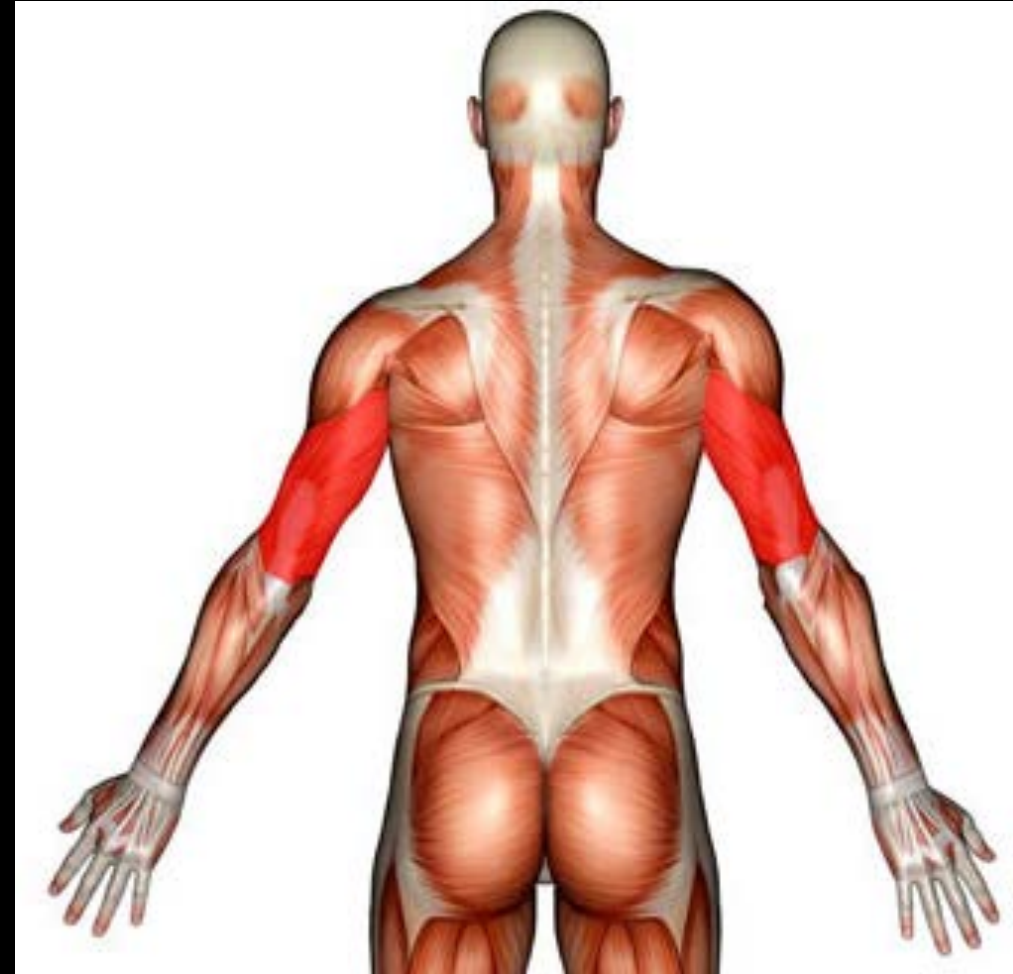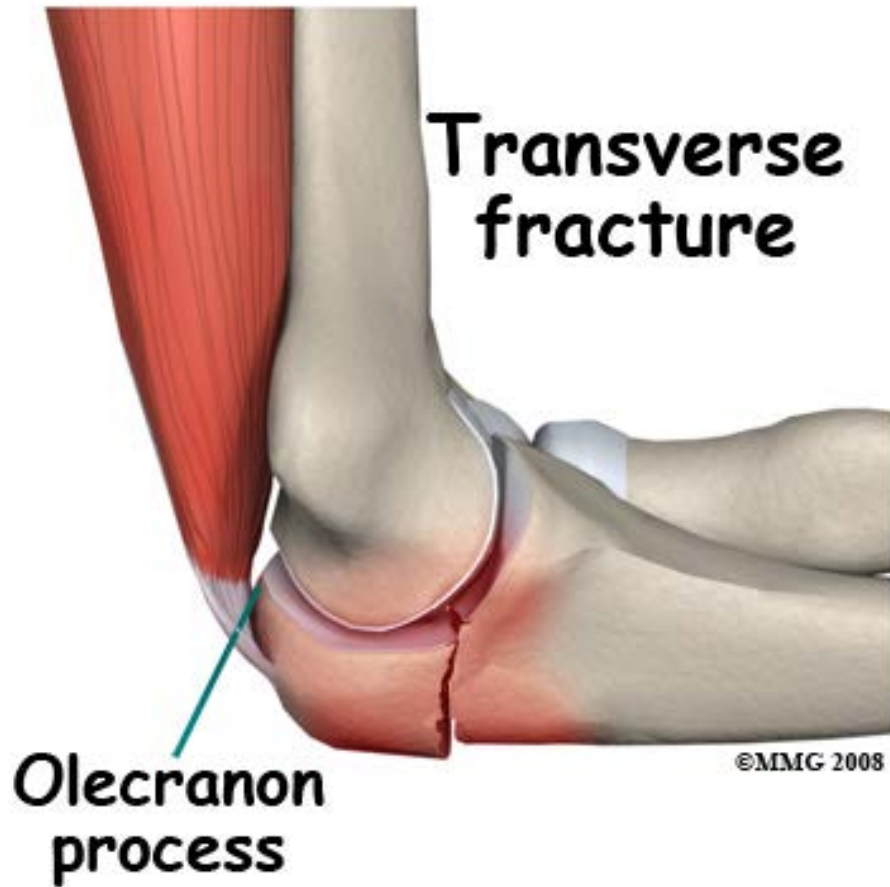
34 y/o, fall of bike



# Olecranon



# Olecranon

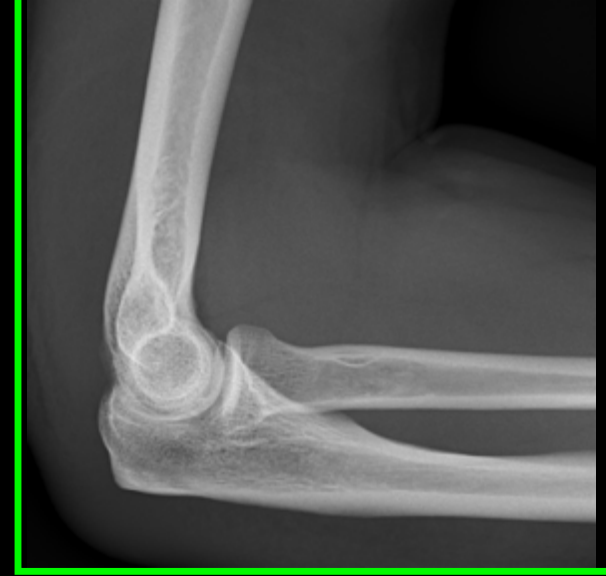


# Olecranon Fx

- Fall onto elbow
- FOOSH

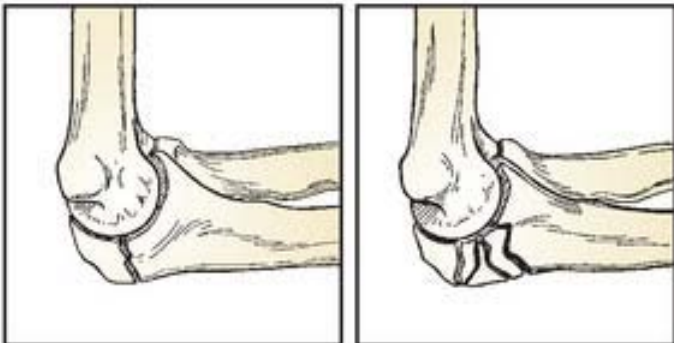


# Olecranon Fx

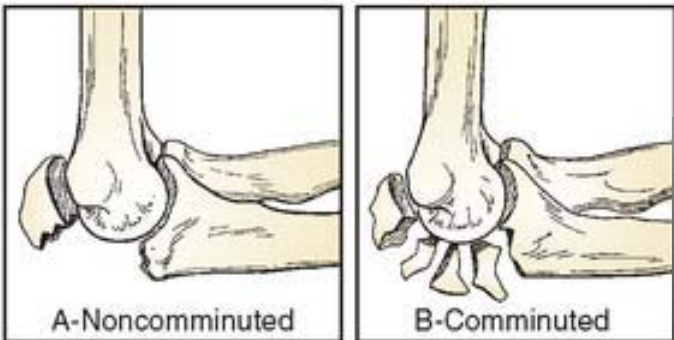


CLASSIFICATION OF OLECRANON FRACTURES (Morrey)

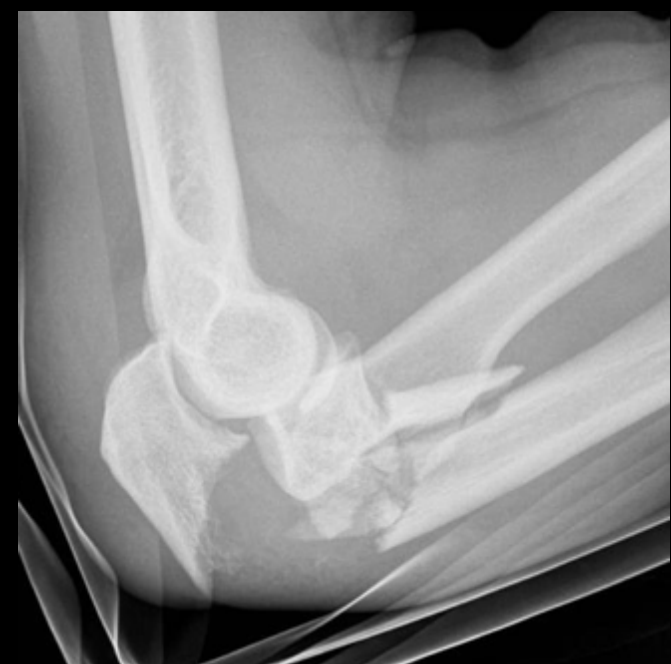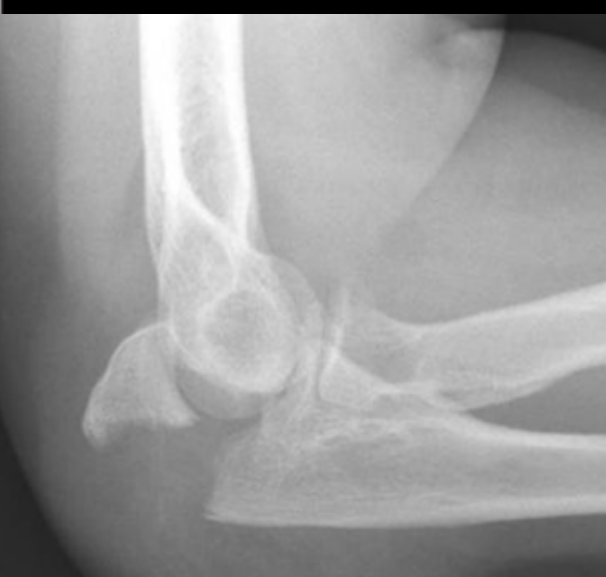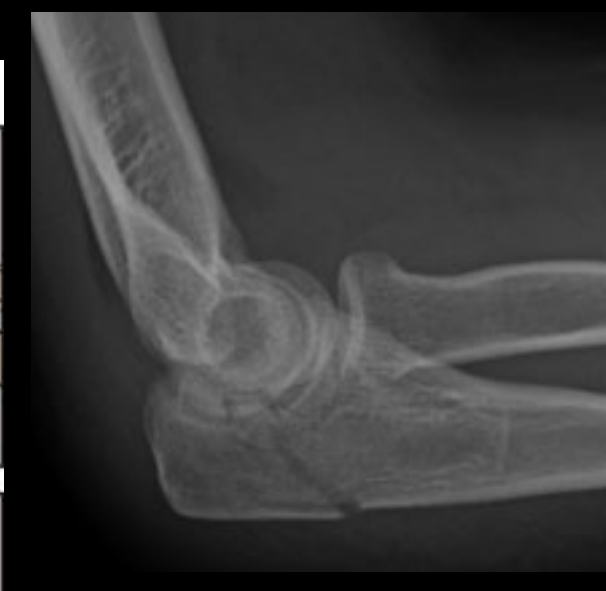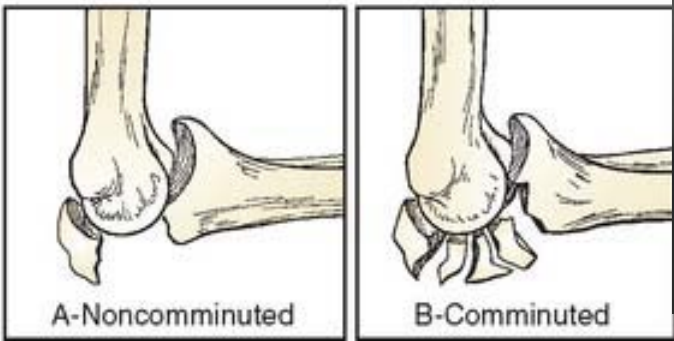
Type I  
Undisplaced



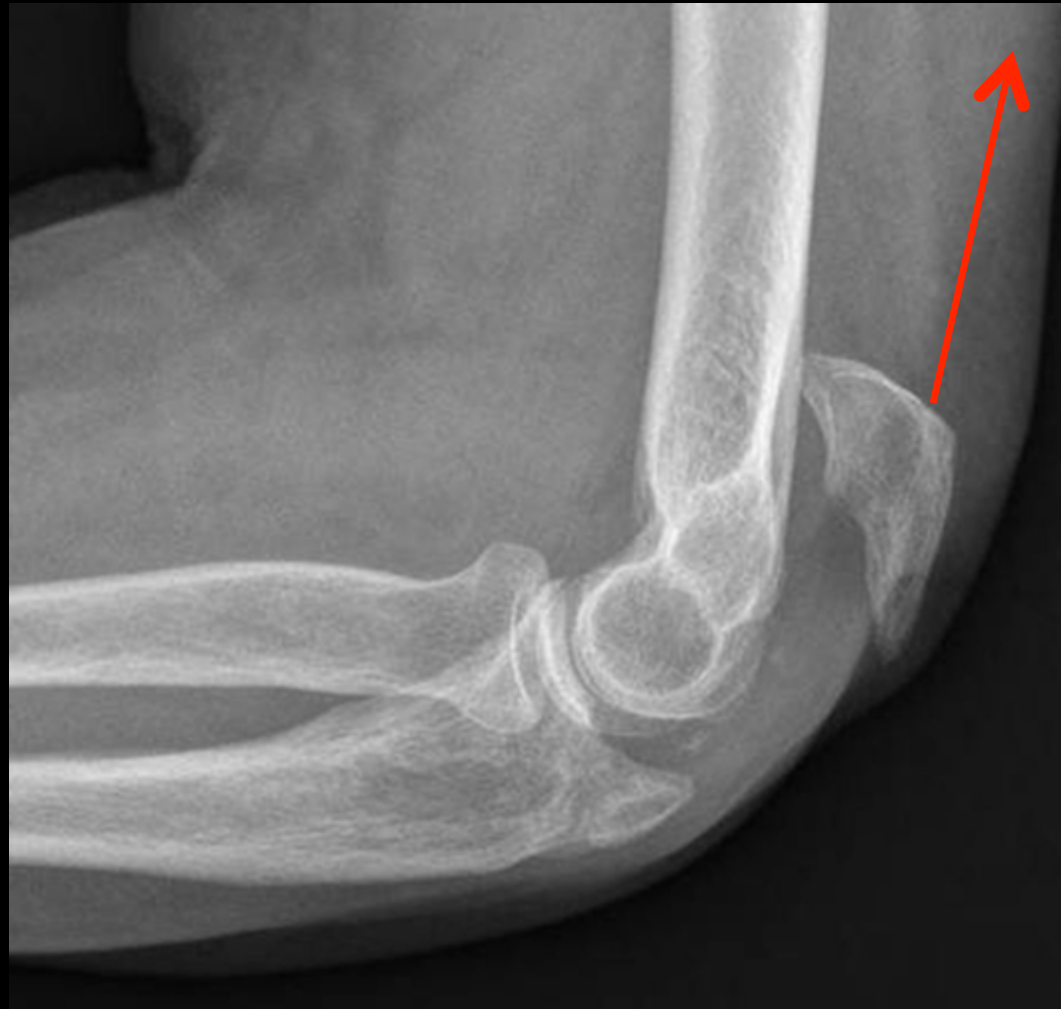Type II  
Displaced-stable



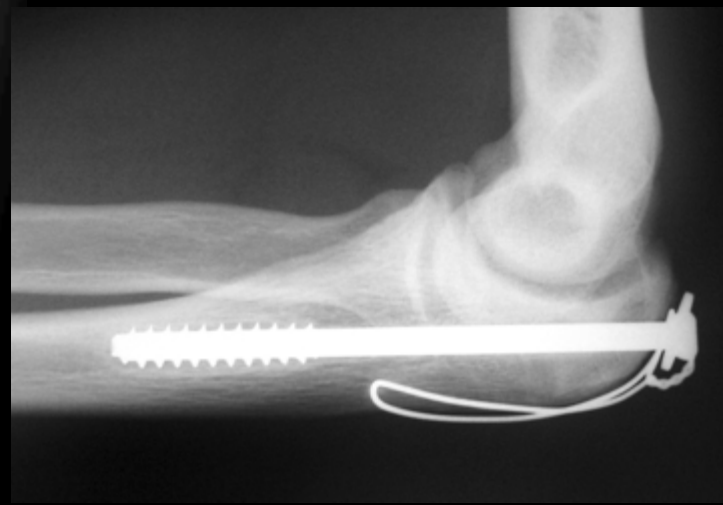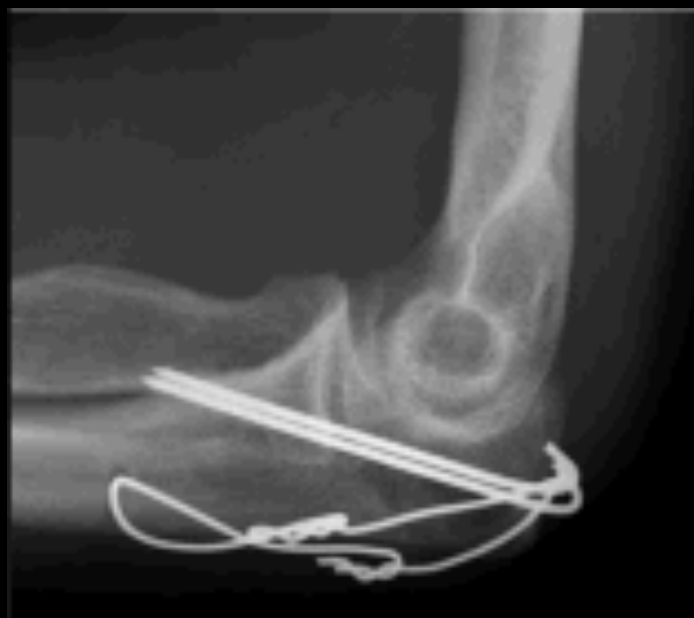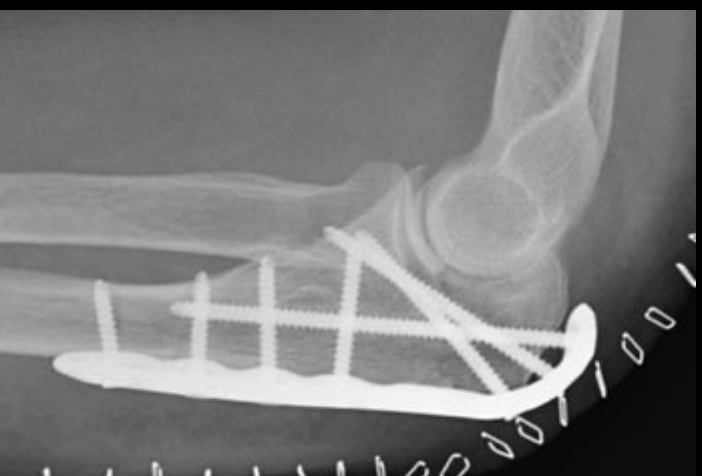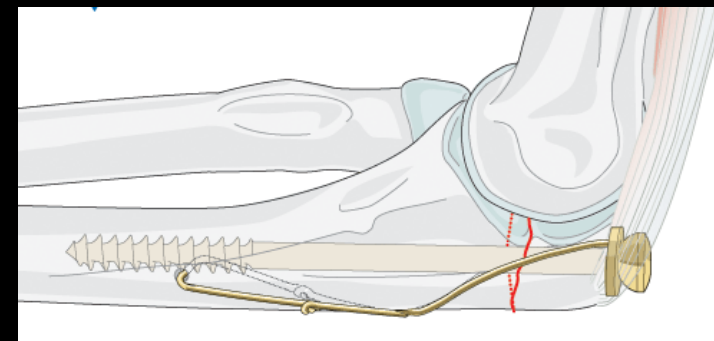
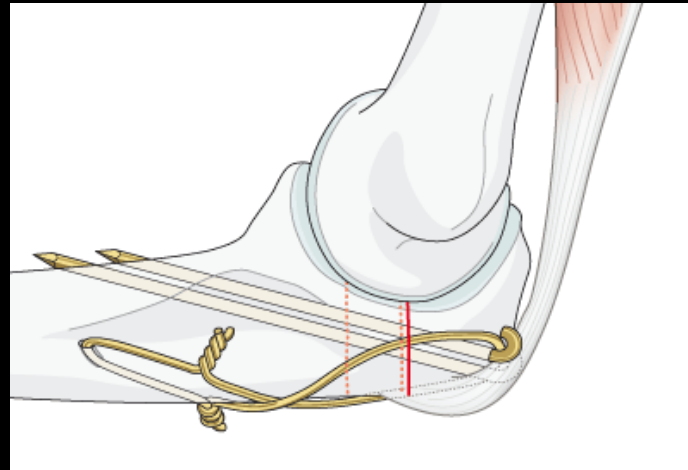
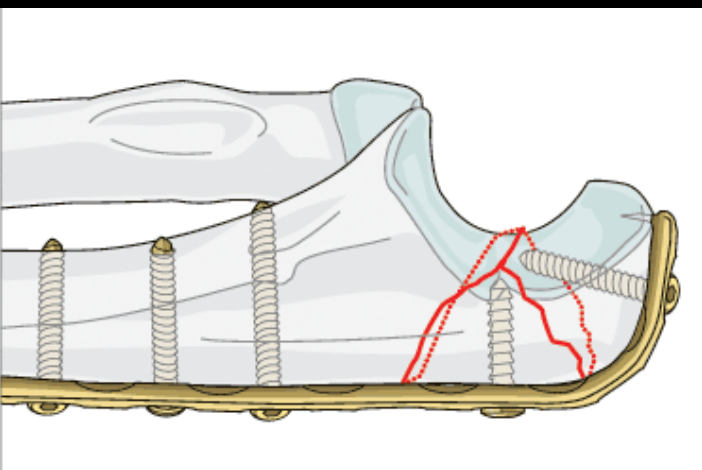
Type III  
Unstable



# Olecranon Fx

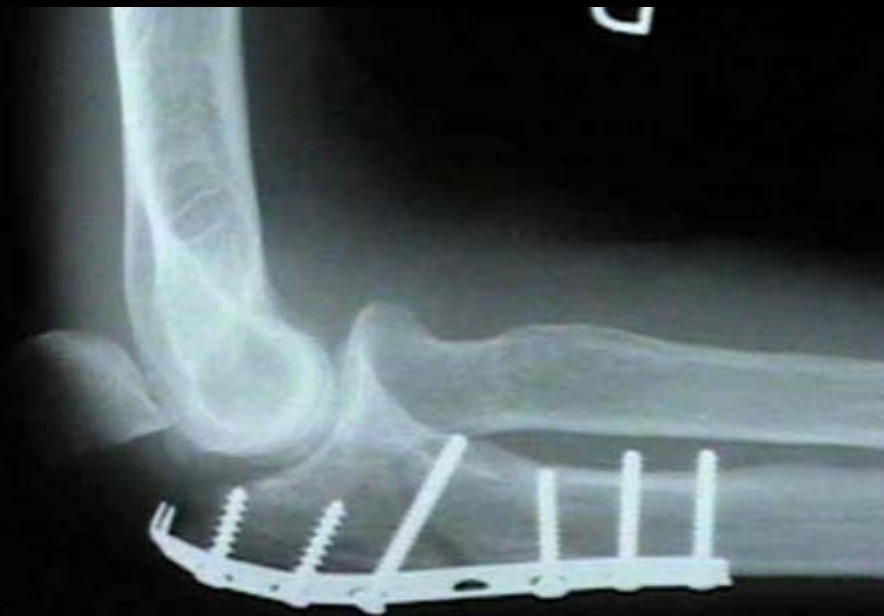
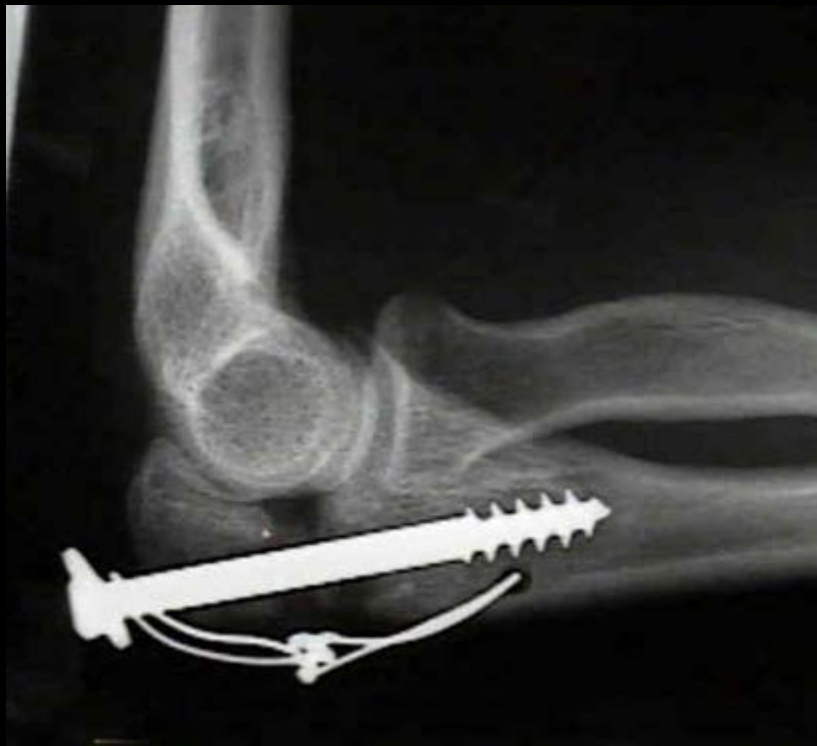
# Olecranon Fx - Fixation

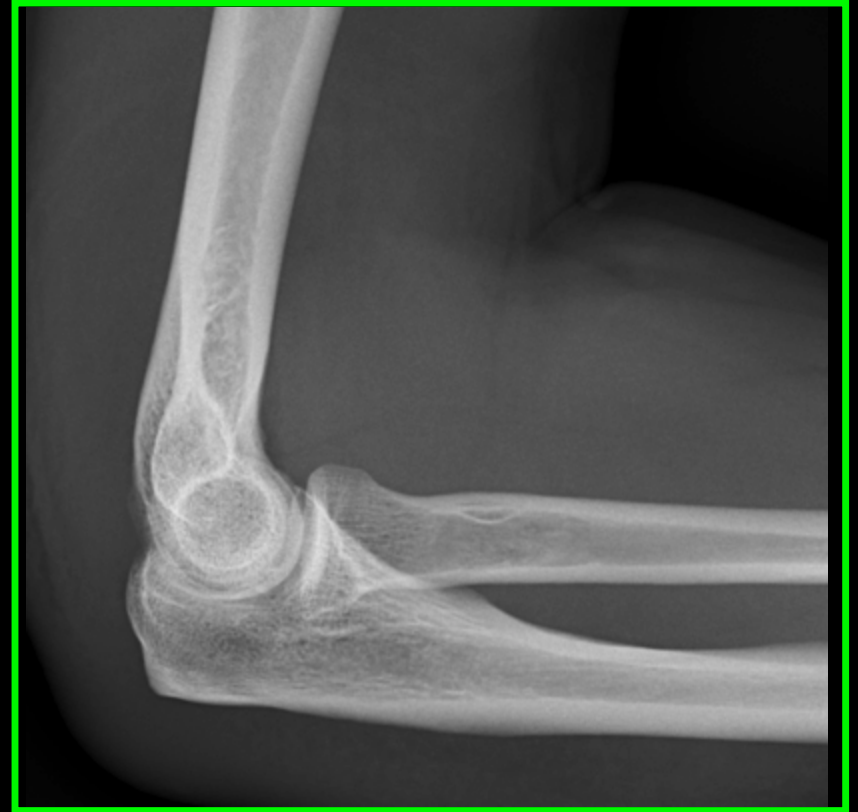
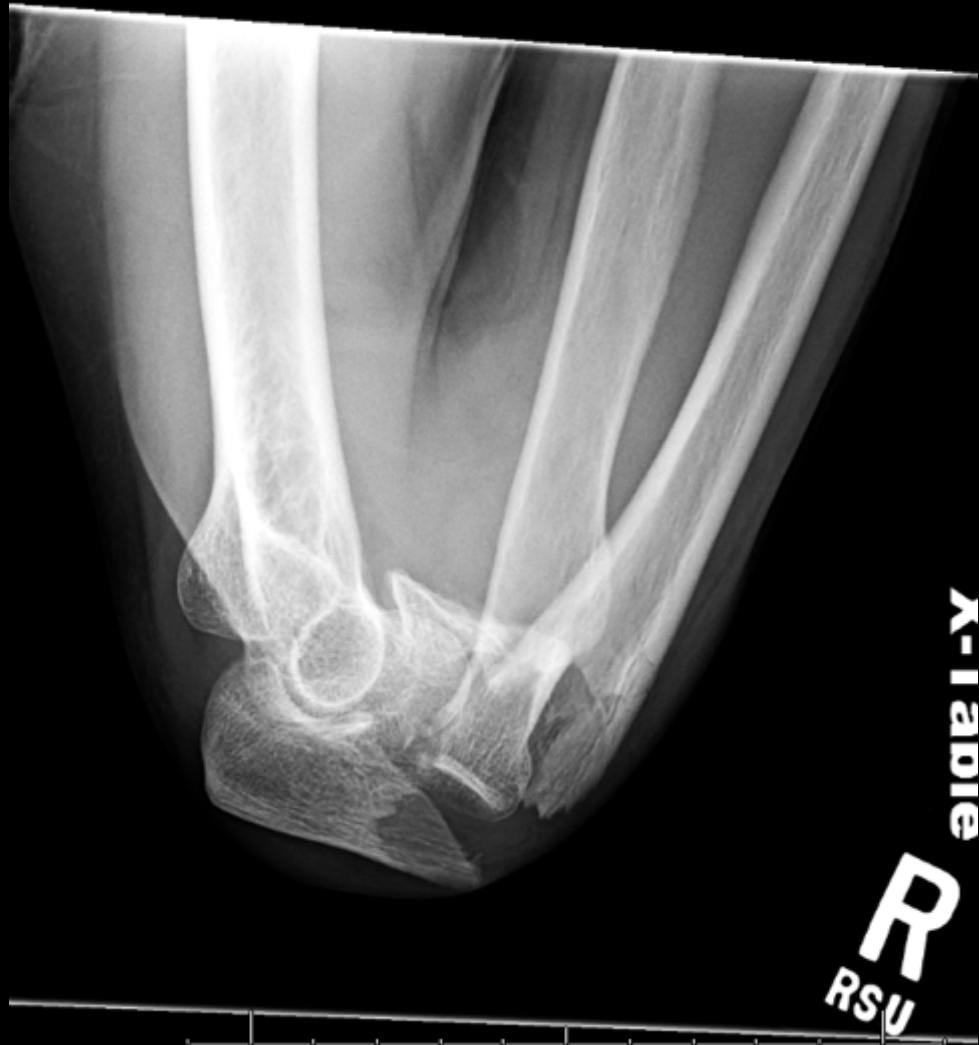


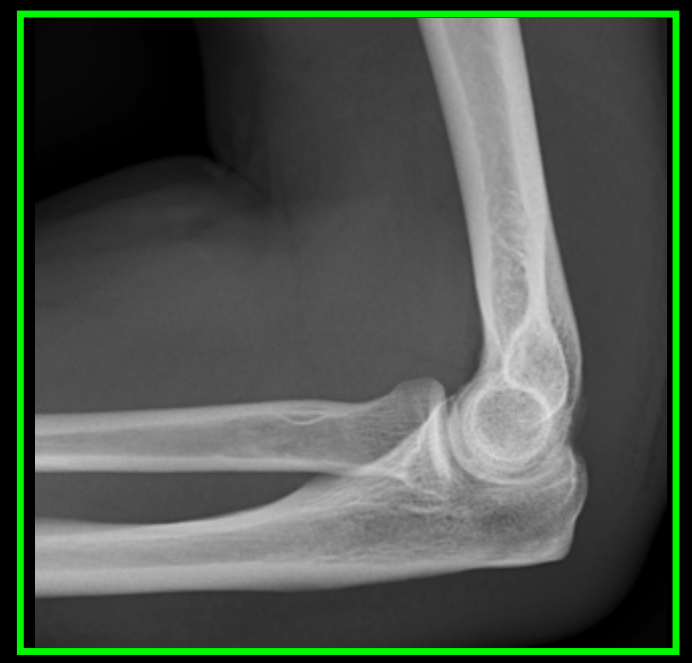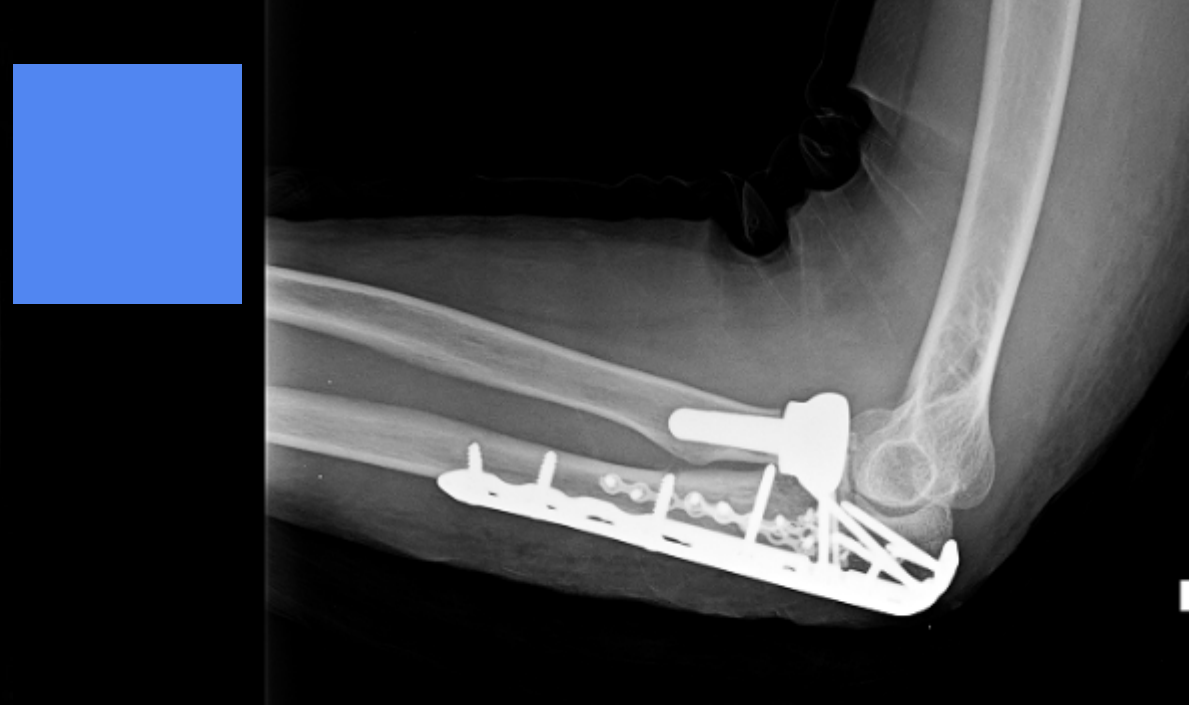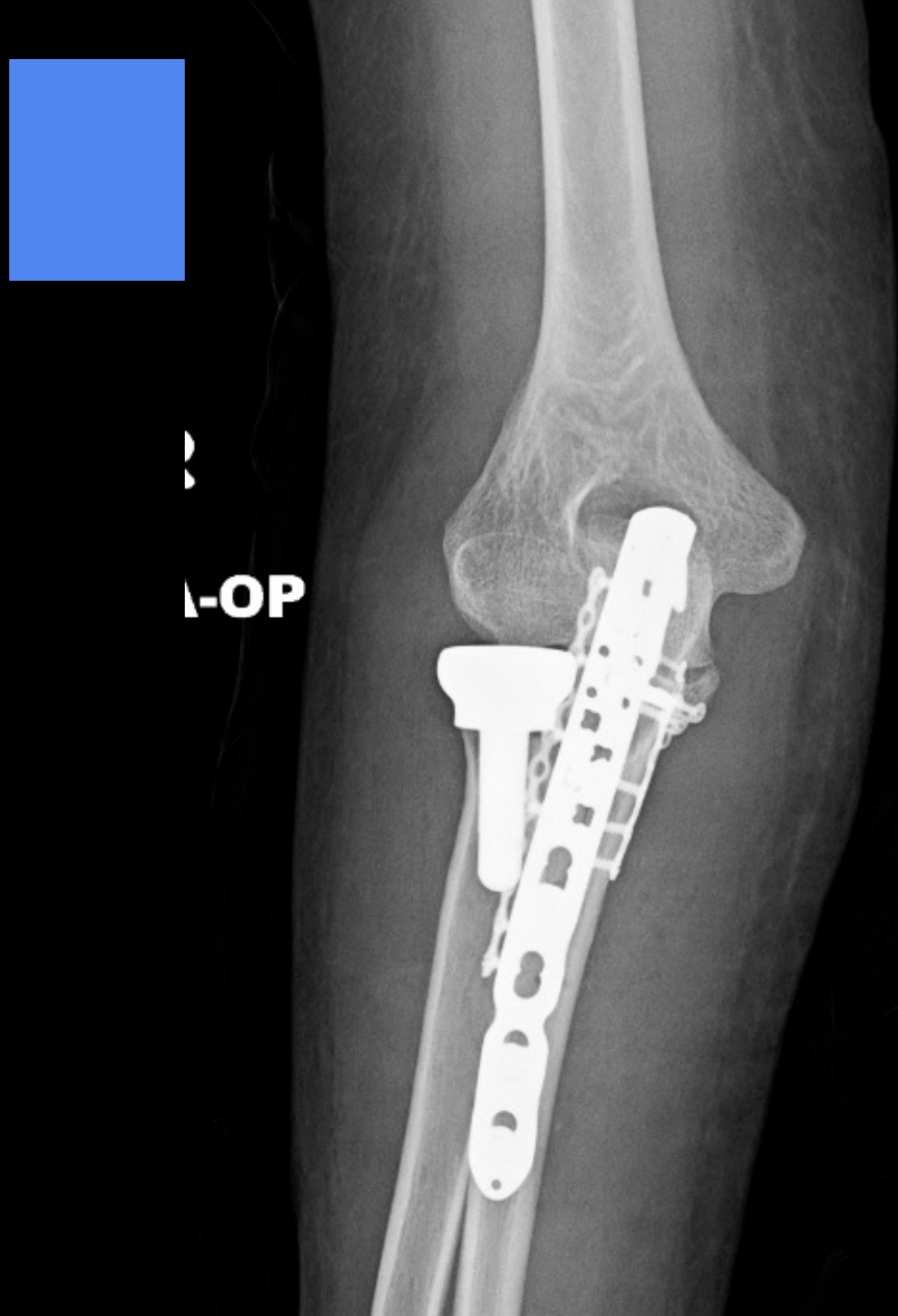# Olecranon escape



57 y/o, female. s/p fall, h/o UE  
nerve/tendon surgeries

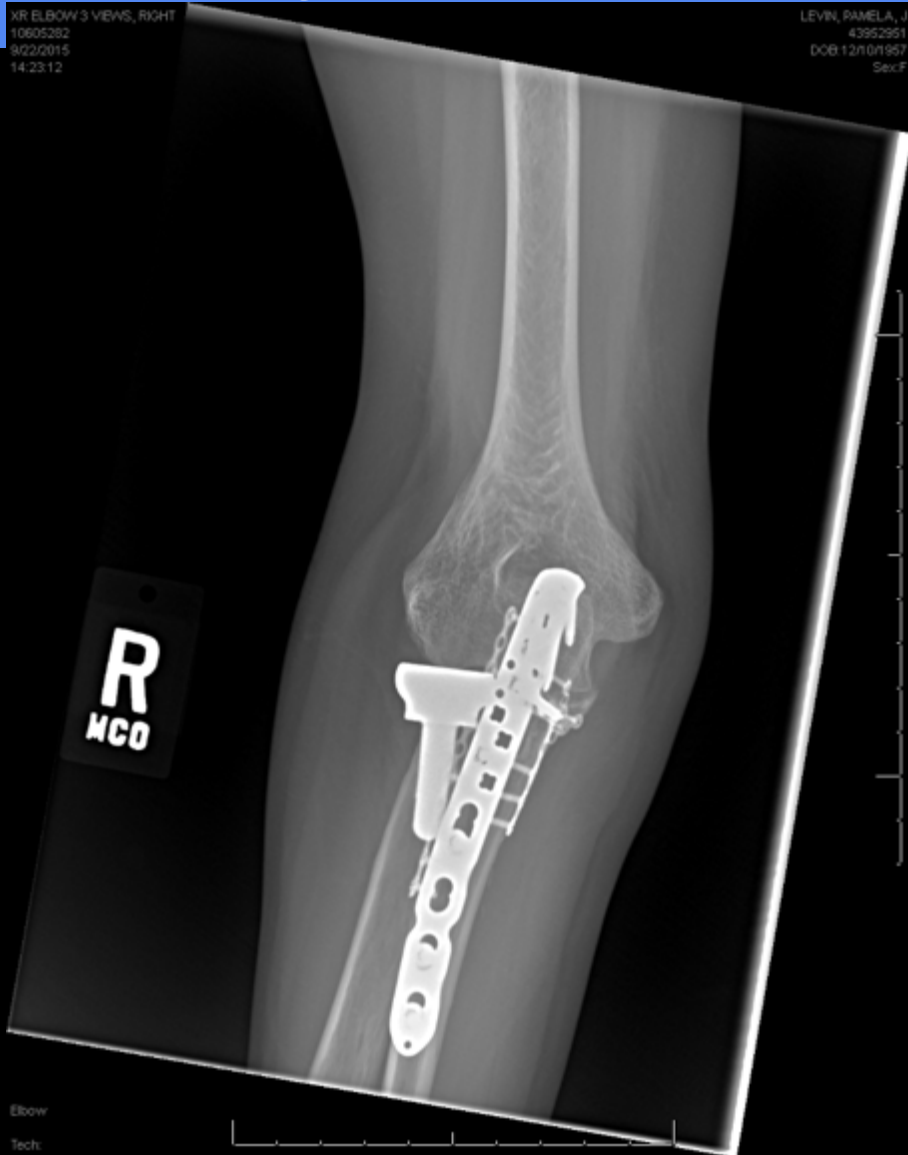



# 1 yr f/u

XR ELBOW 3 VIEWS, RIGHT  
10605282  
9/22/2015  
14:23:12

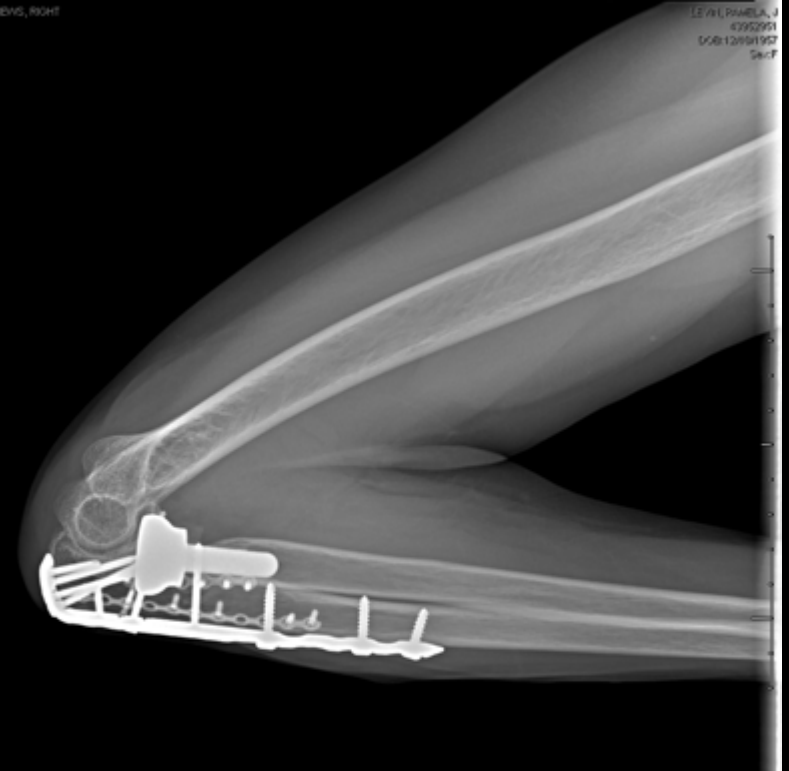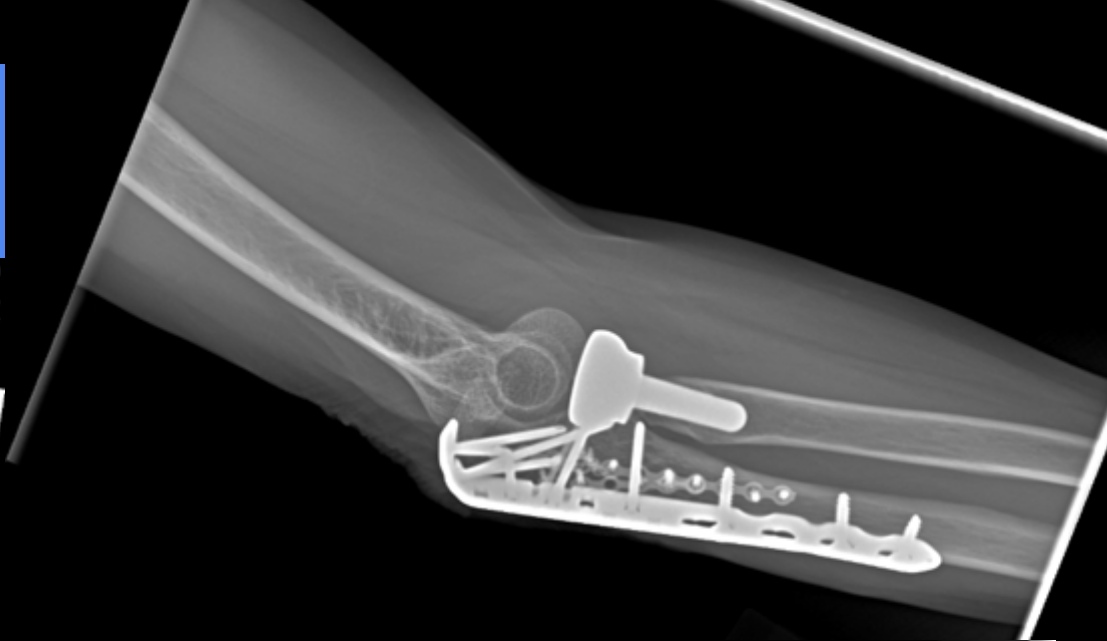LEVIN, PAMELA, J  
43952951  
DOB: 12/01/1957  
Sex: F



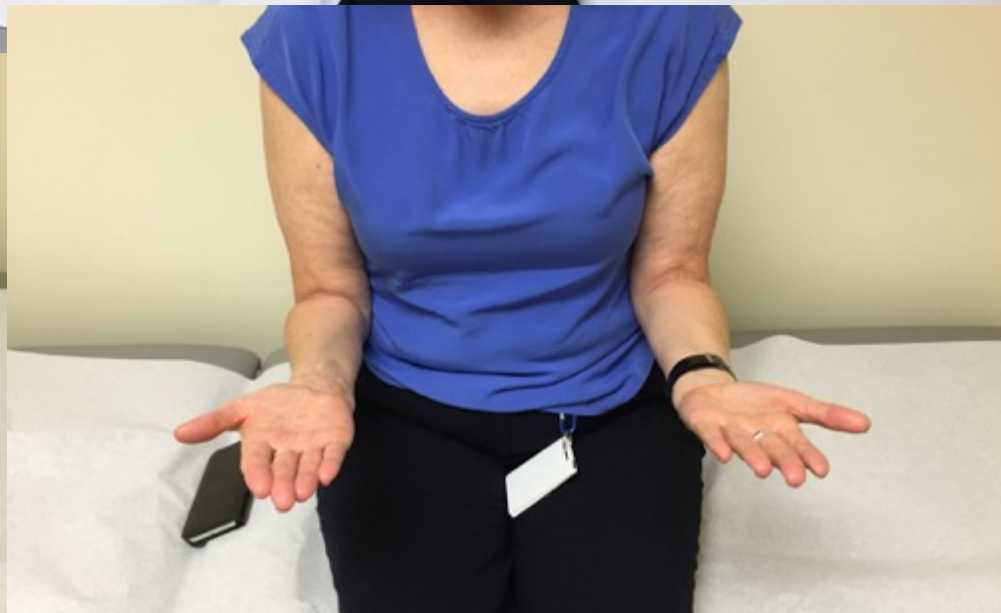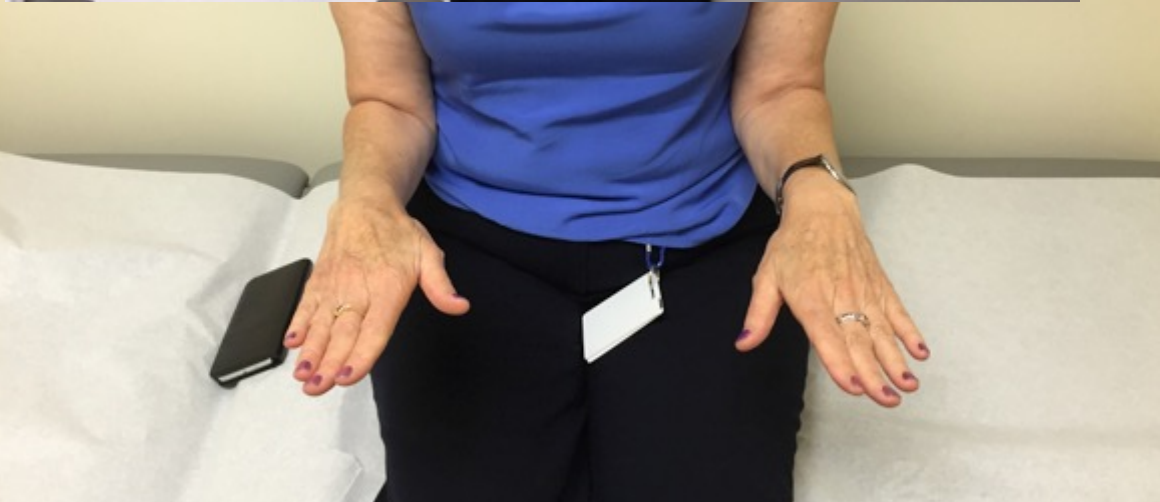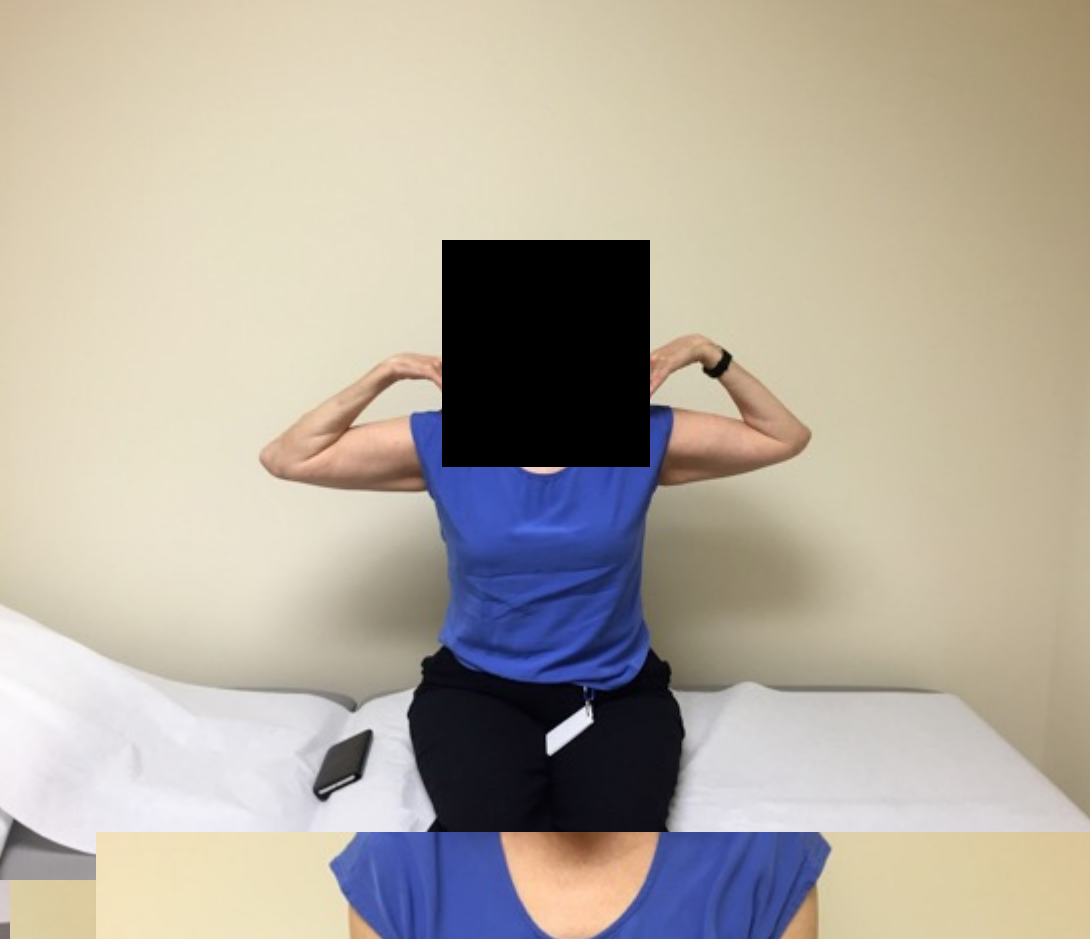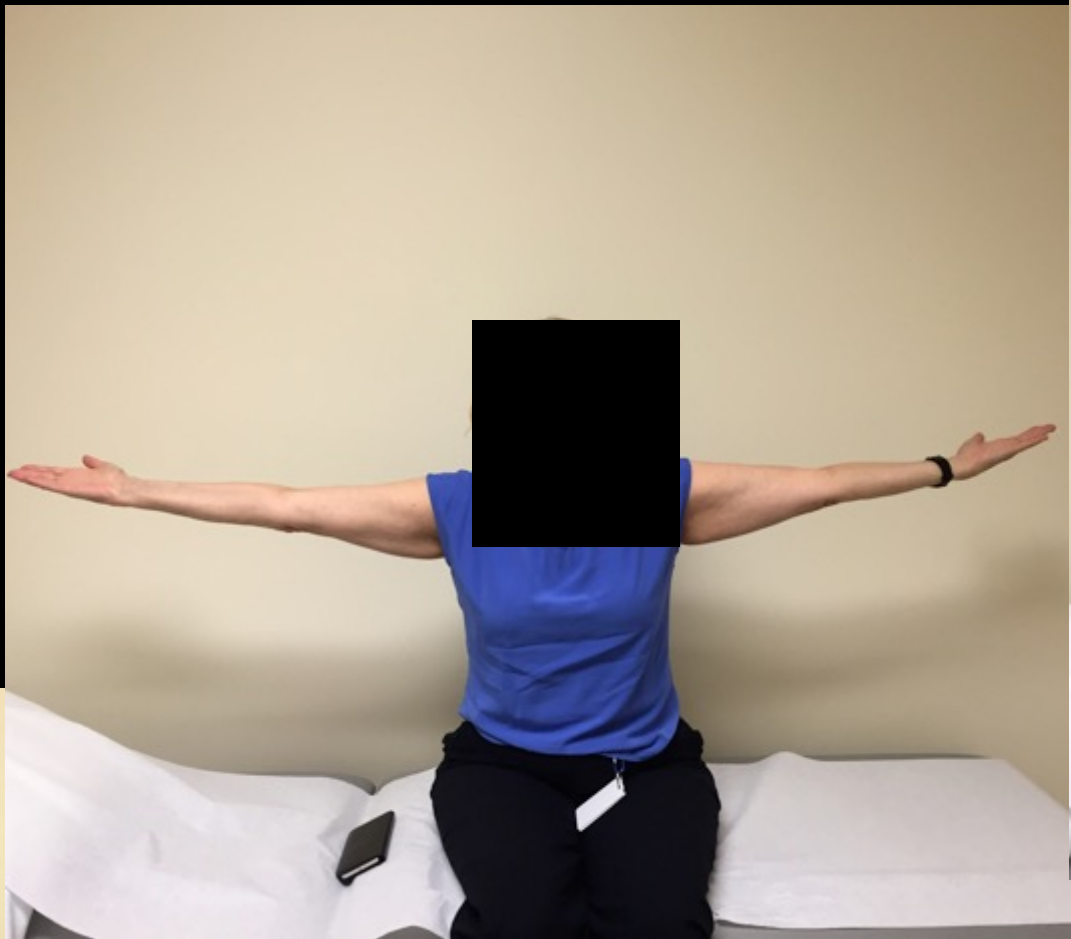XR ELBOW 3 VIEWS, RIGHT  
10605282  
9/22/2015  
14:22:46

XR ELBOW 3 VIEWS, RIGHT  
10605282  
9/22/2015  
14:21:45

LEVIN, PAMELA, J  
43952951  
DOB: 12/01/1957  
Sex: F

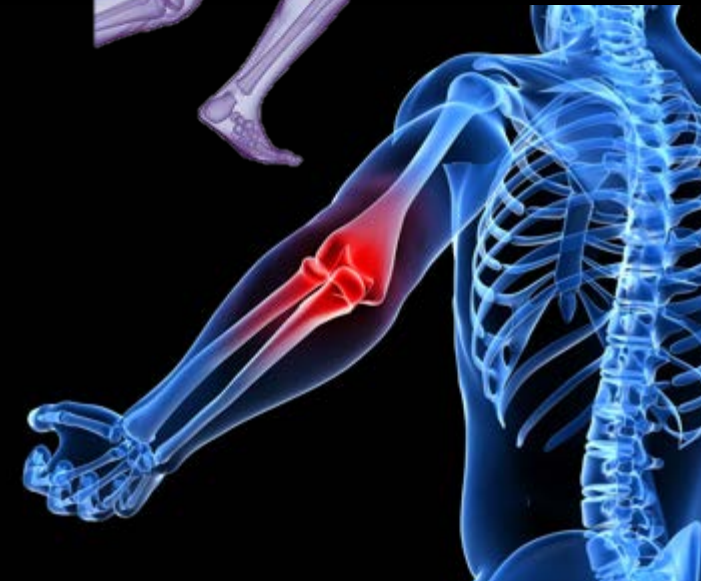
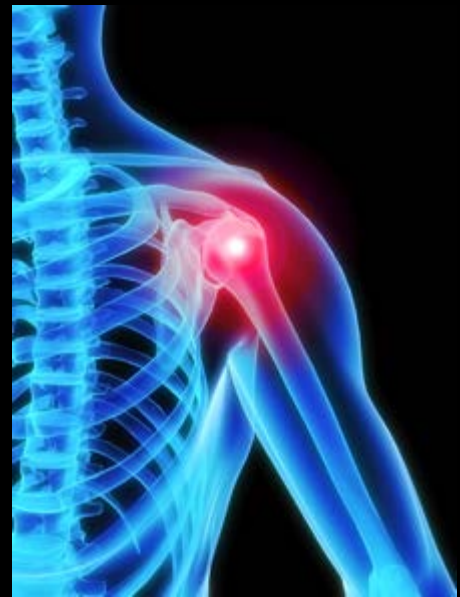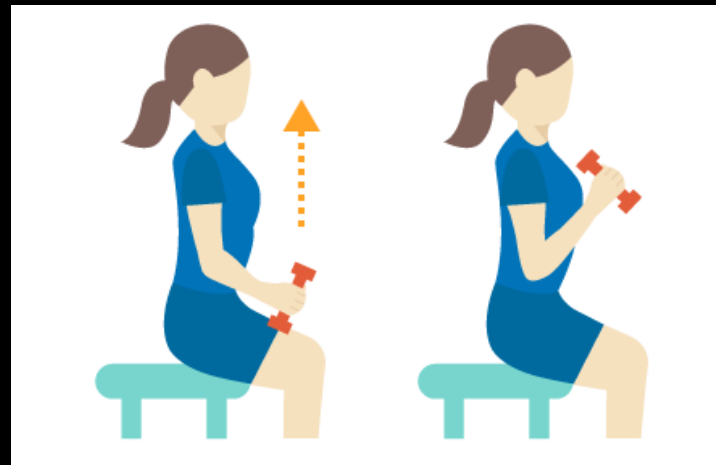

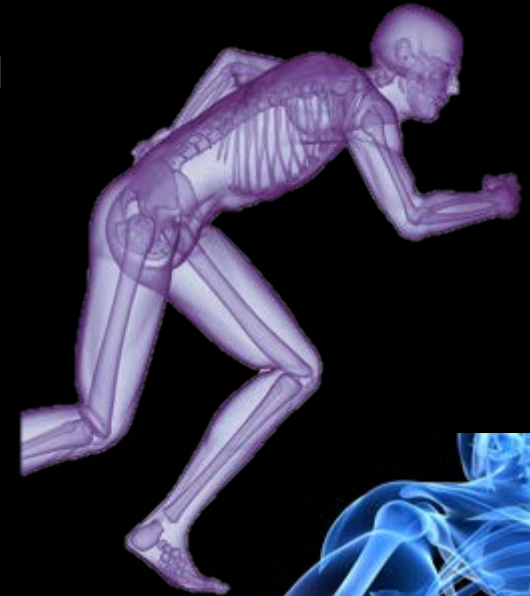
Elbow  
Tech:



# Summary

- Goal : Return to prior functional level
- ROM is critical: Life = Motion
- 50/50 rule:



# THANK YOU



[Utku.Kandemir@ucsf.edu](mailto:Utku.Kandemir@ucsf.edu)

