

# Spine Imaging and Pain Intervention

Cynthia T. Chin M.D.

UCSF  
Neuroradiology



D Shanahan New Yorker

UCSF University of California, San Francisco

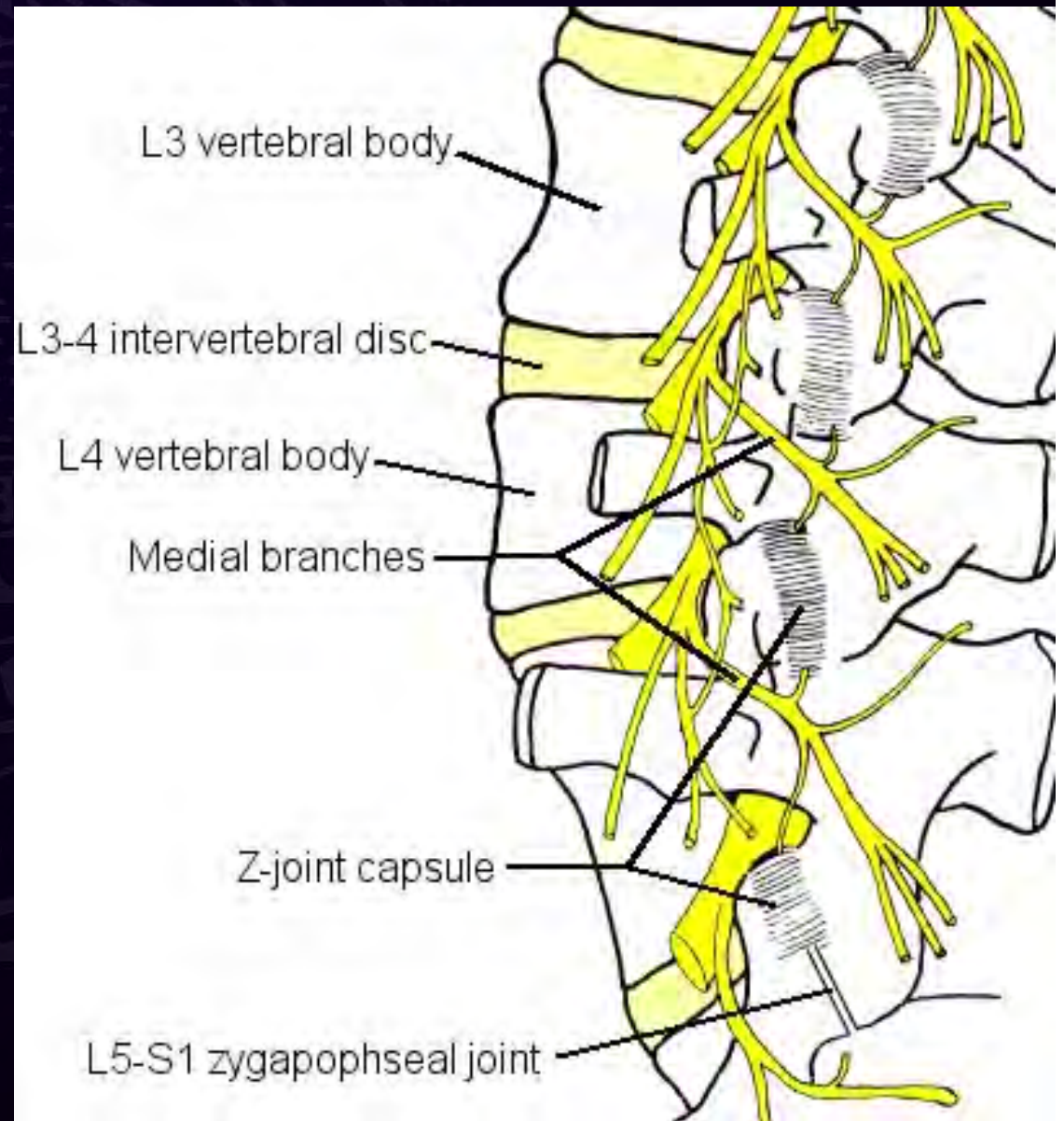
# Spine

## Musculoskeletal

- vertebral body
- discs
- foramina
- facets
- ligament

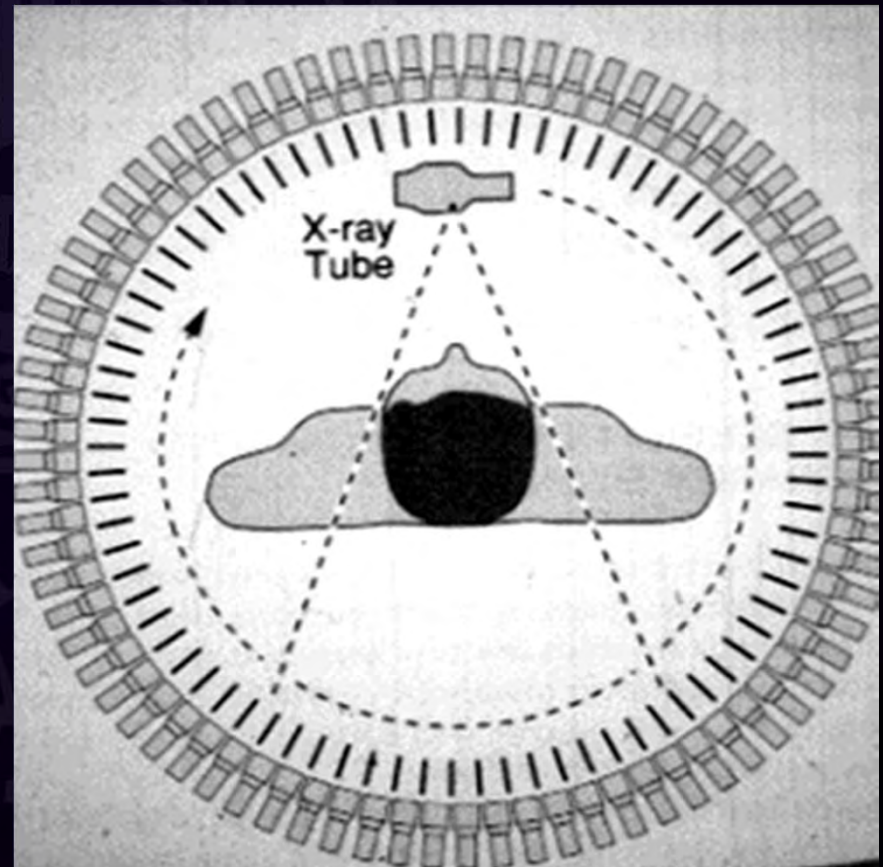
## Nervous System

- spinal cord
- spinal roots
- caudal brainstem
- cerebellum



# Computed Tomography

- Godfrey Hounsfield  
1972
- English Musical  
Instruments - Beatles
- Collimated beam  
differentially absorbed
- Photons collected by  
CT detectors
- Differential  
intensity/gray scale



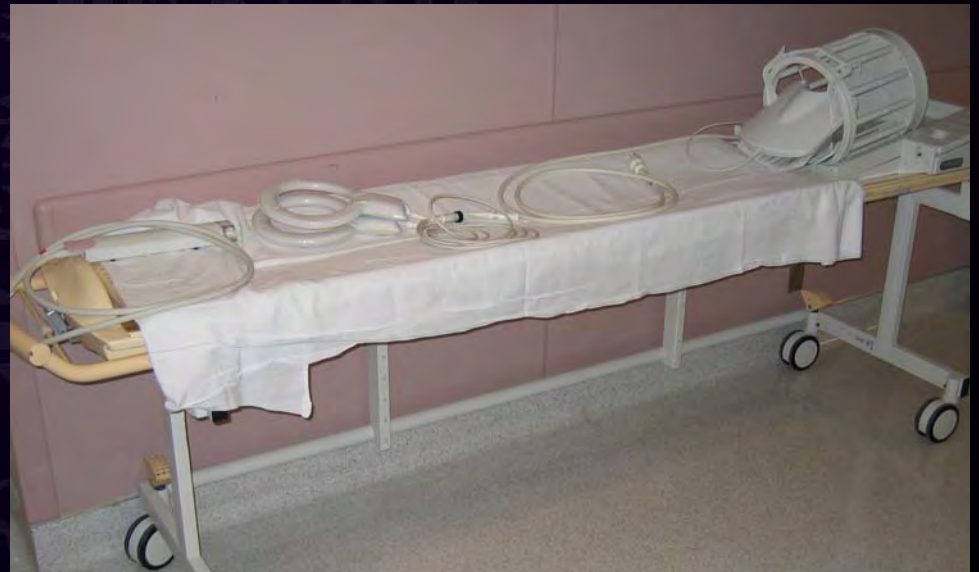# MRI

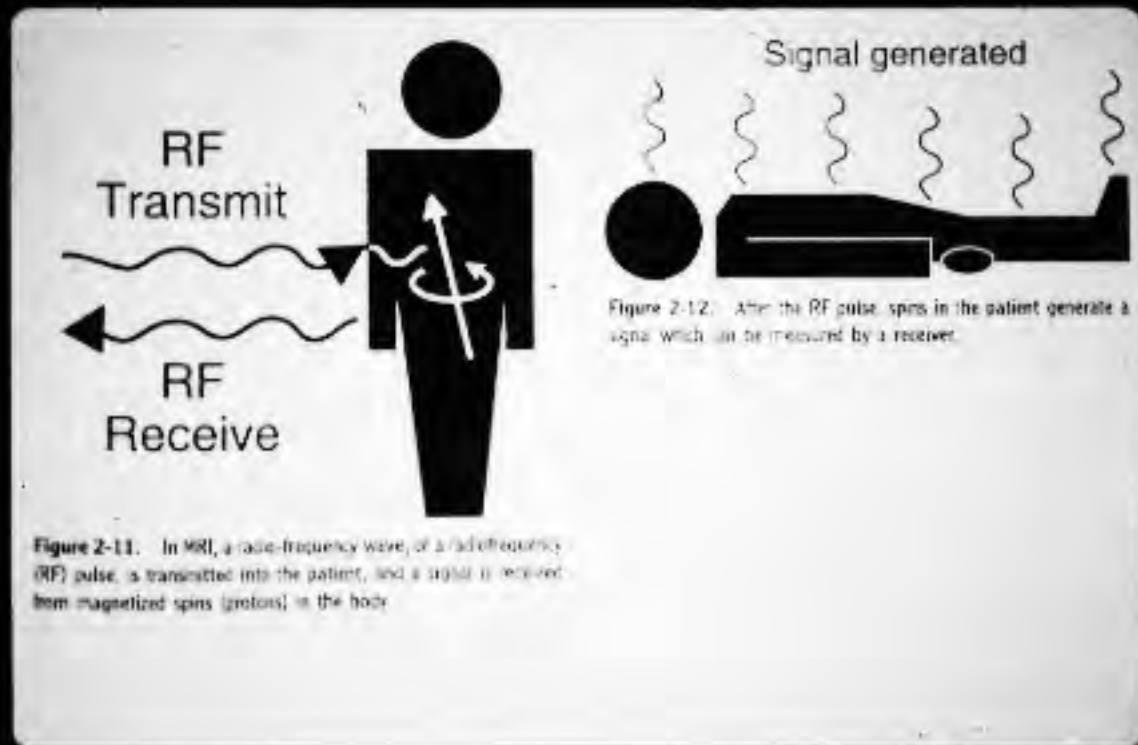
Coils: creates organized gradient of increasing magnetic field strength

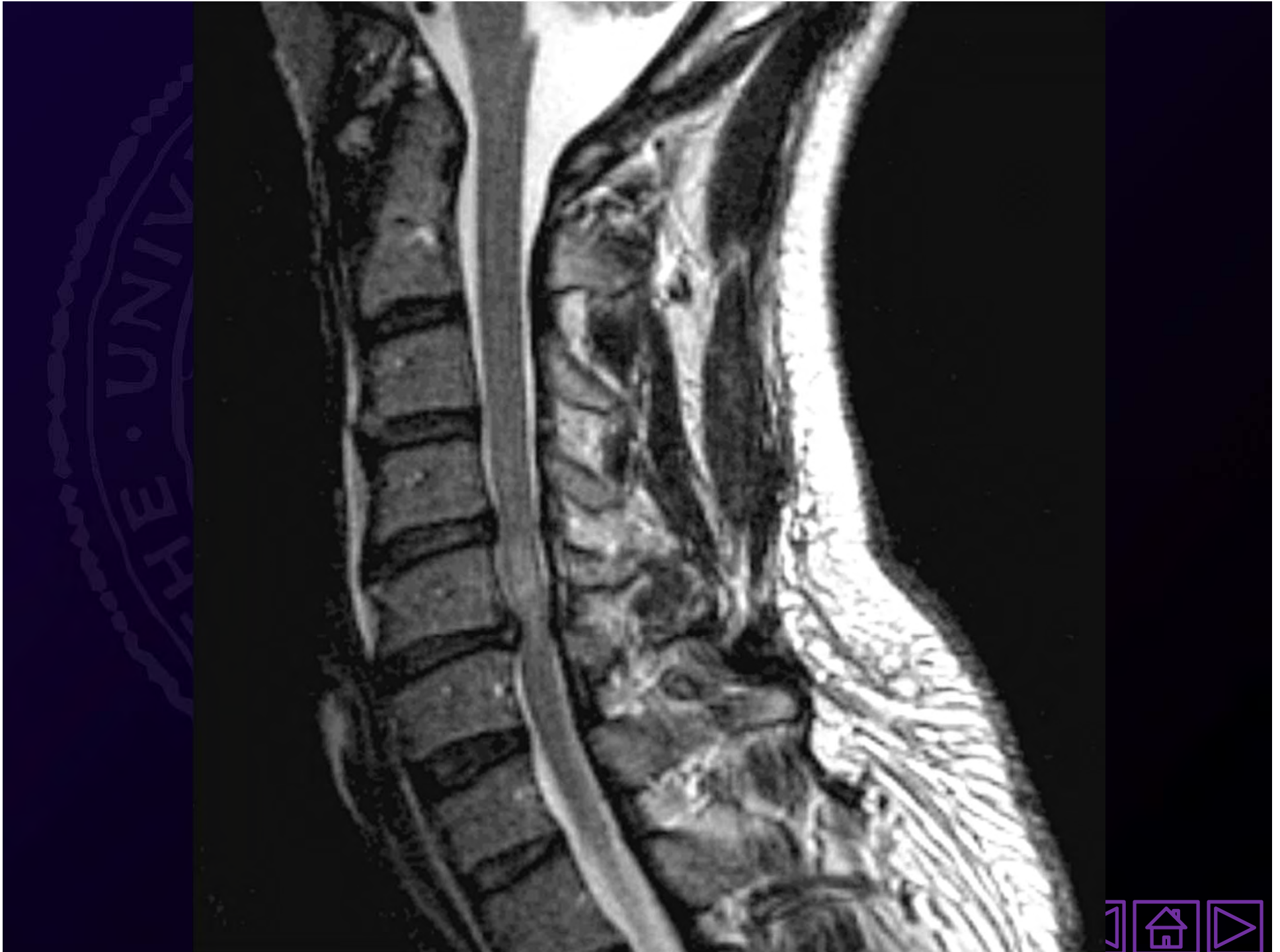
Tuning to a particular frequency localizes a point and judges amplitude of signal

Turning coils off and on = “jackhammer”

Coils also used to correct unwanted inhomogeneities

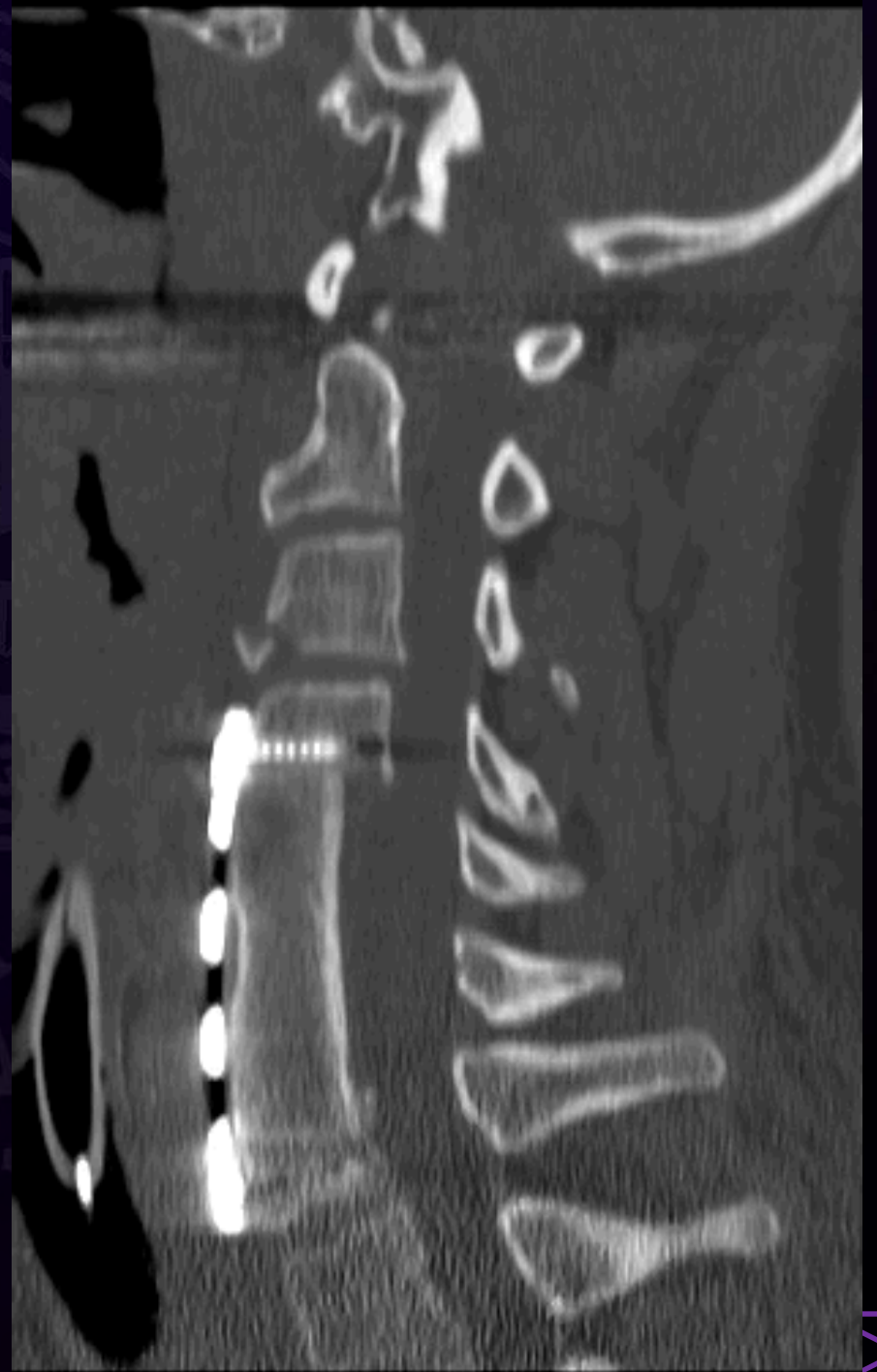
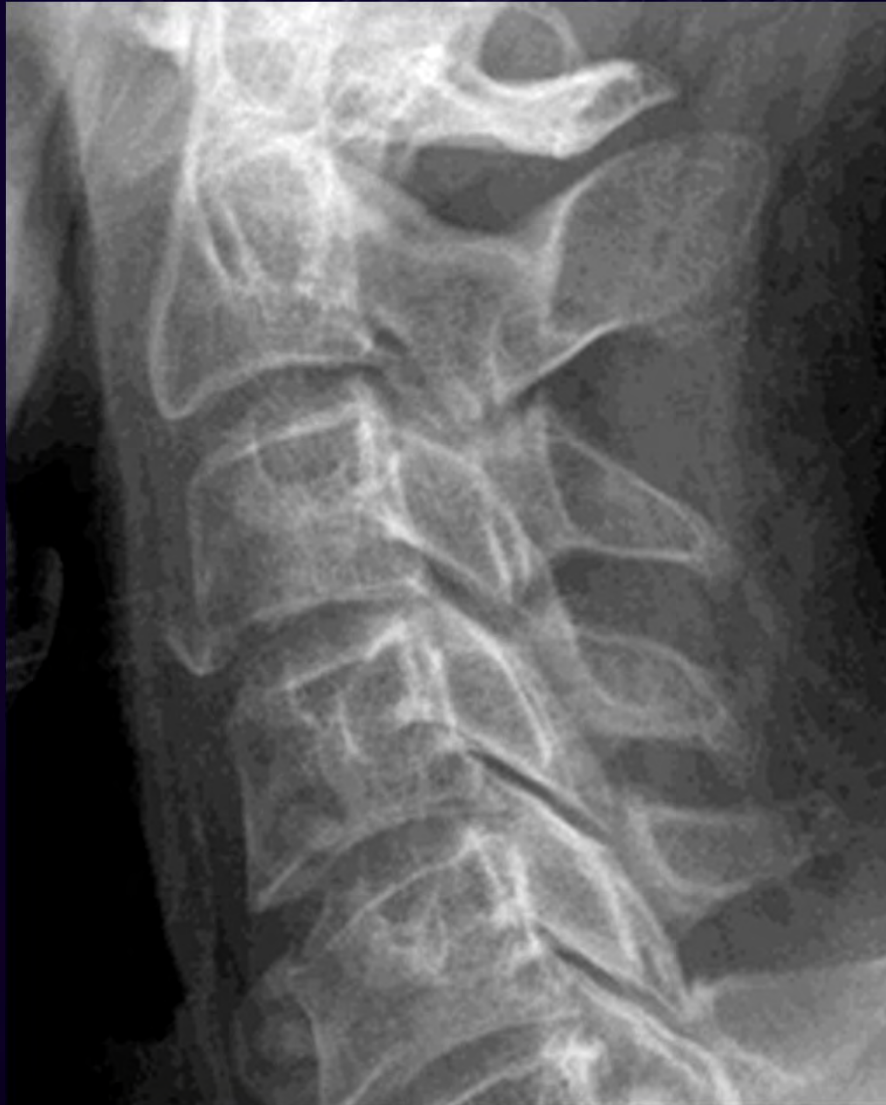
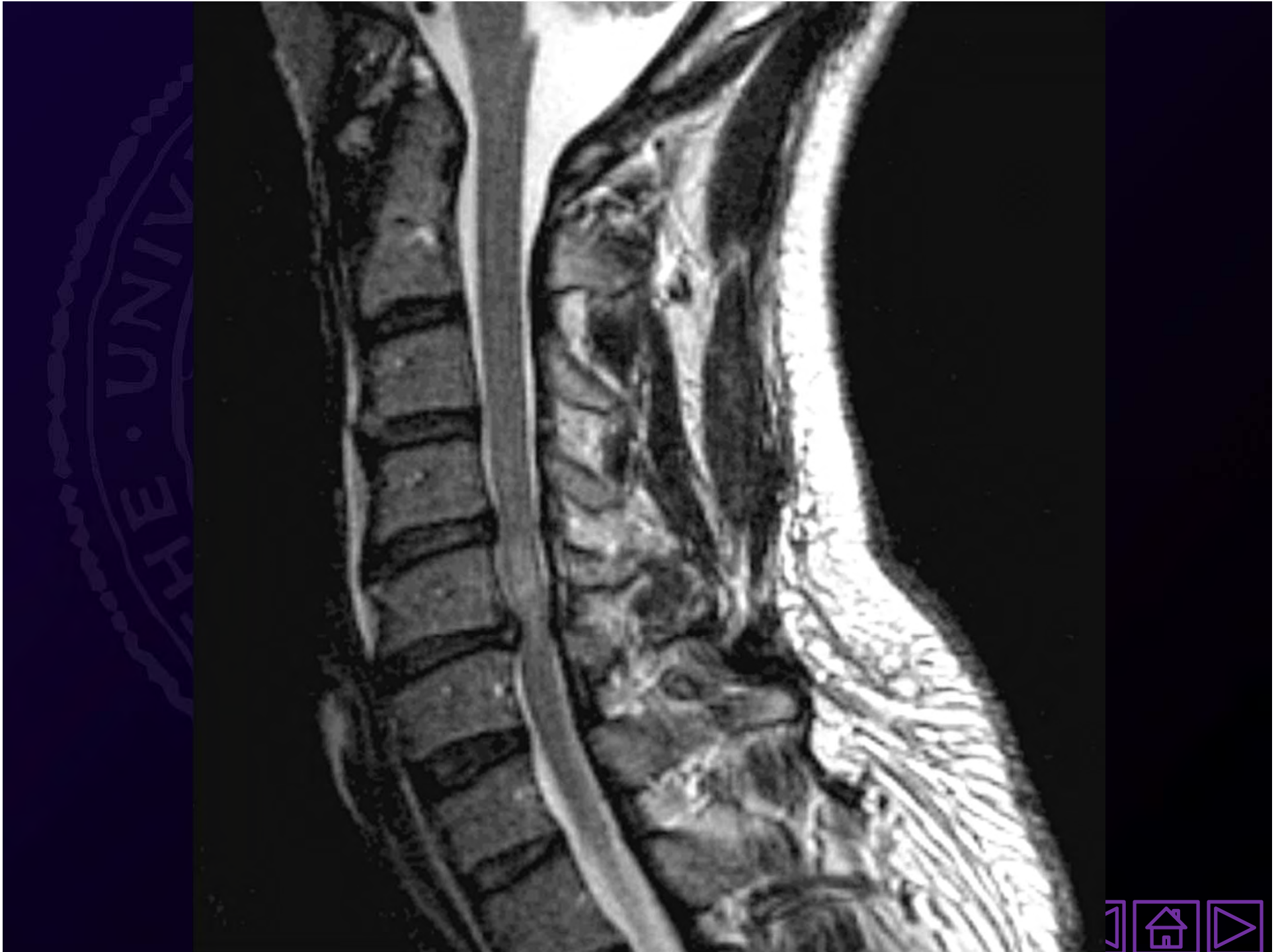




THE UNIVERSITY



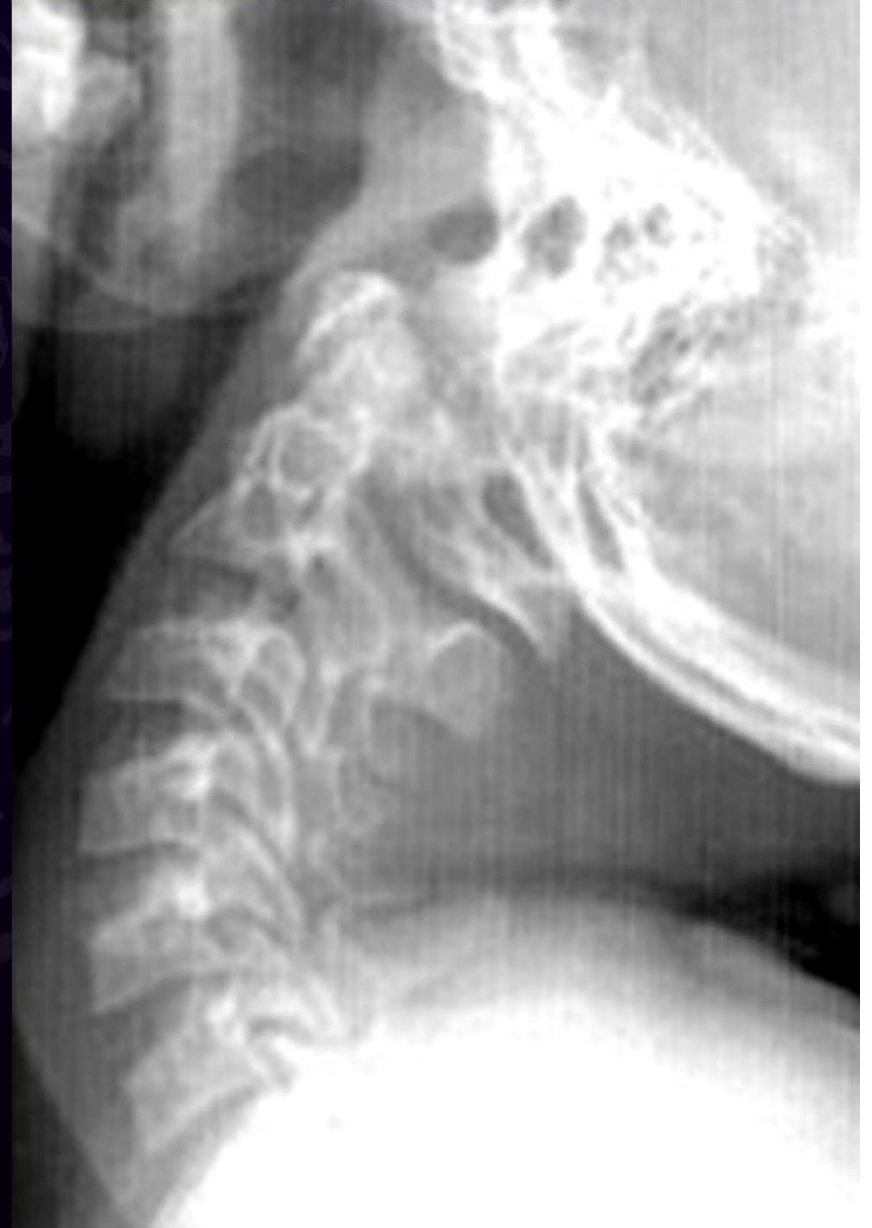
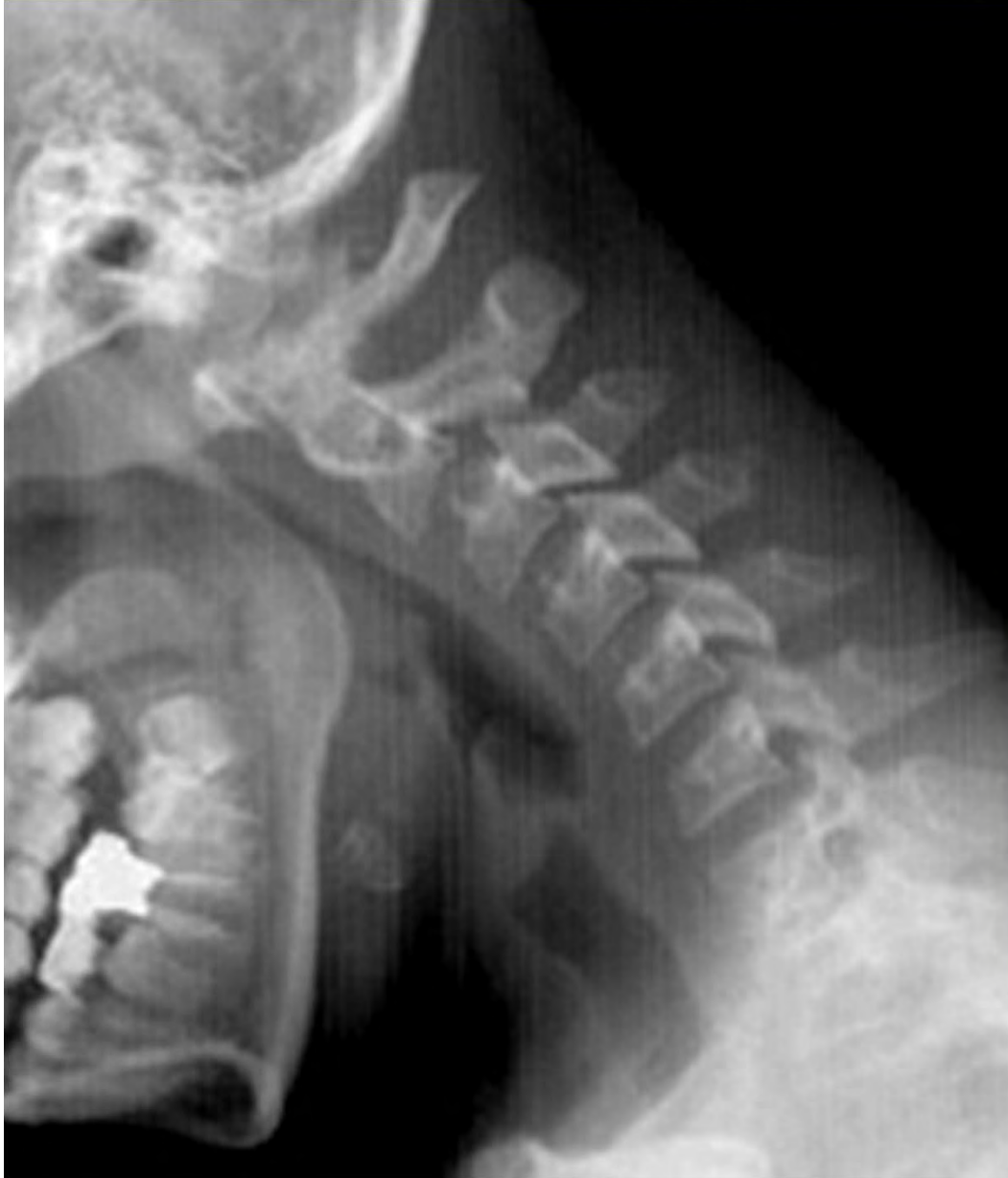


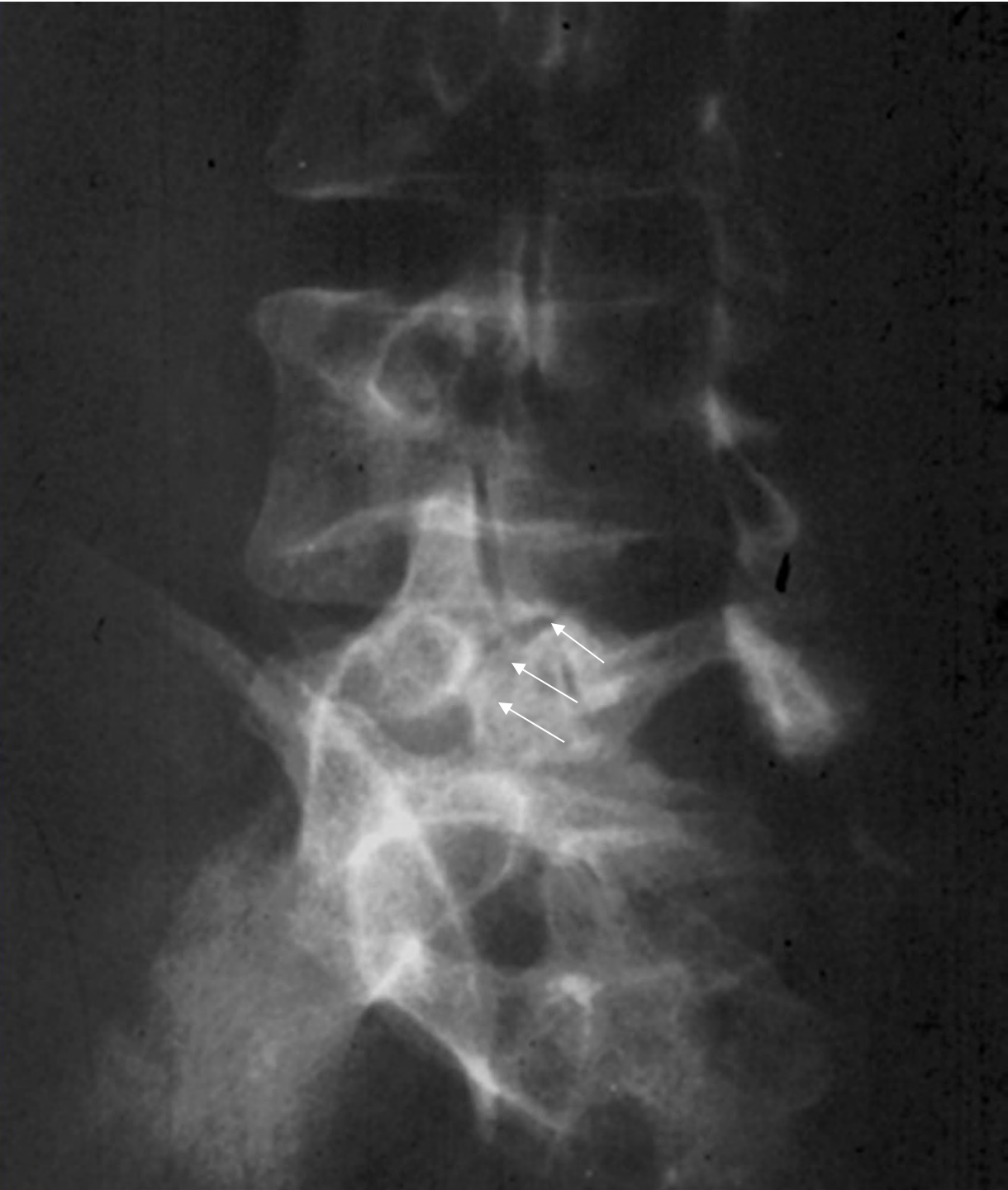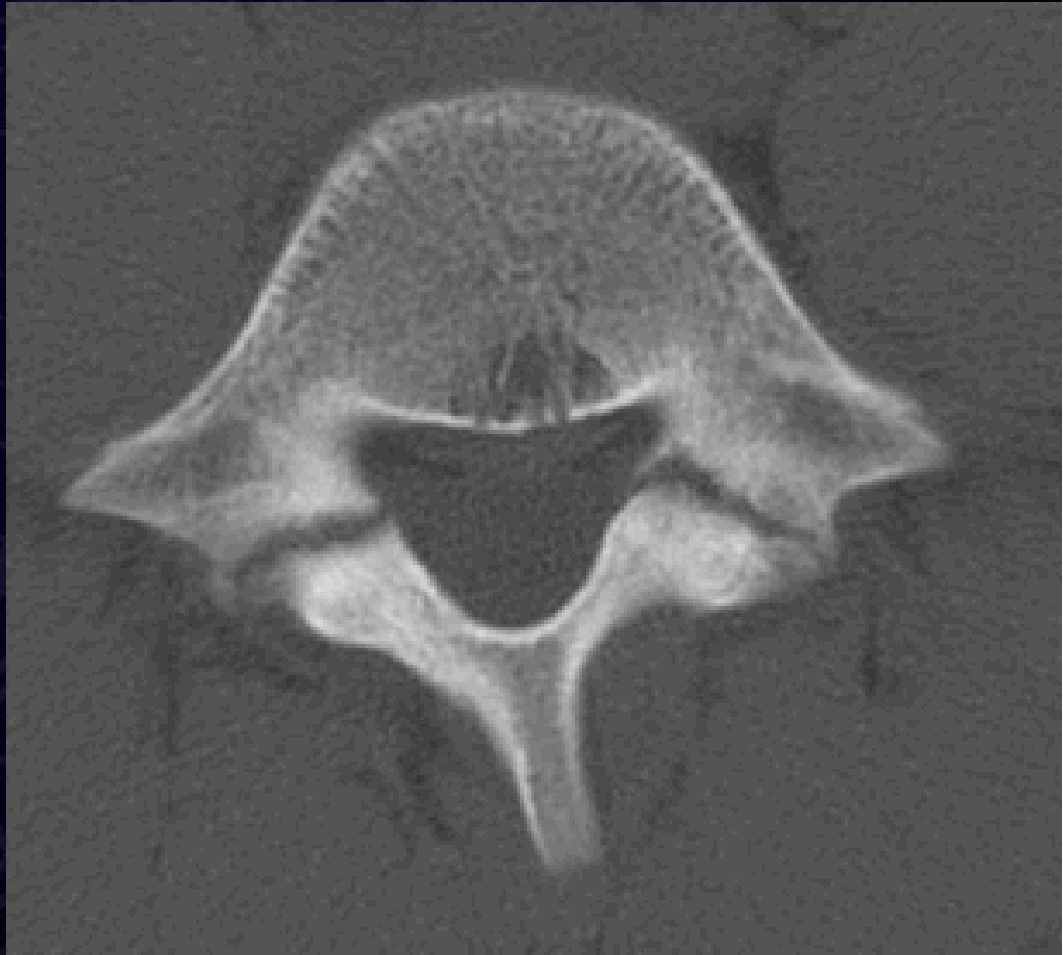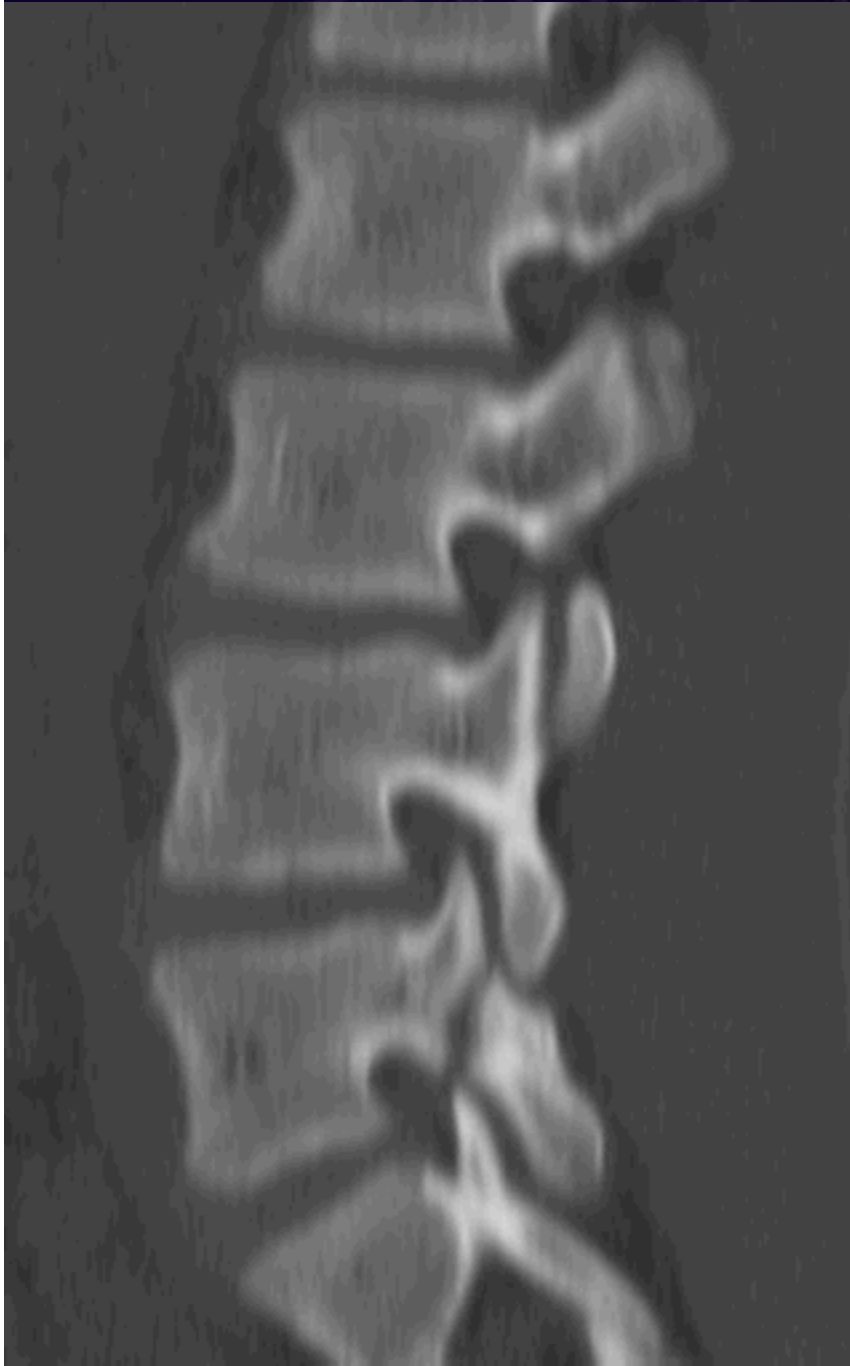THE UNIVERSITY

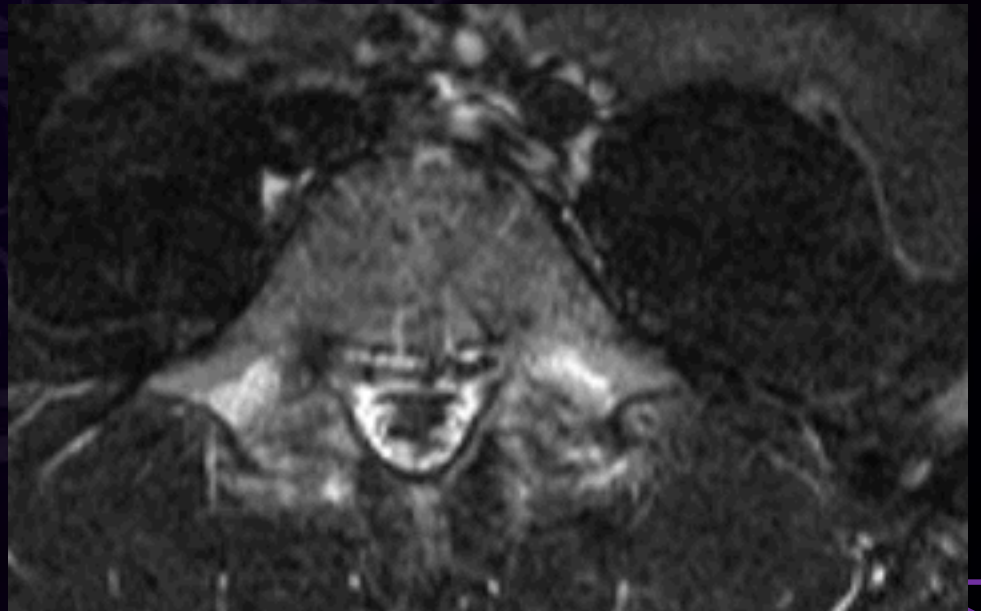
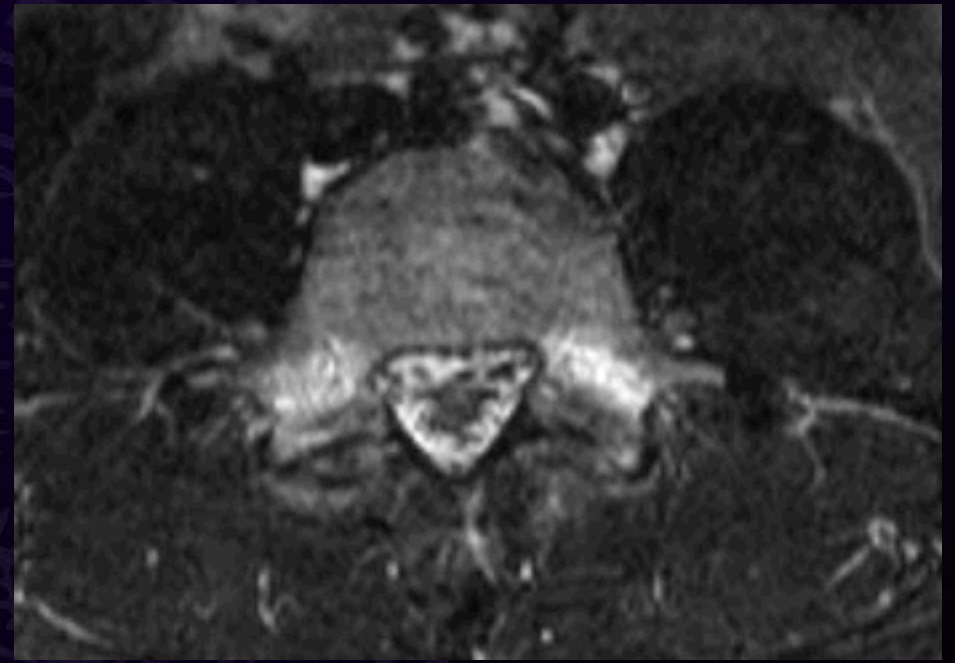
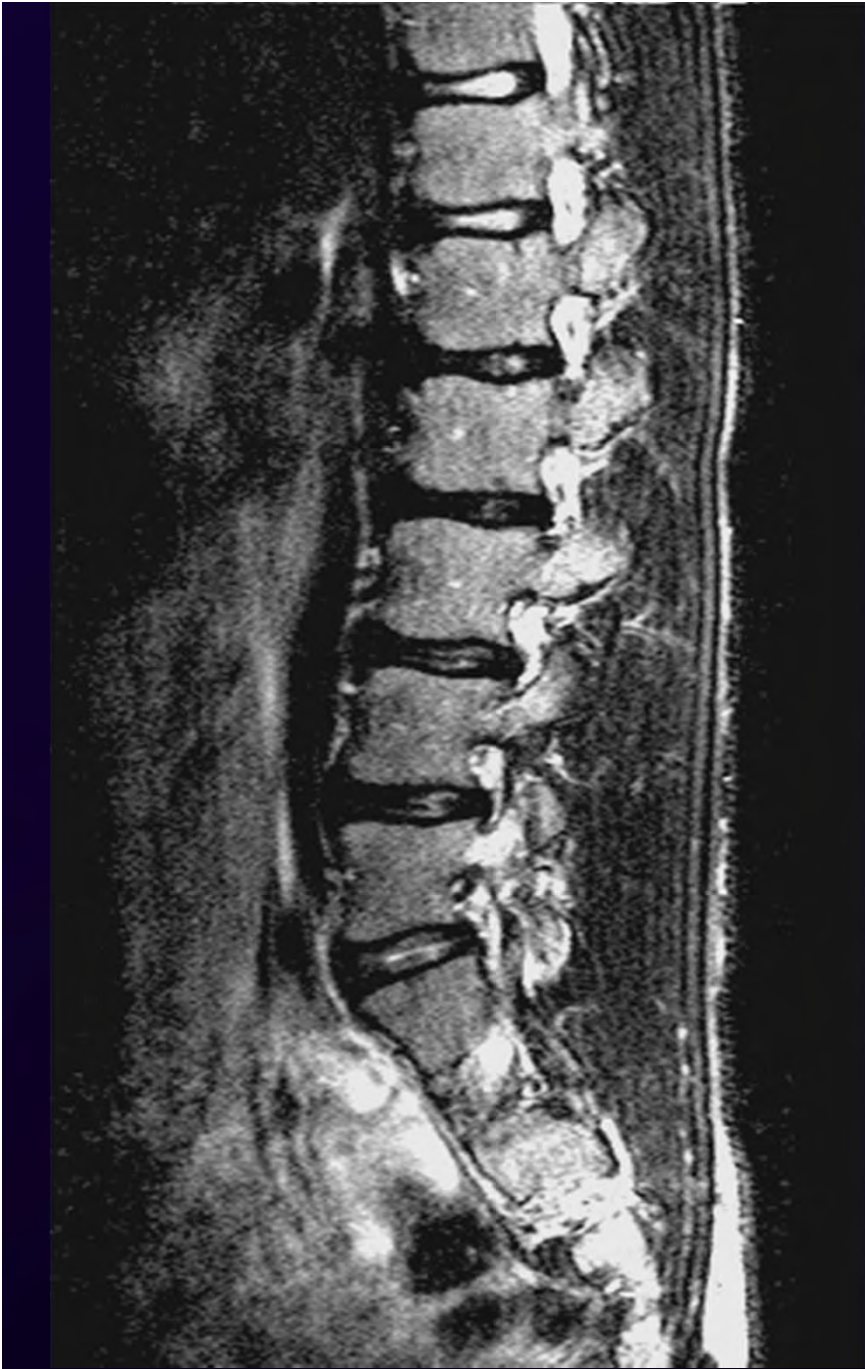

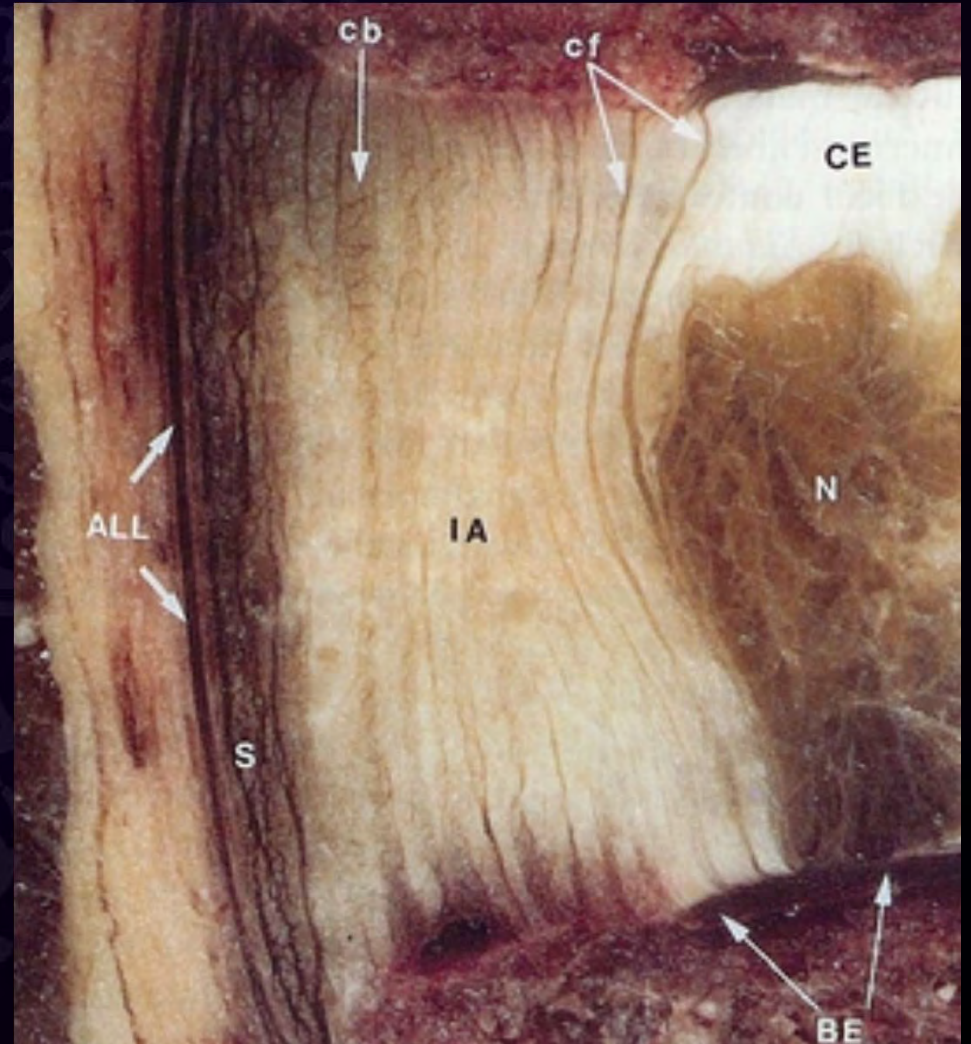
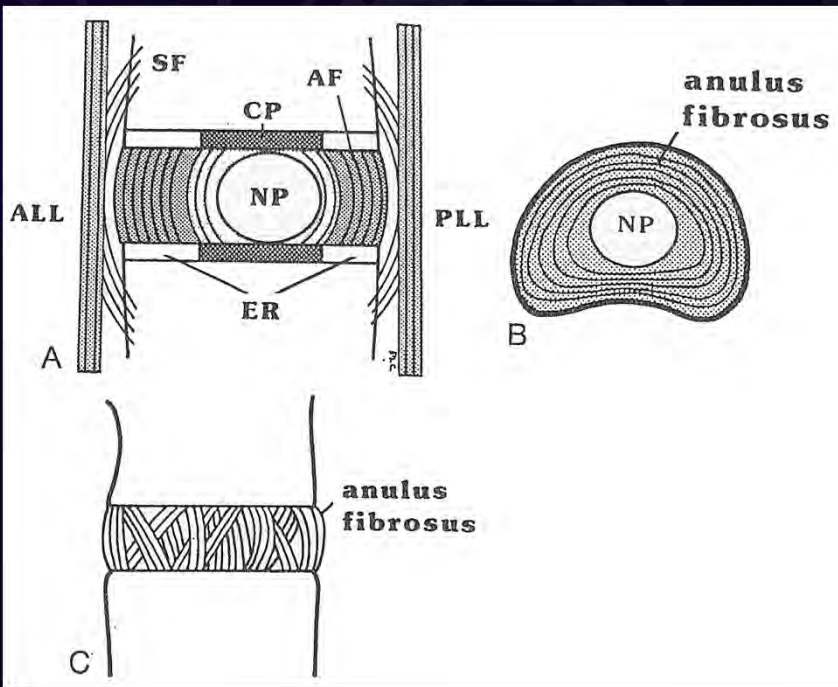
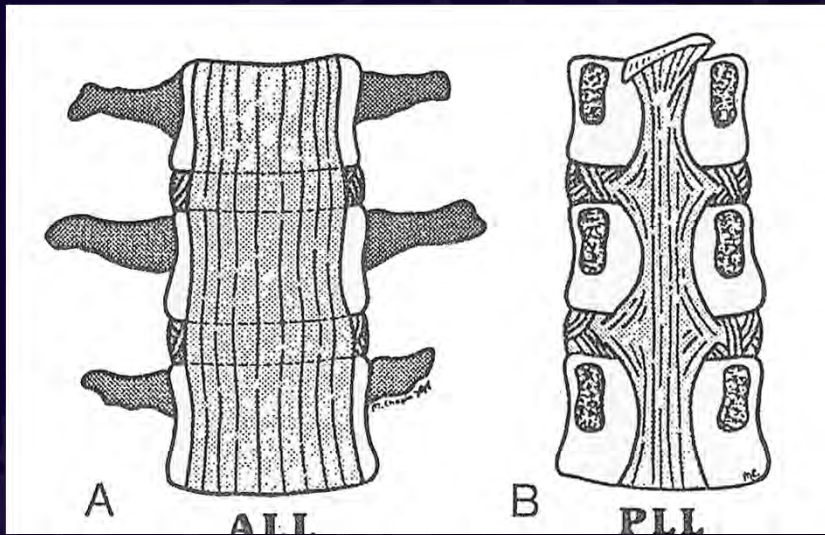



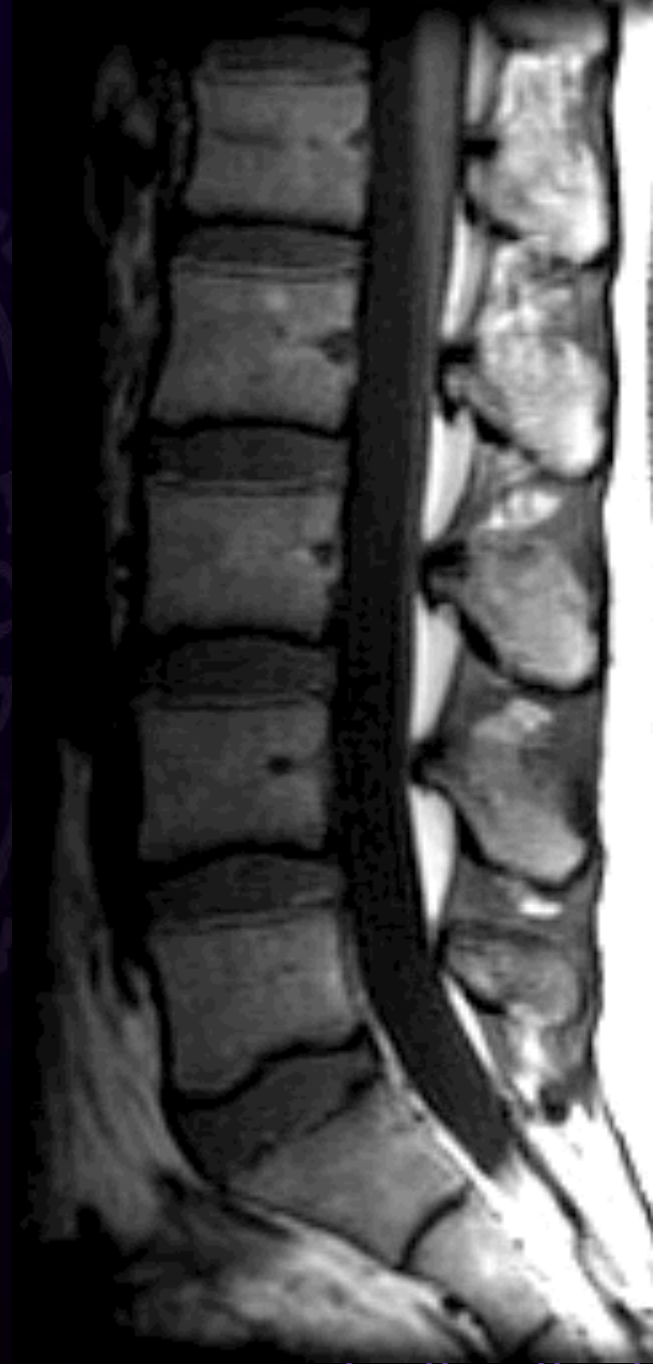
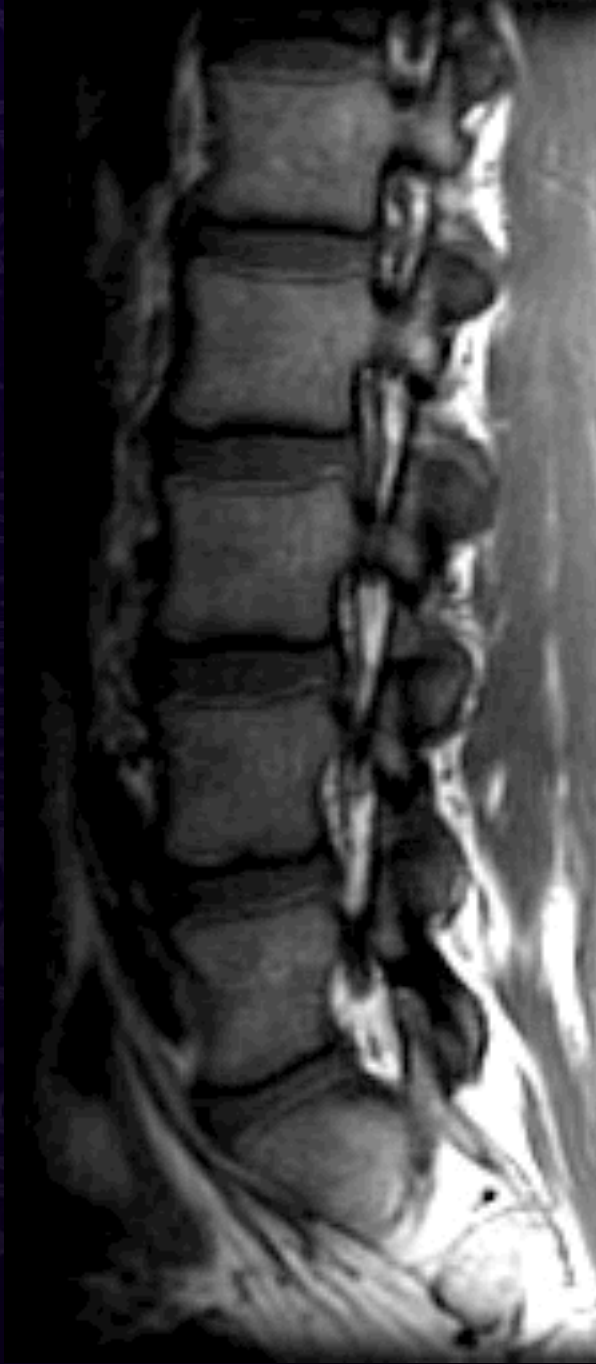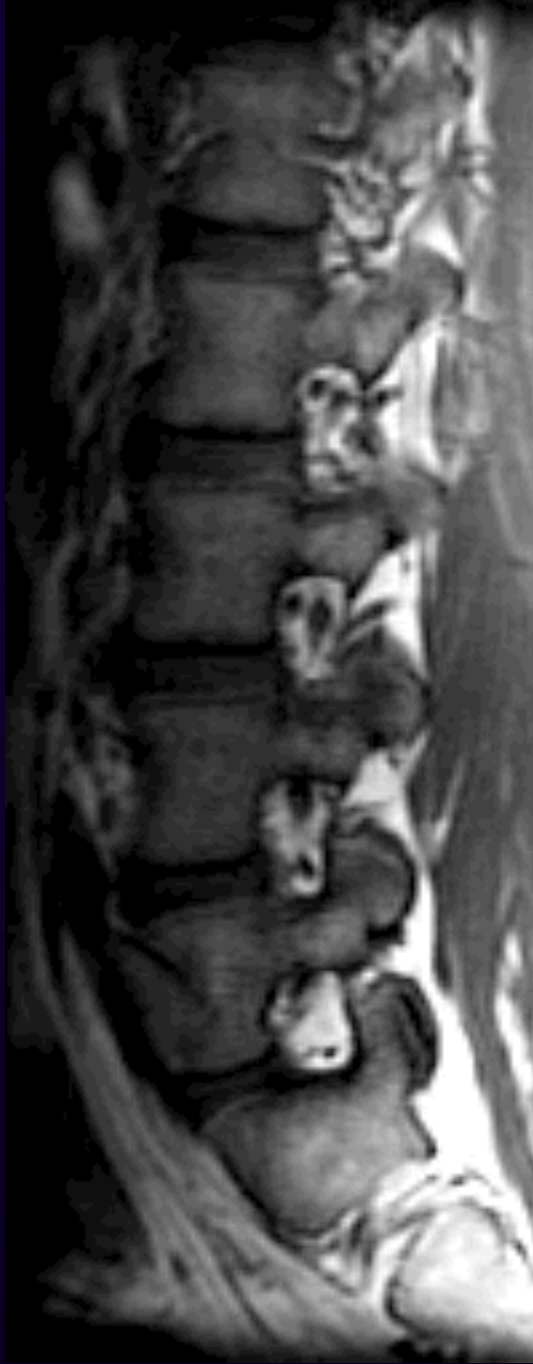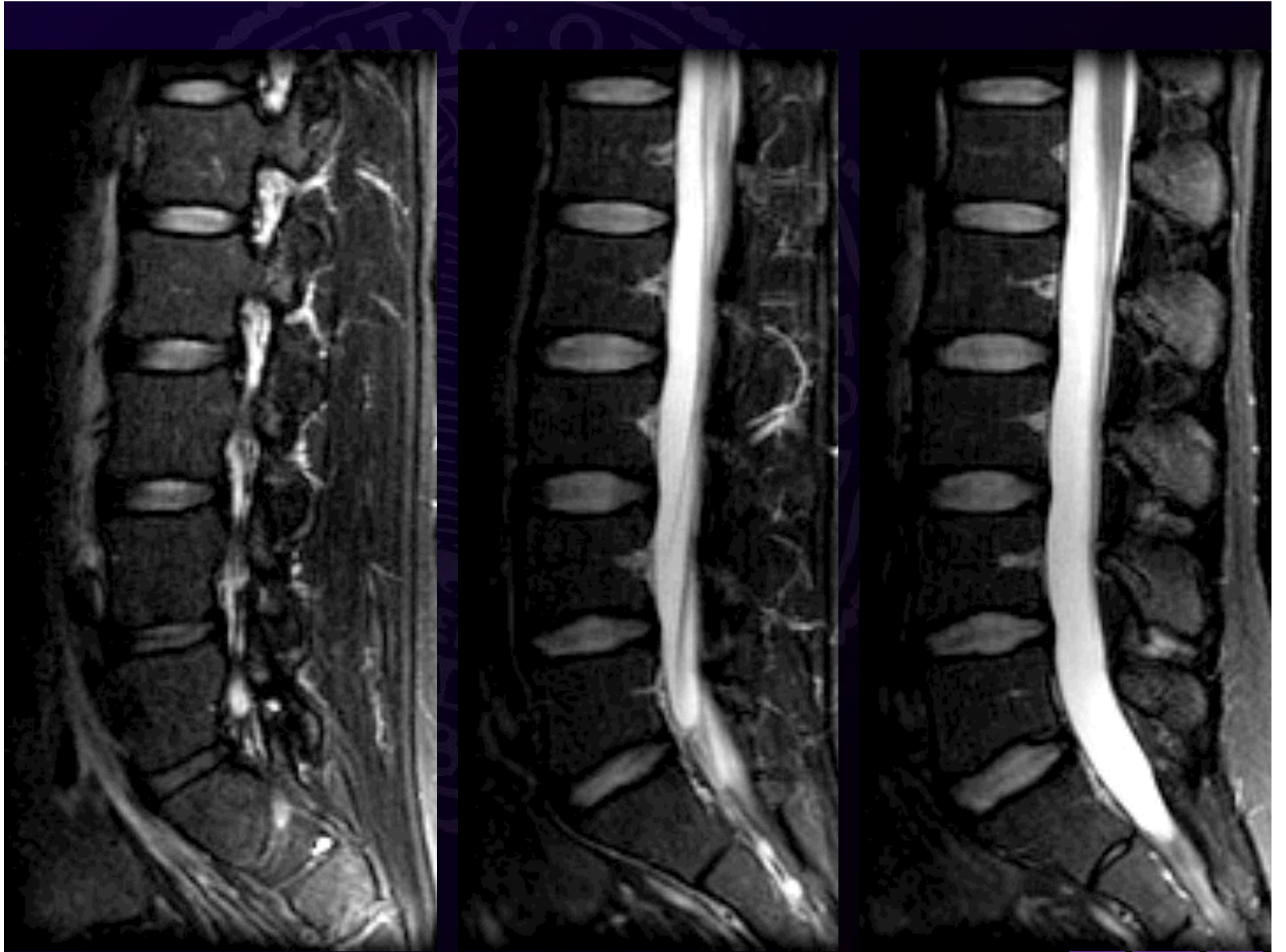


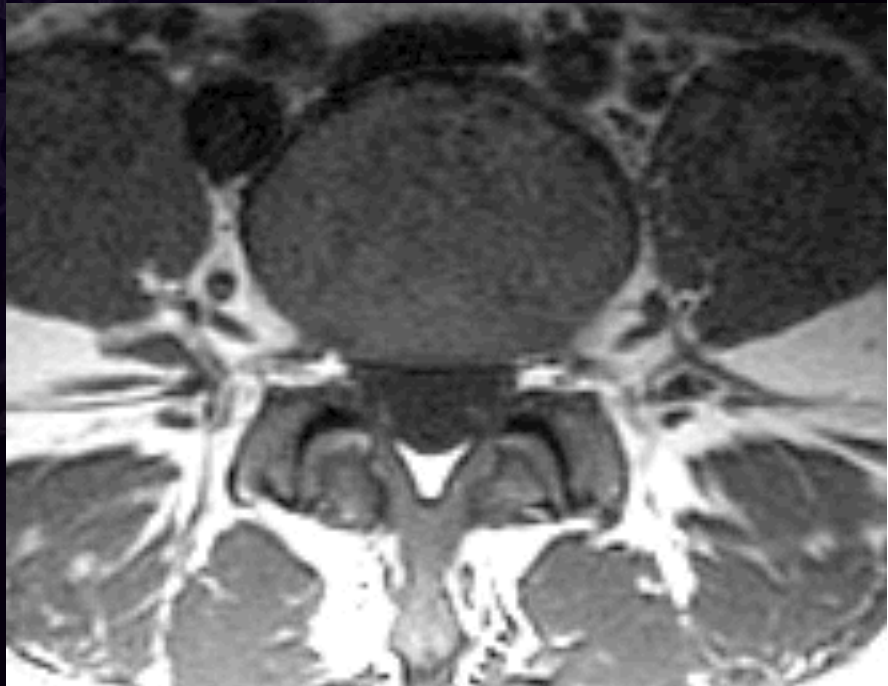
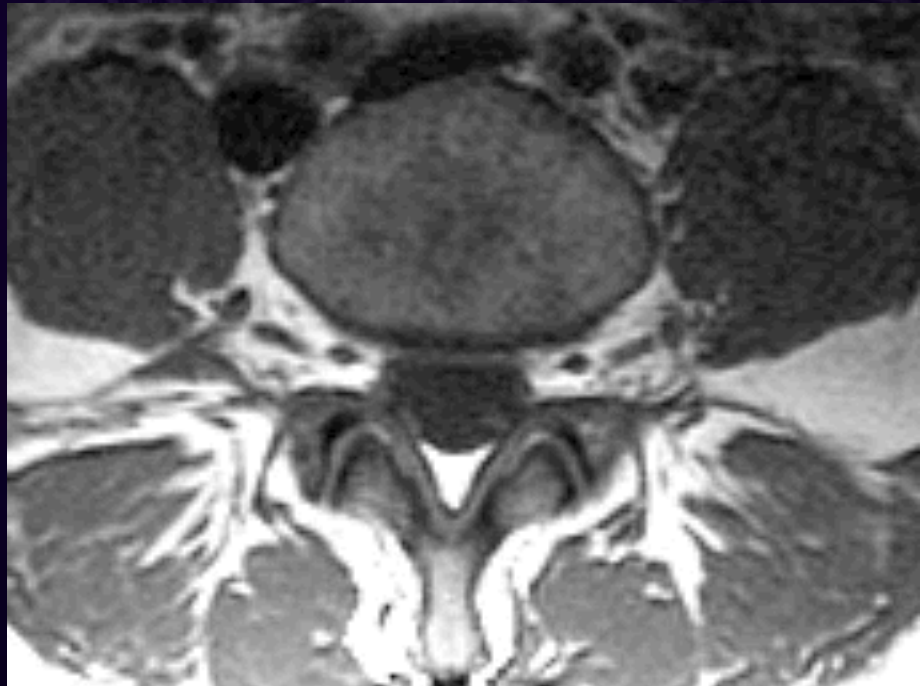
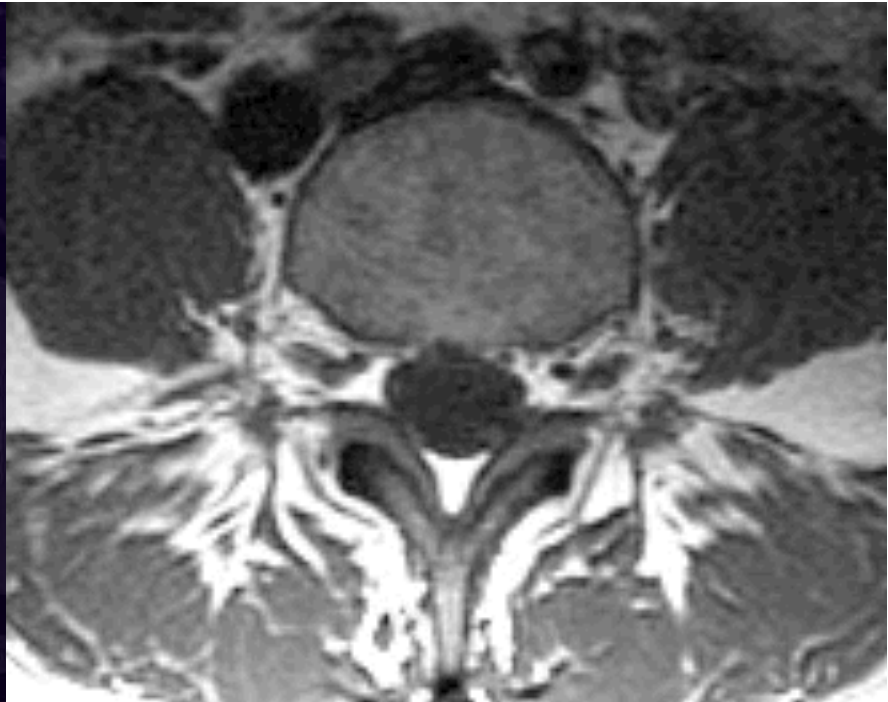
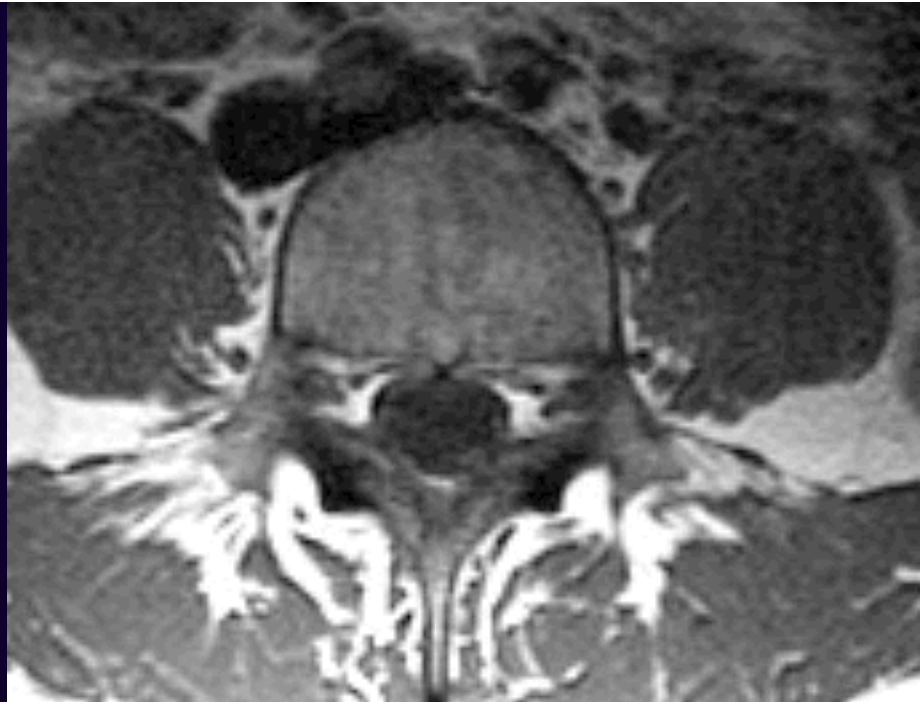




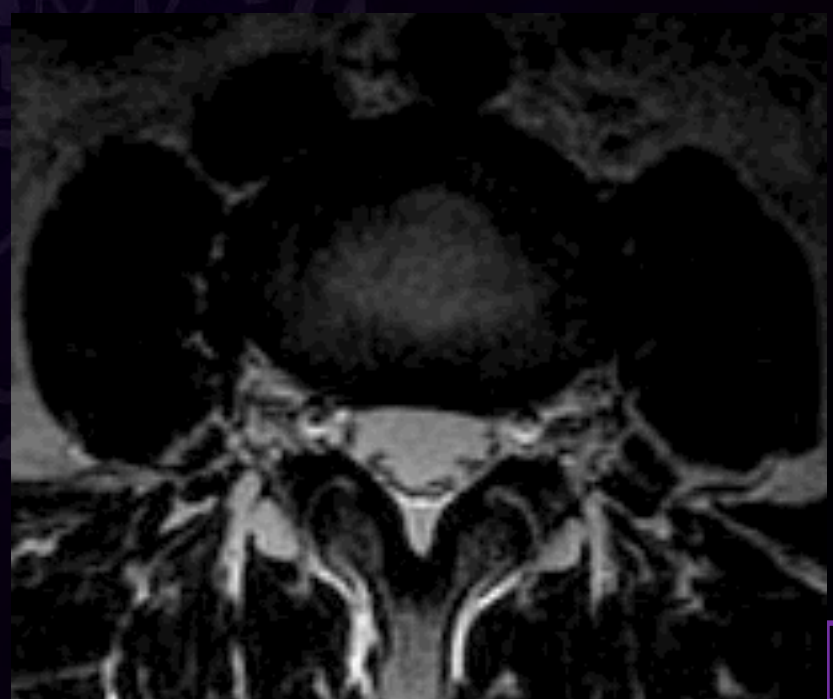
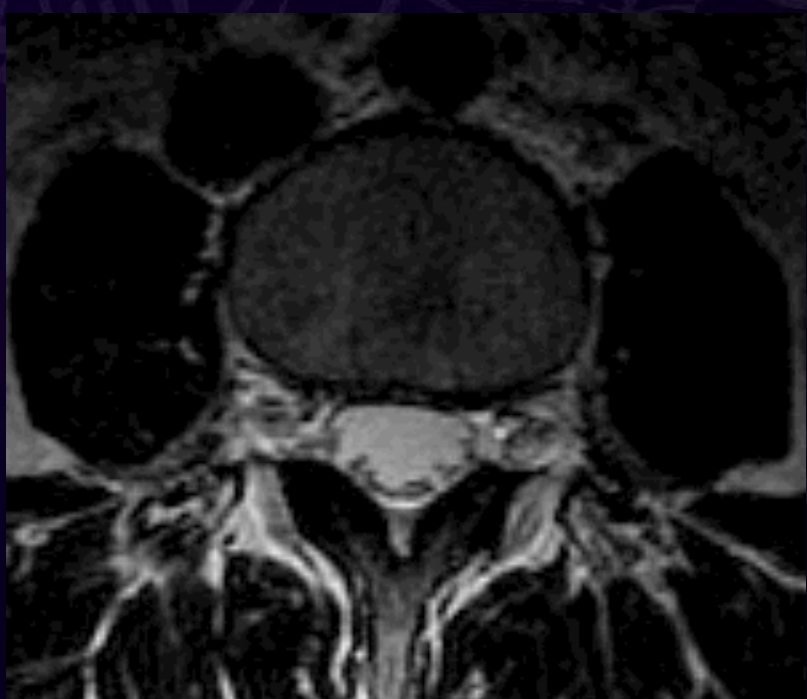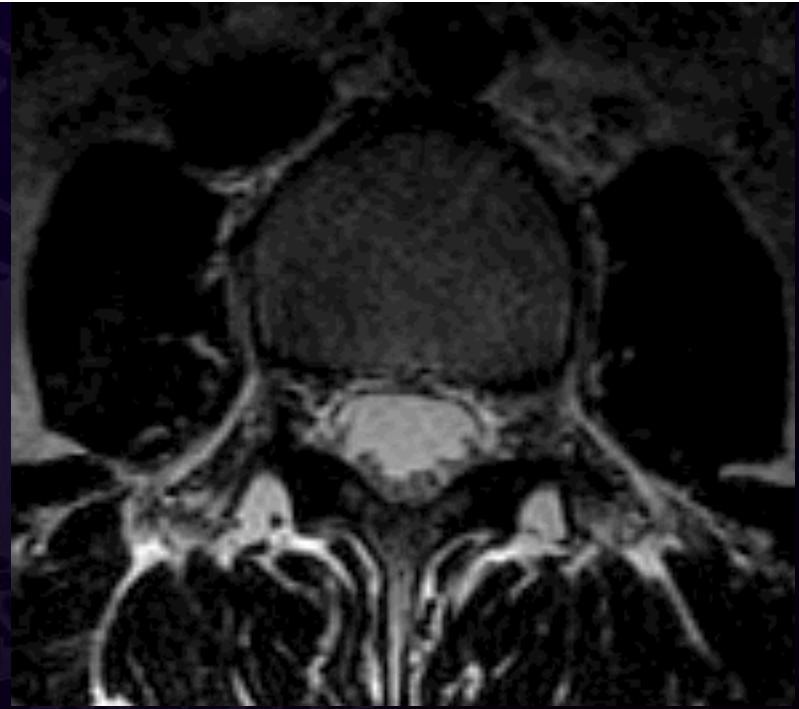




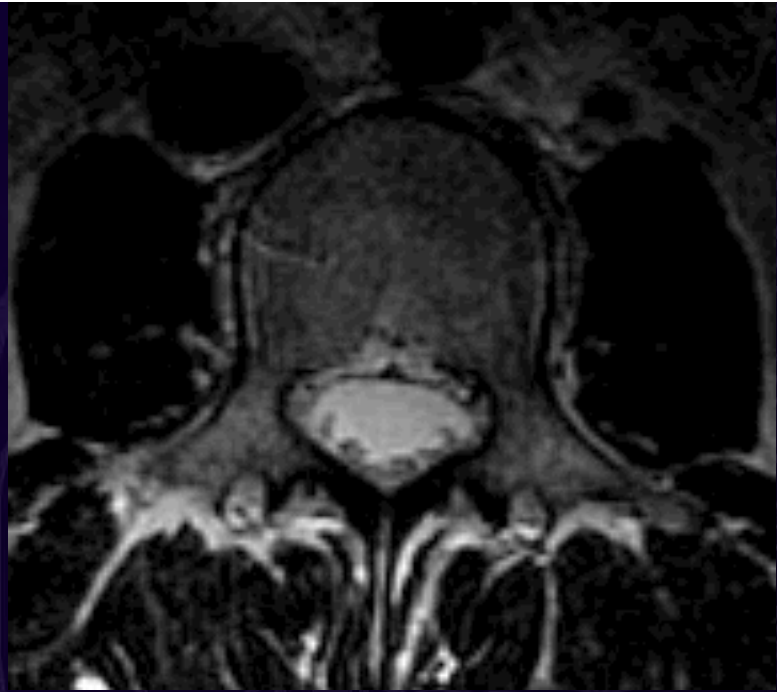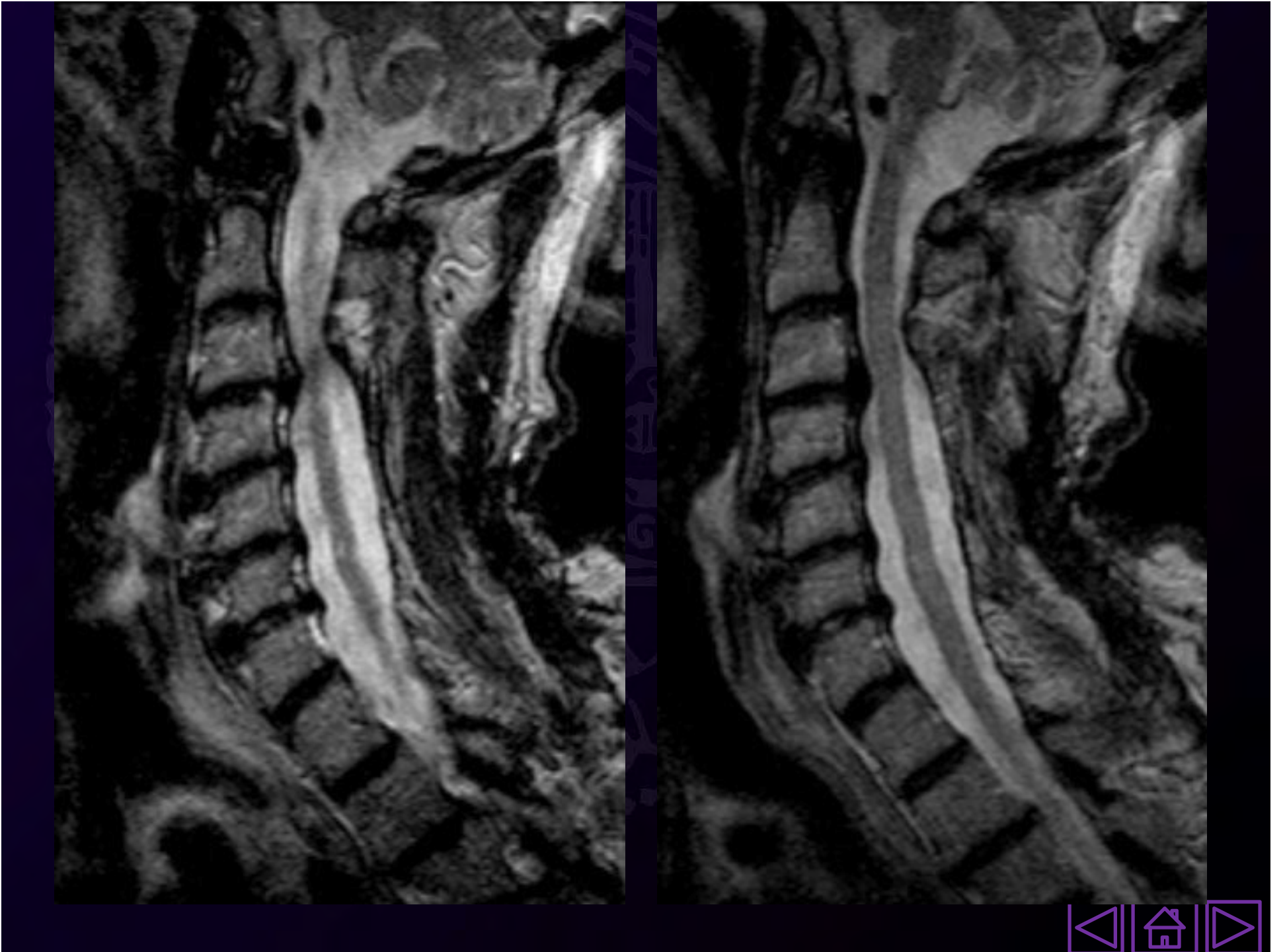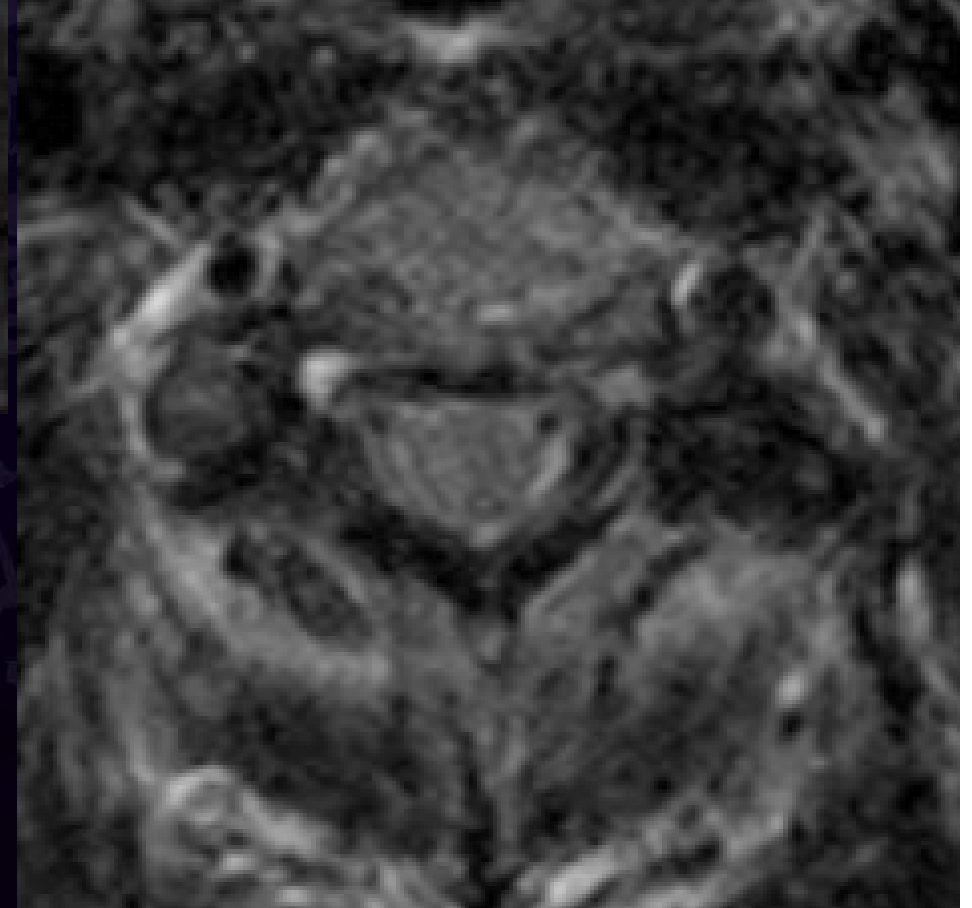

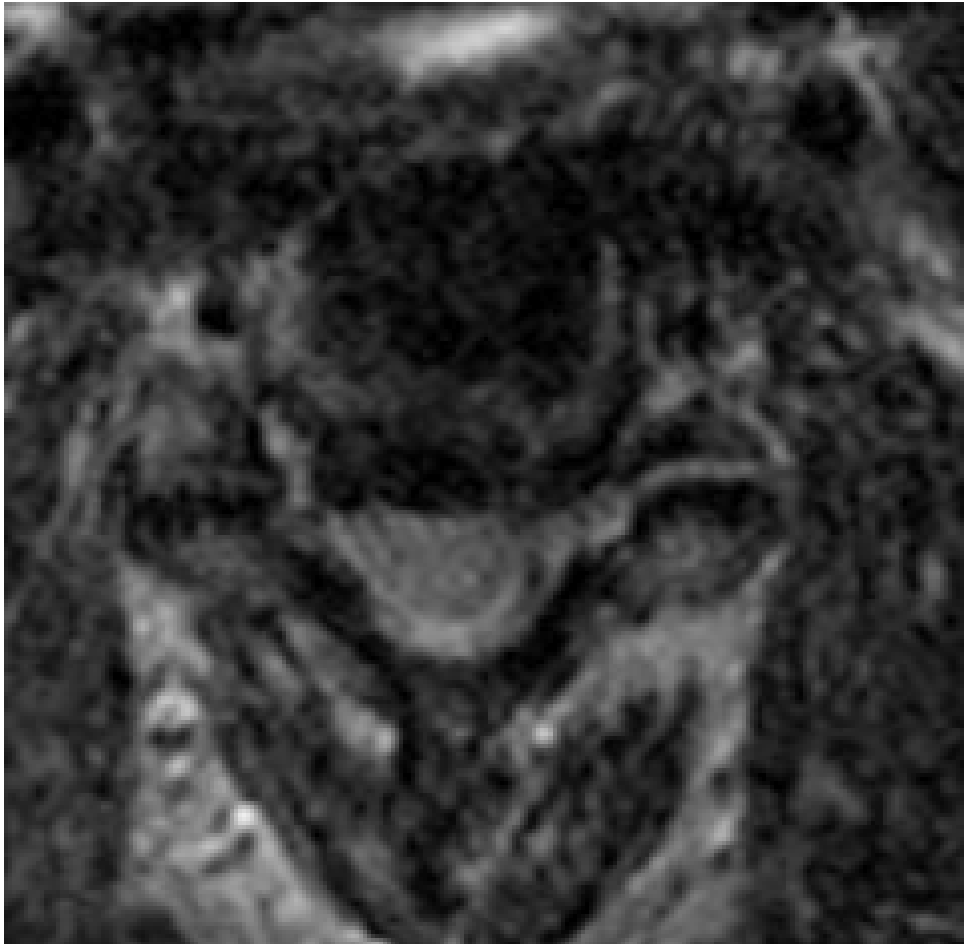


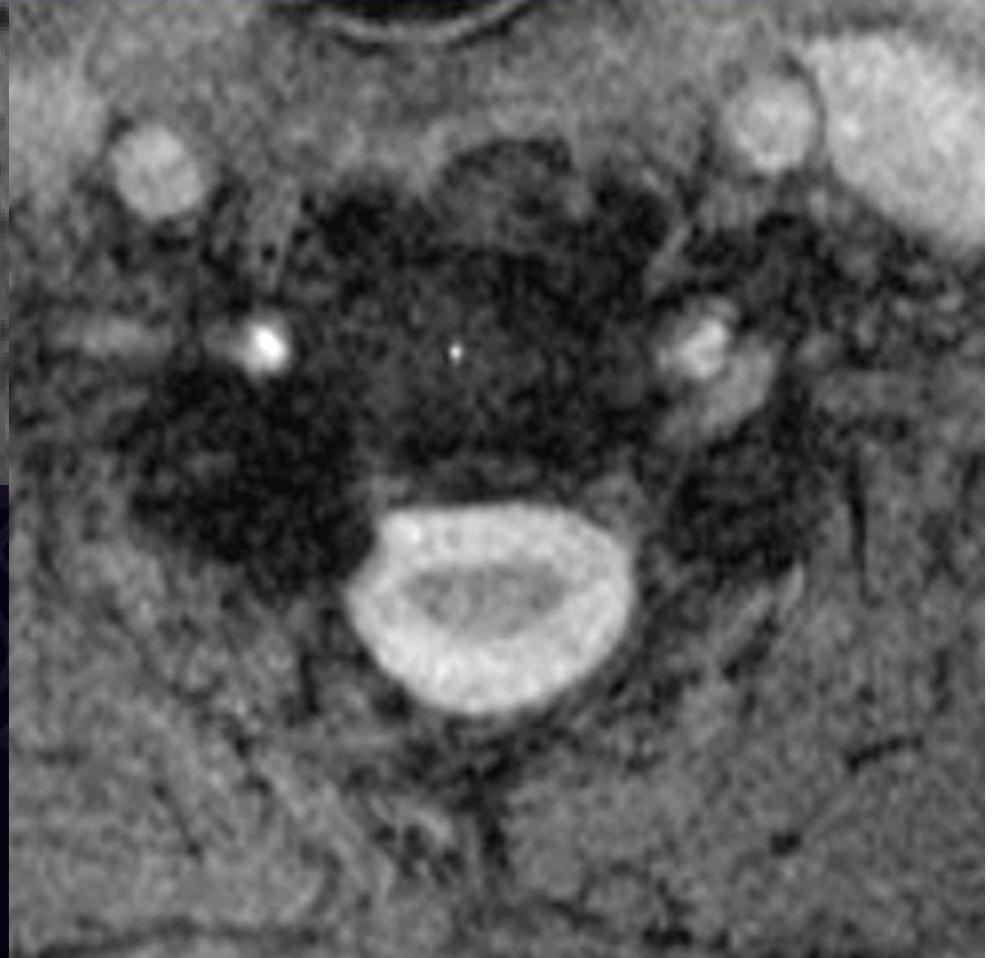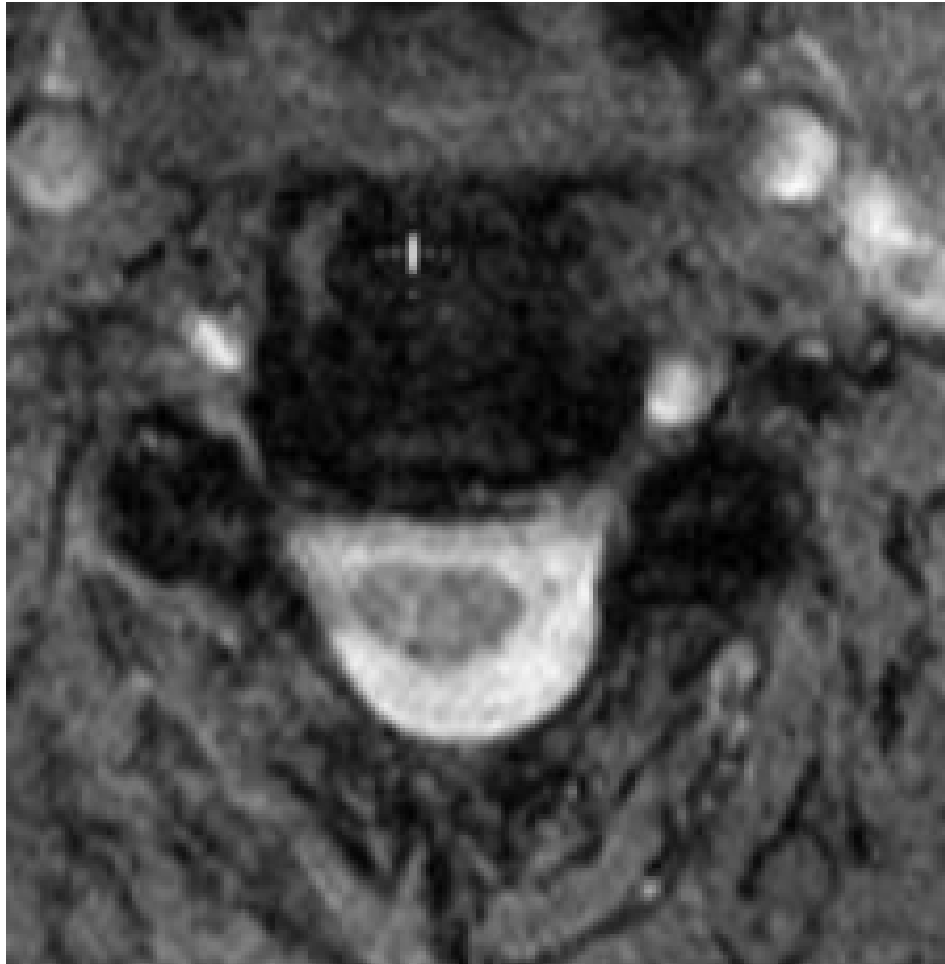


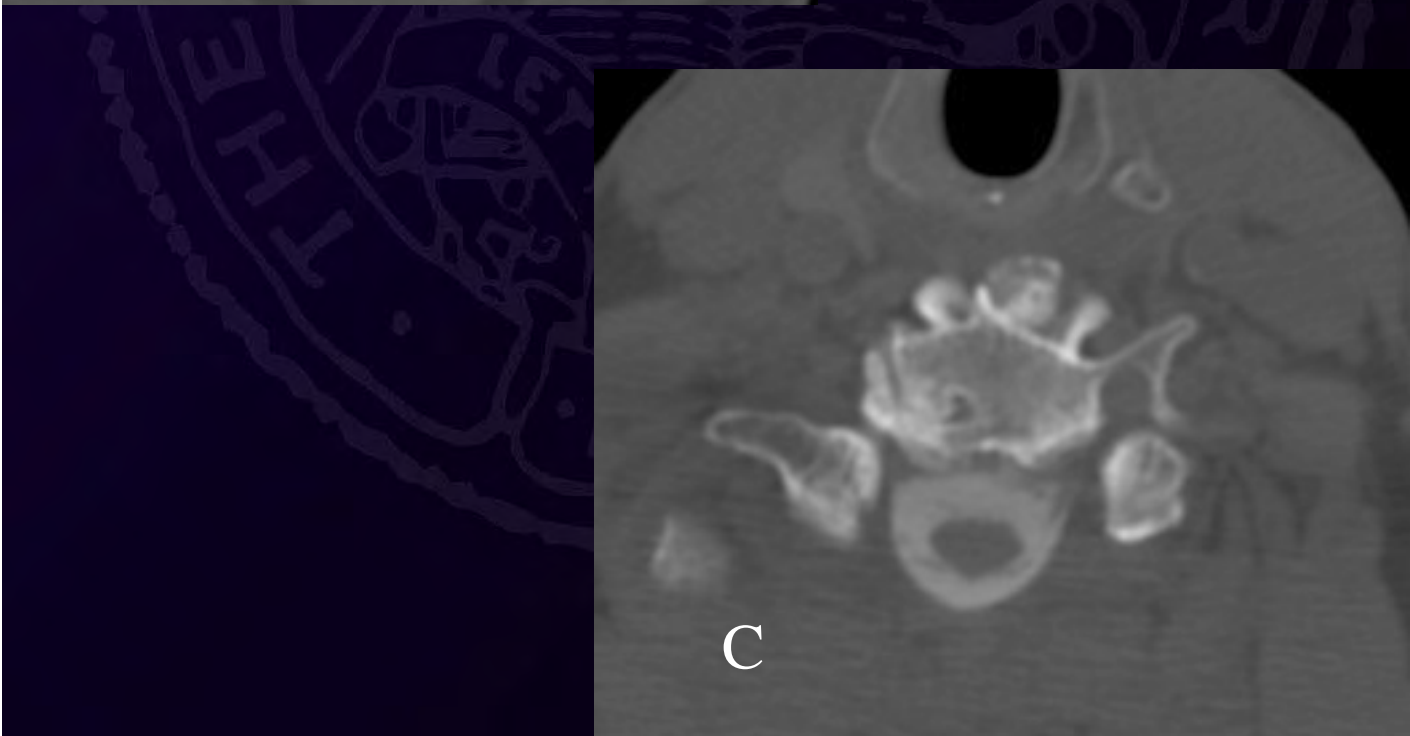
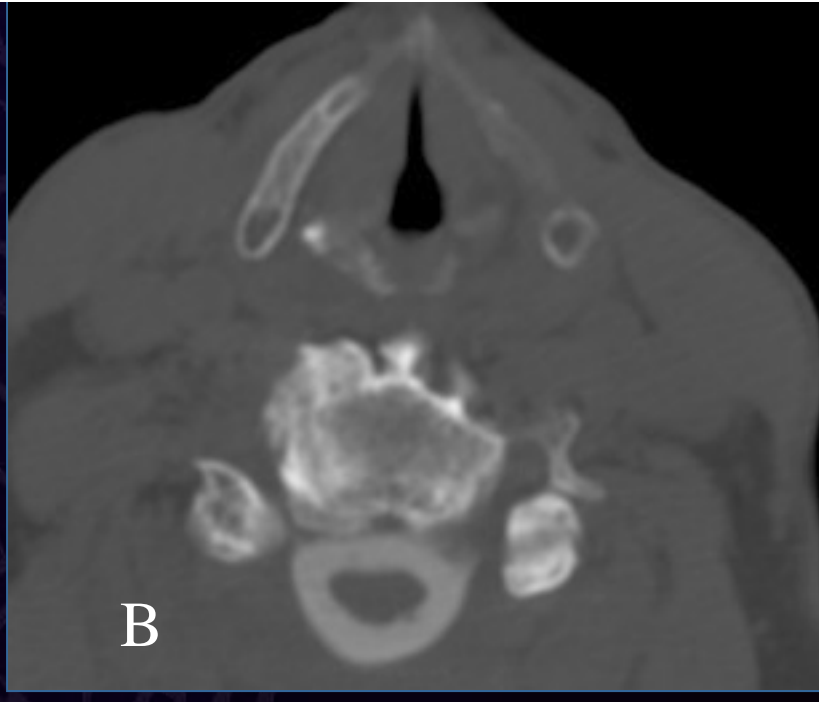
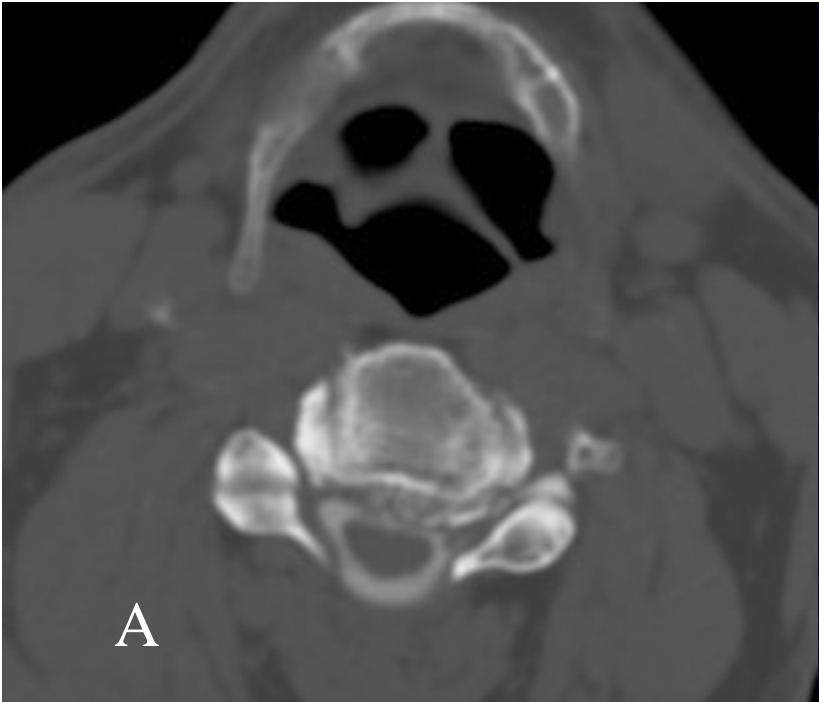




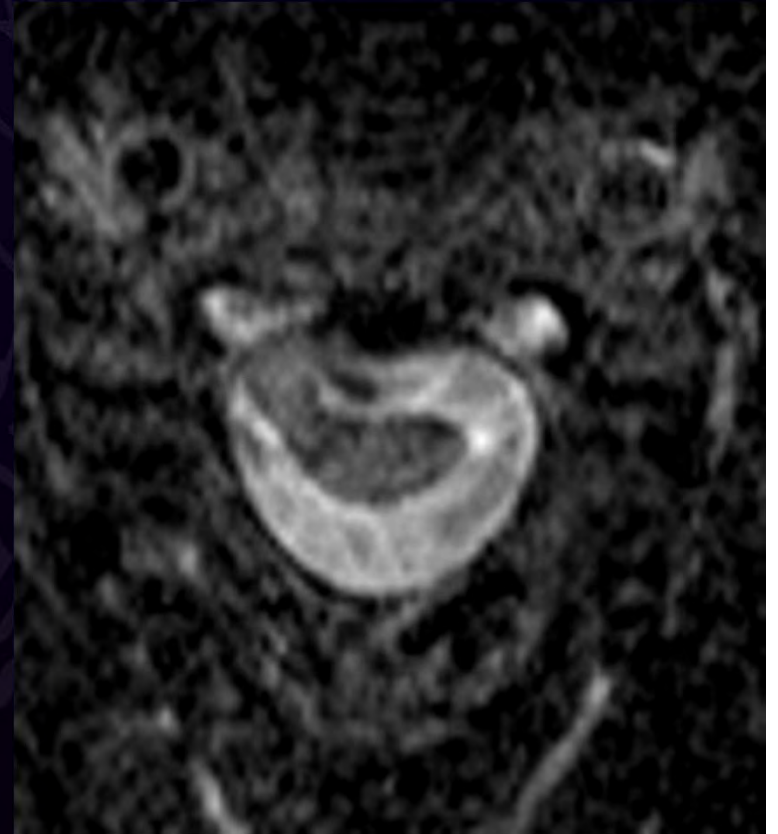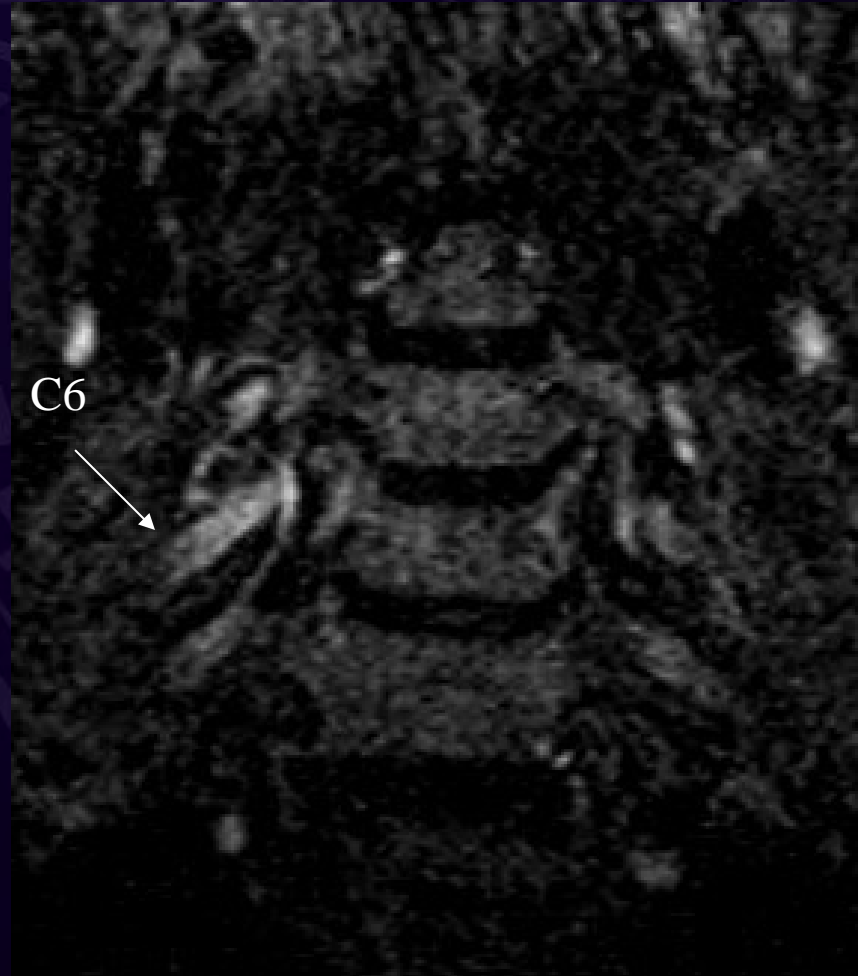








# Pre-operative

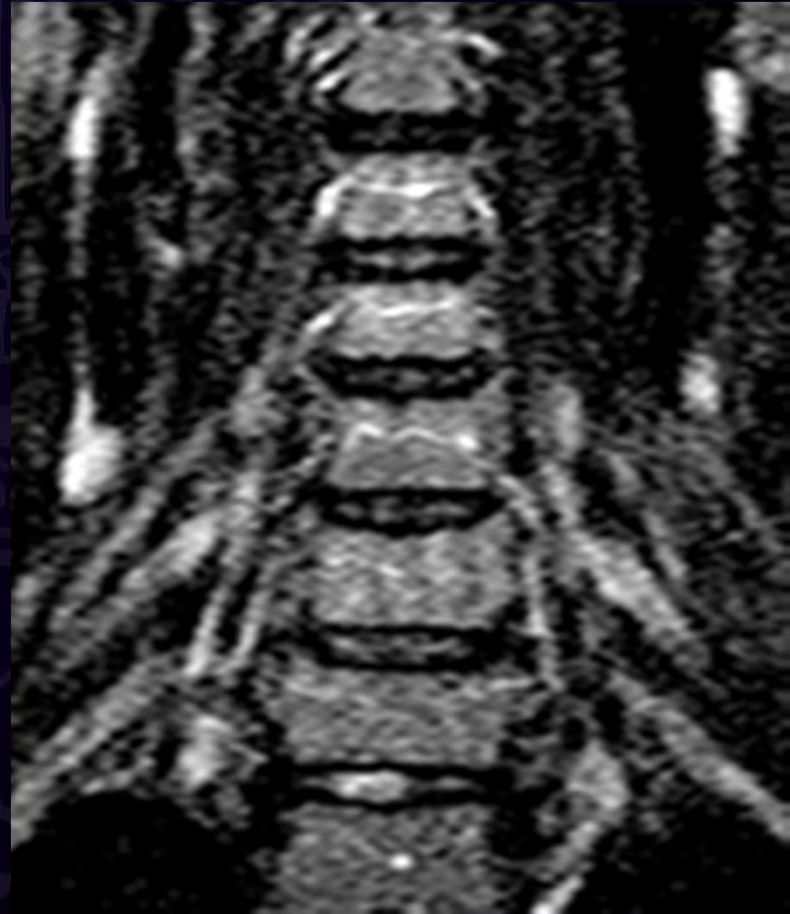

# MR Neurography

Tissue selective  
imaging

Identifying &  
evaluating  
characteristics of  
nerve morphology

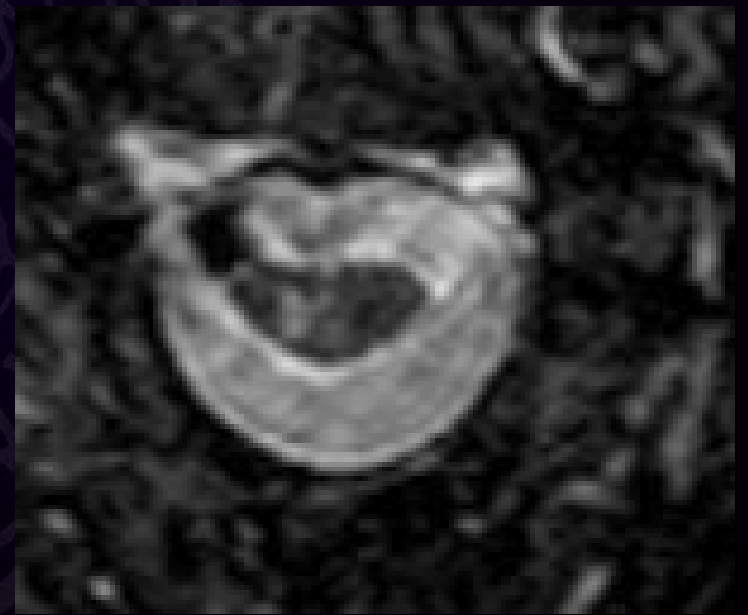
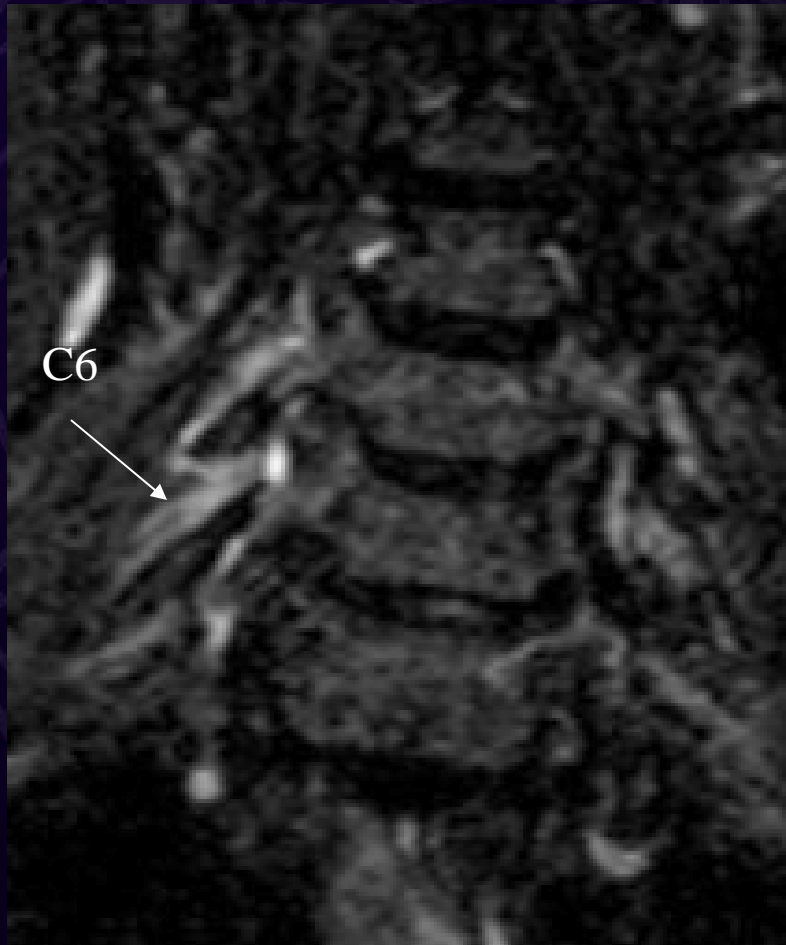
Localizes pathology



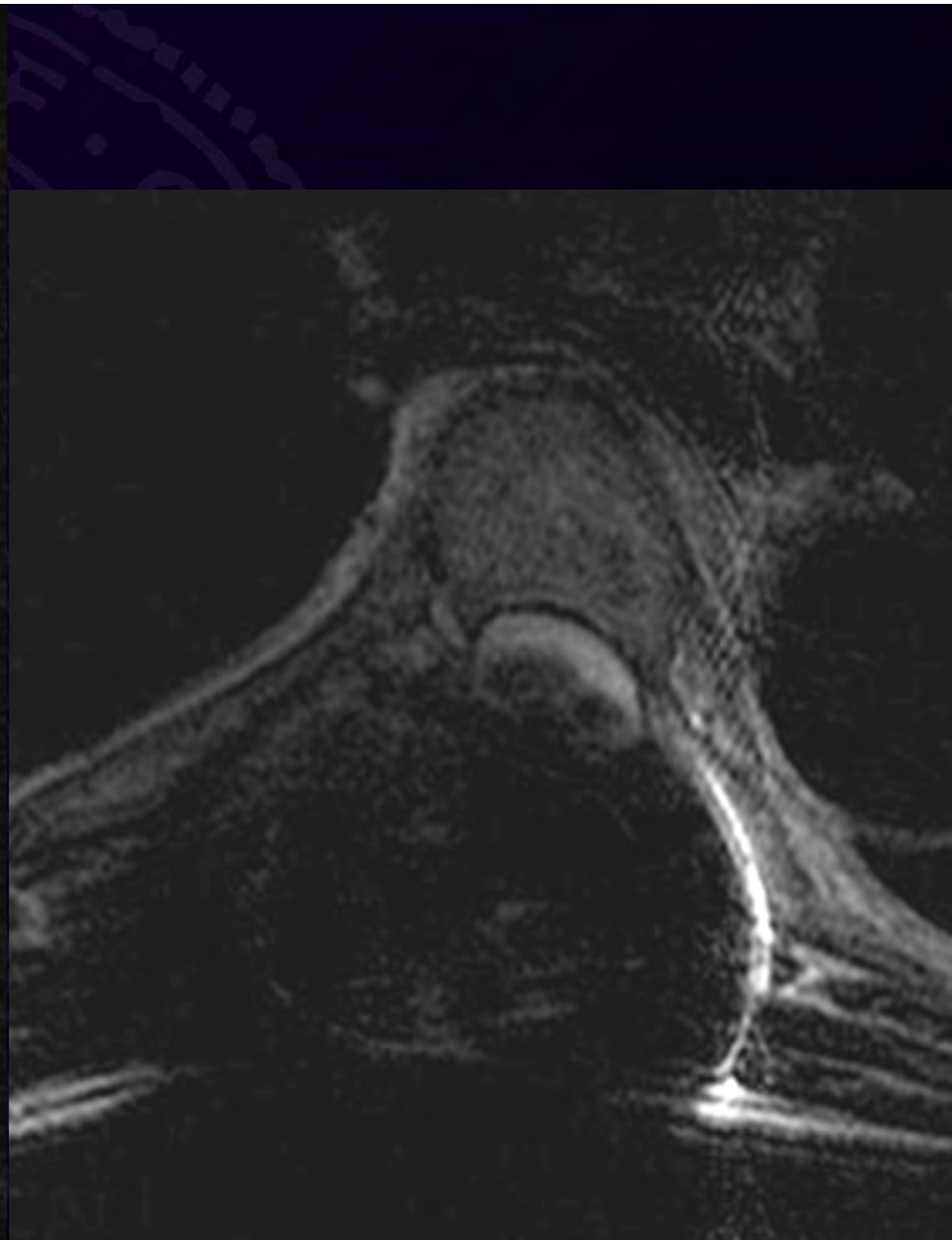
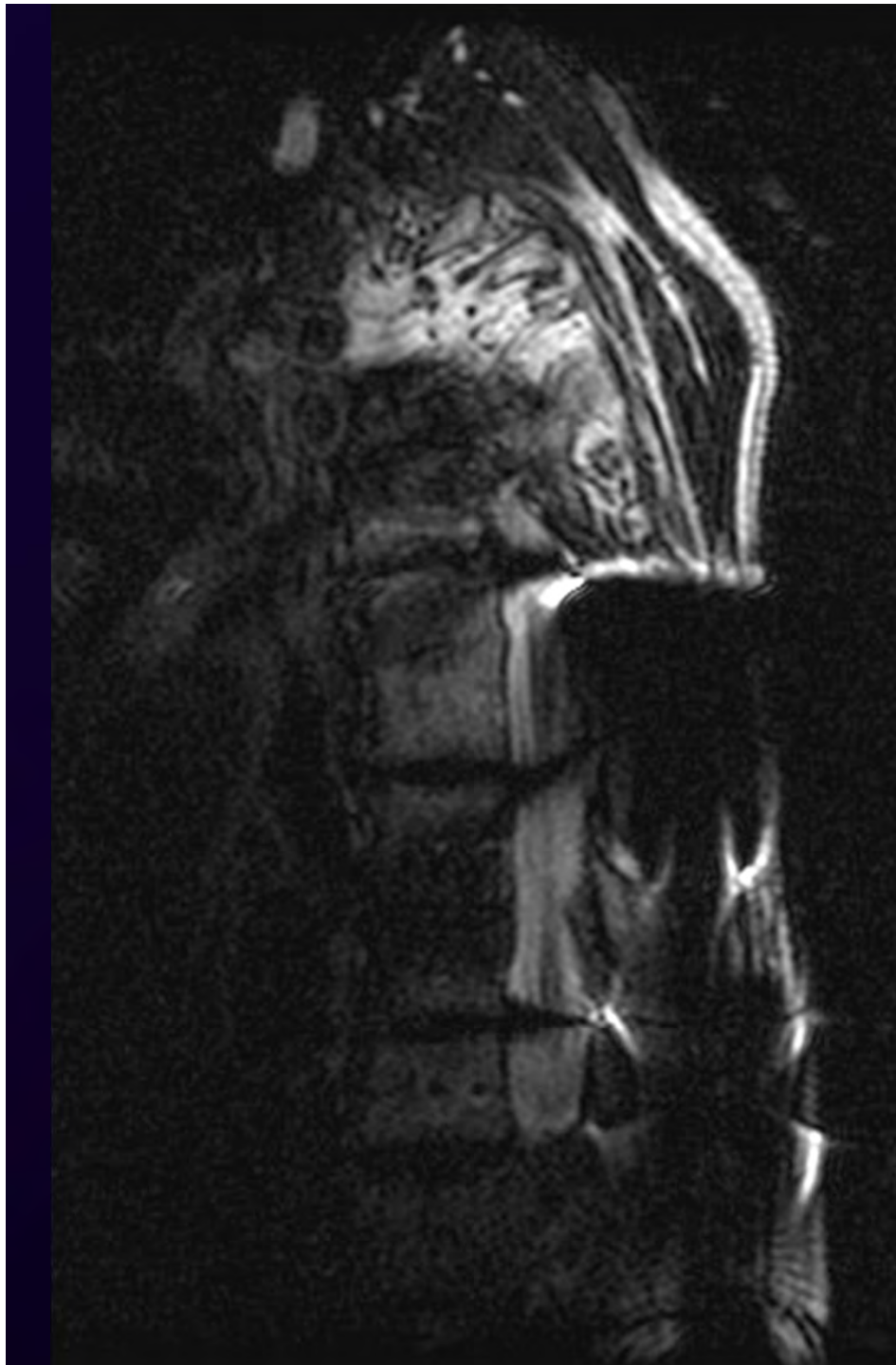
Coronal STIR: cervical roots

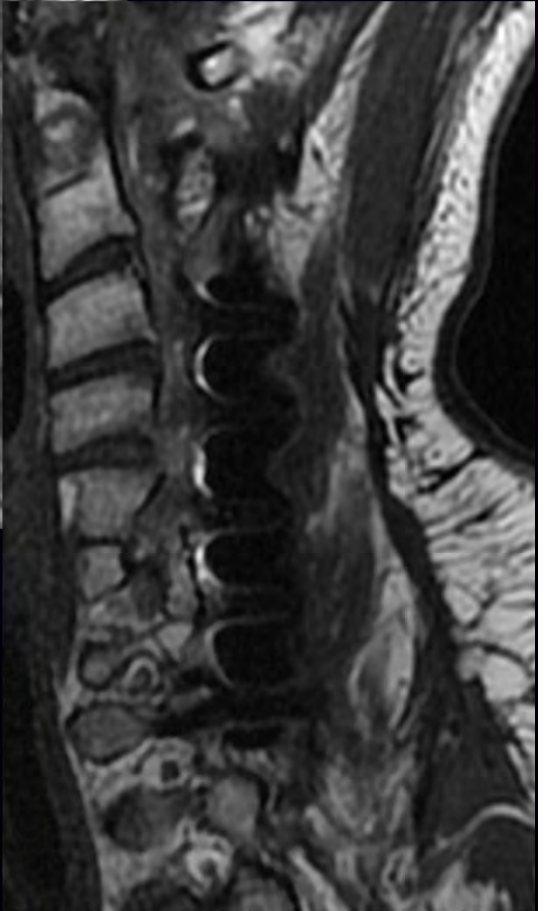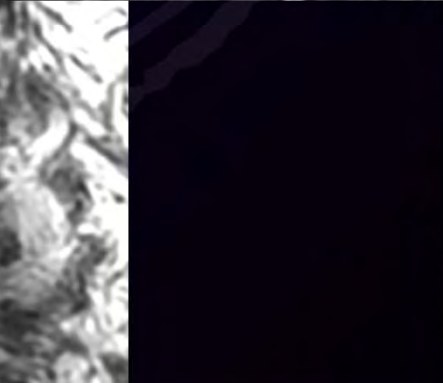

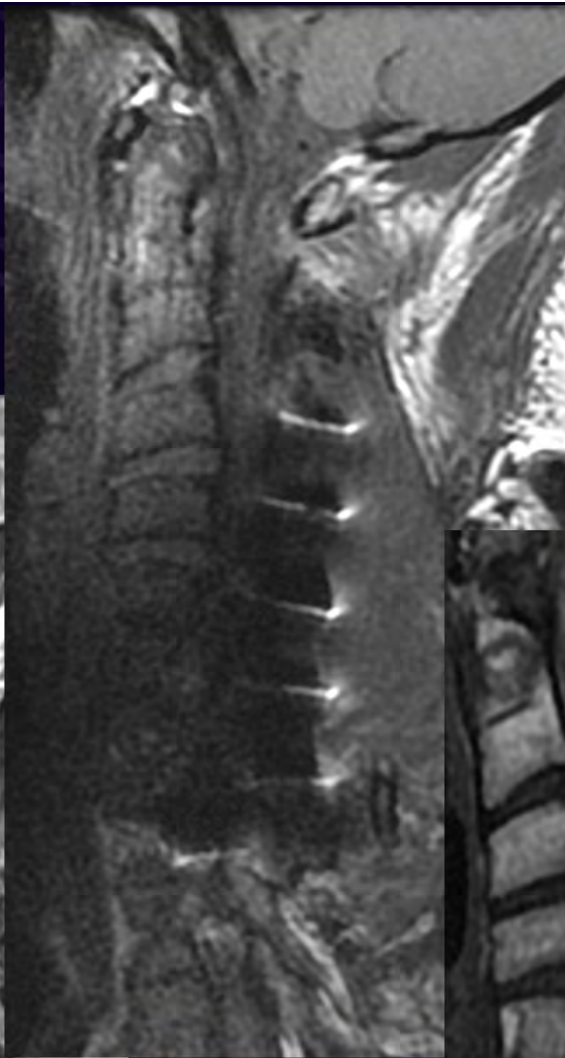
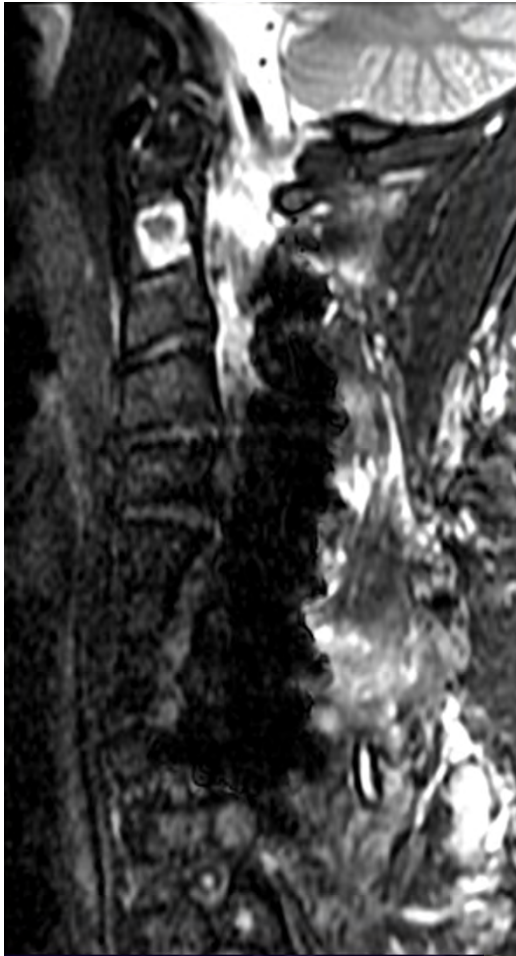


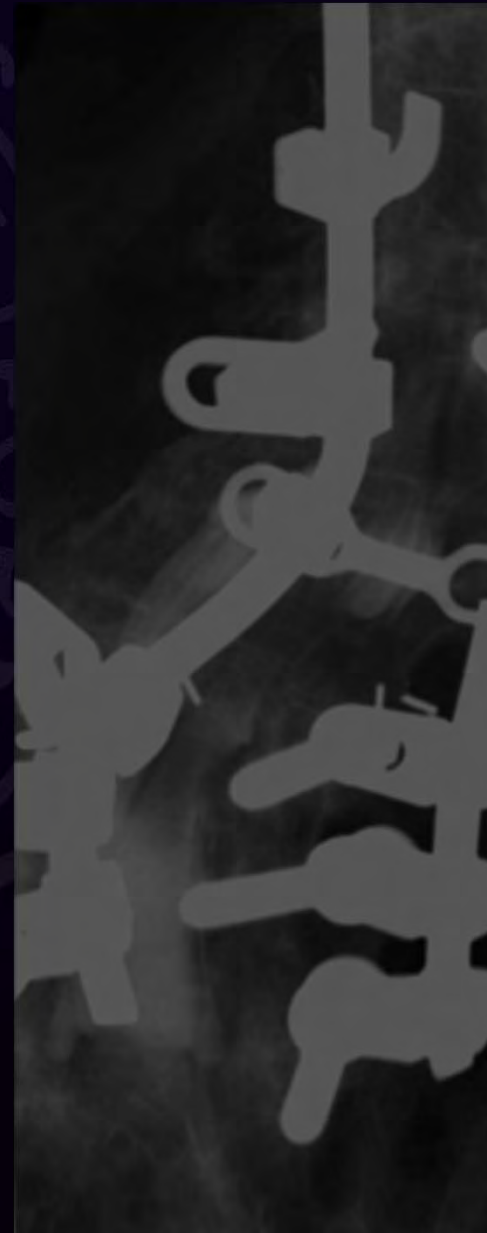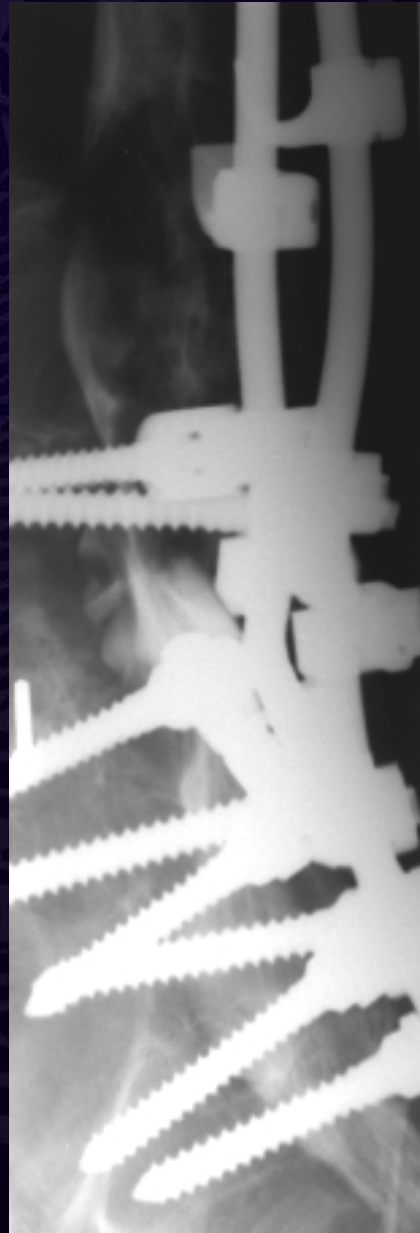
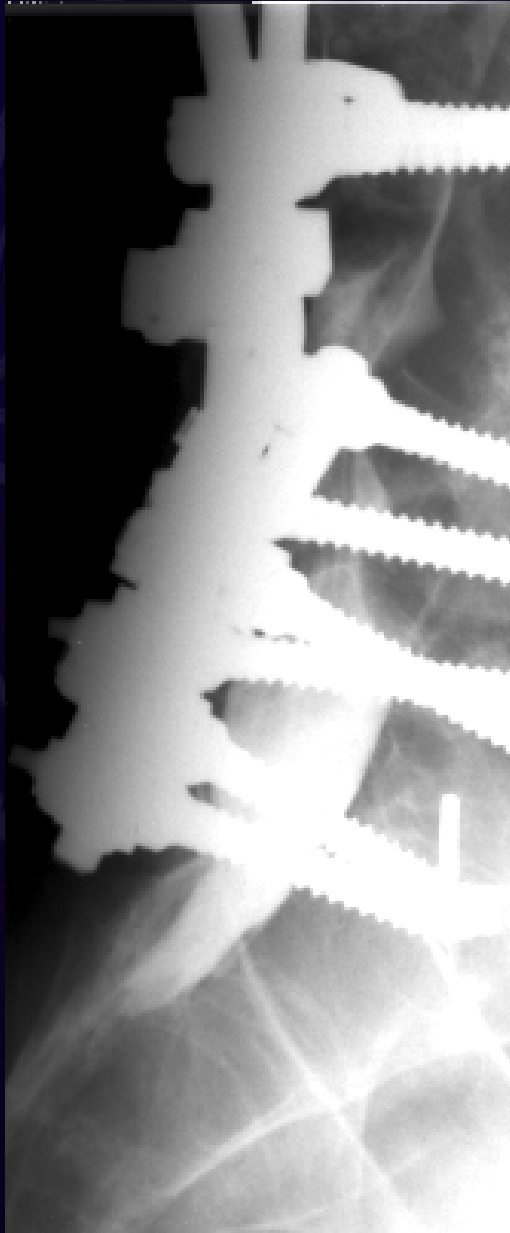
# Post-operative

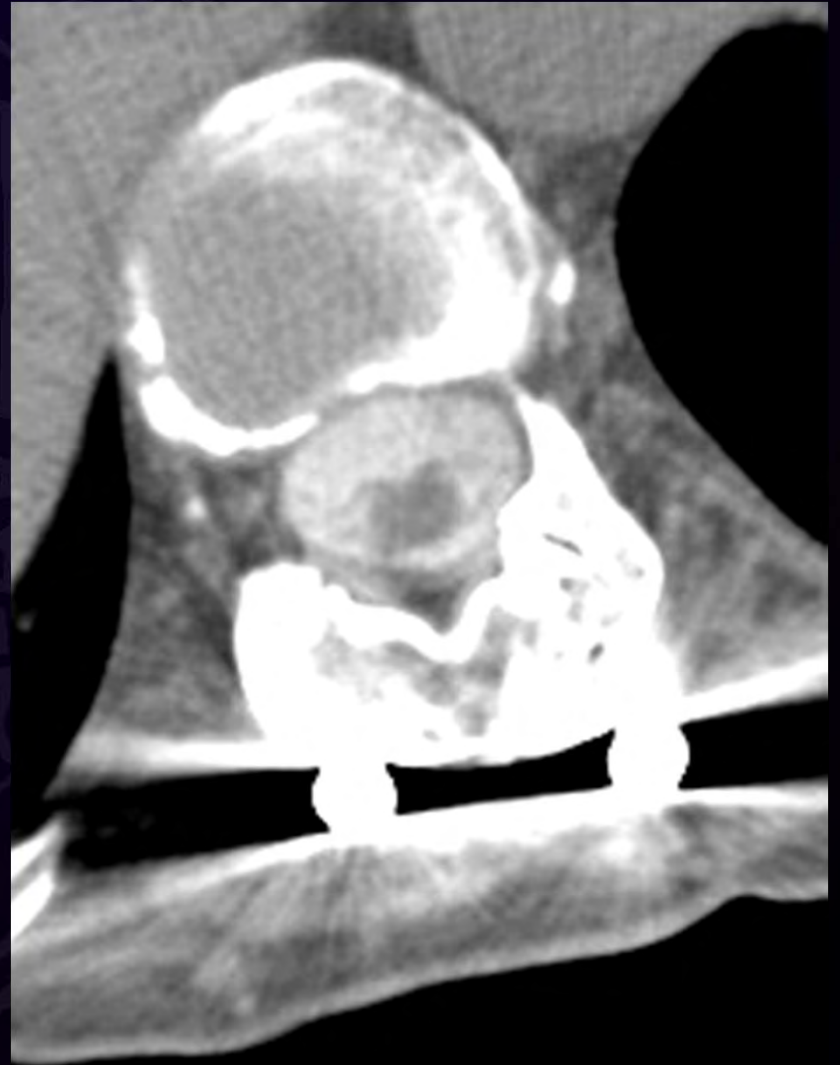
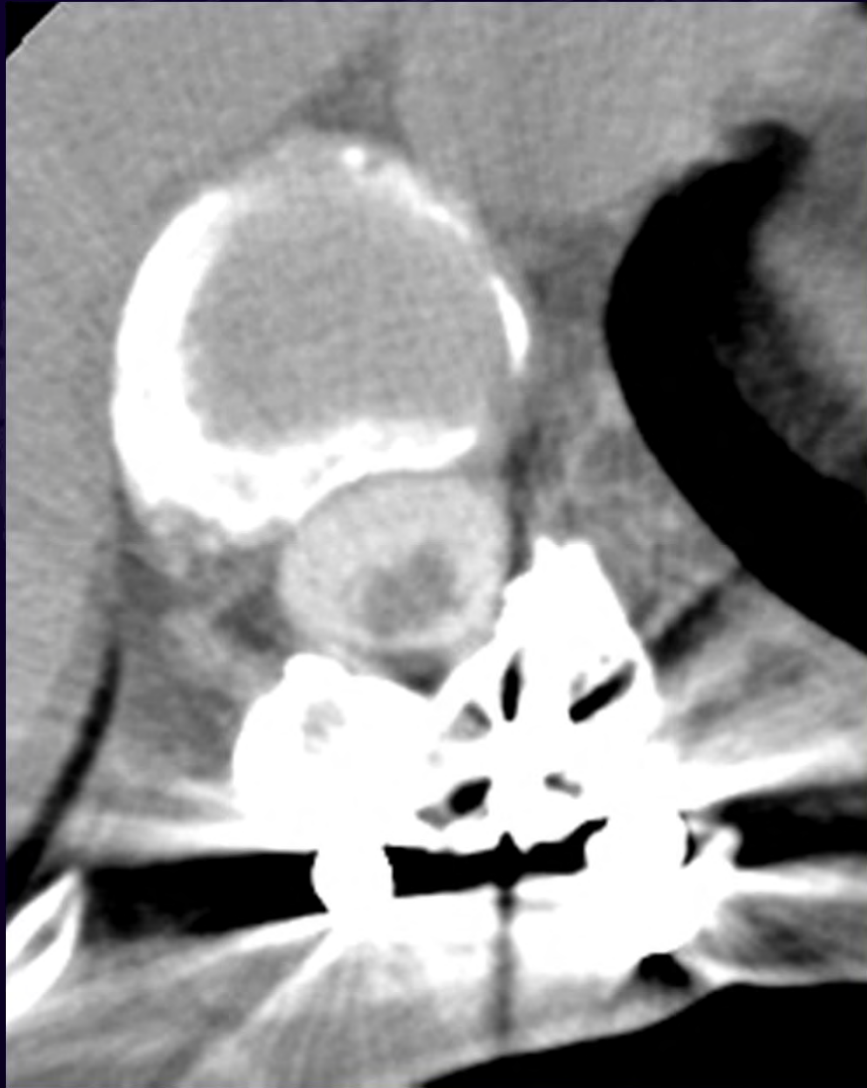


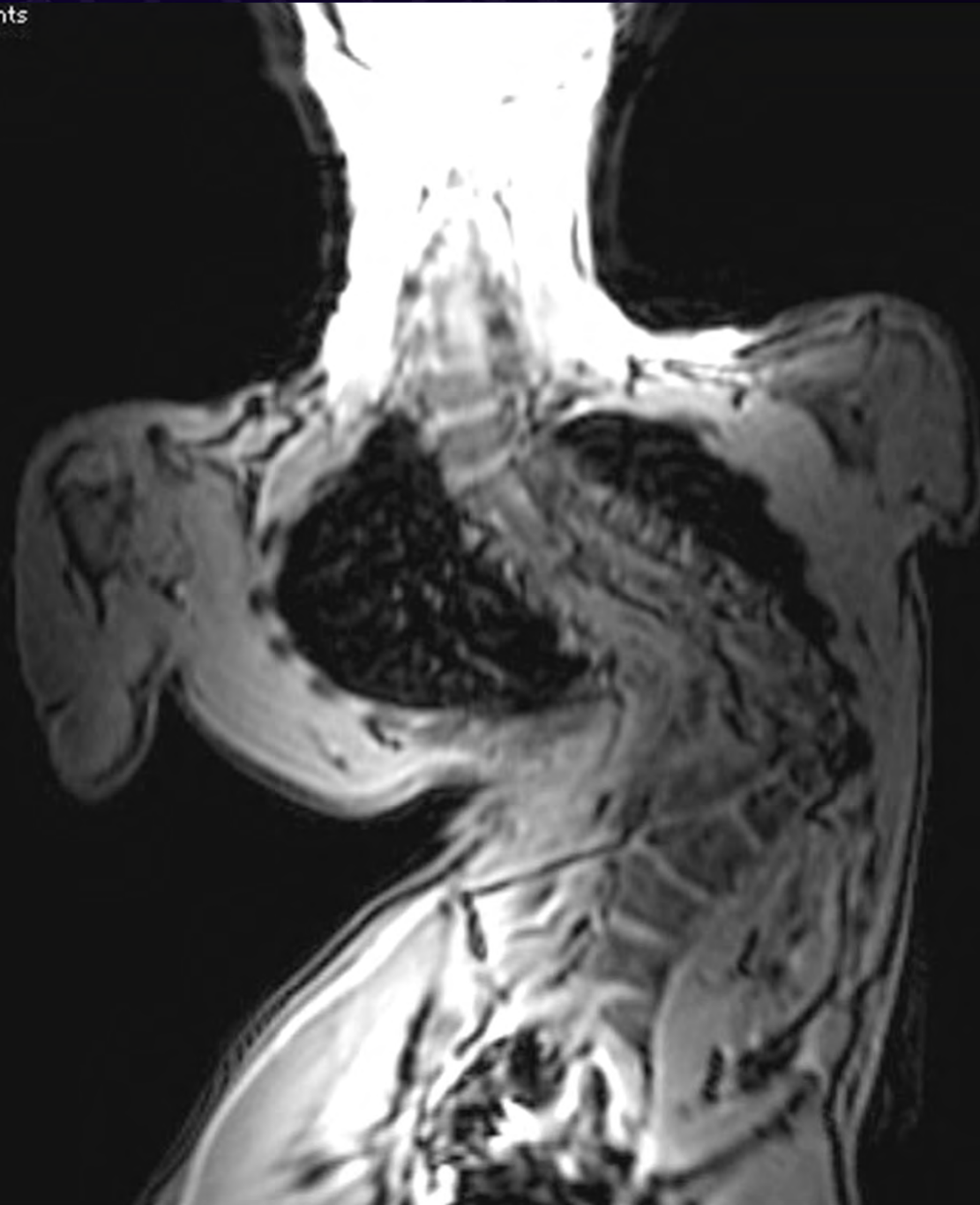


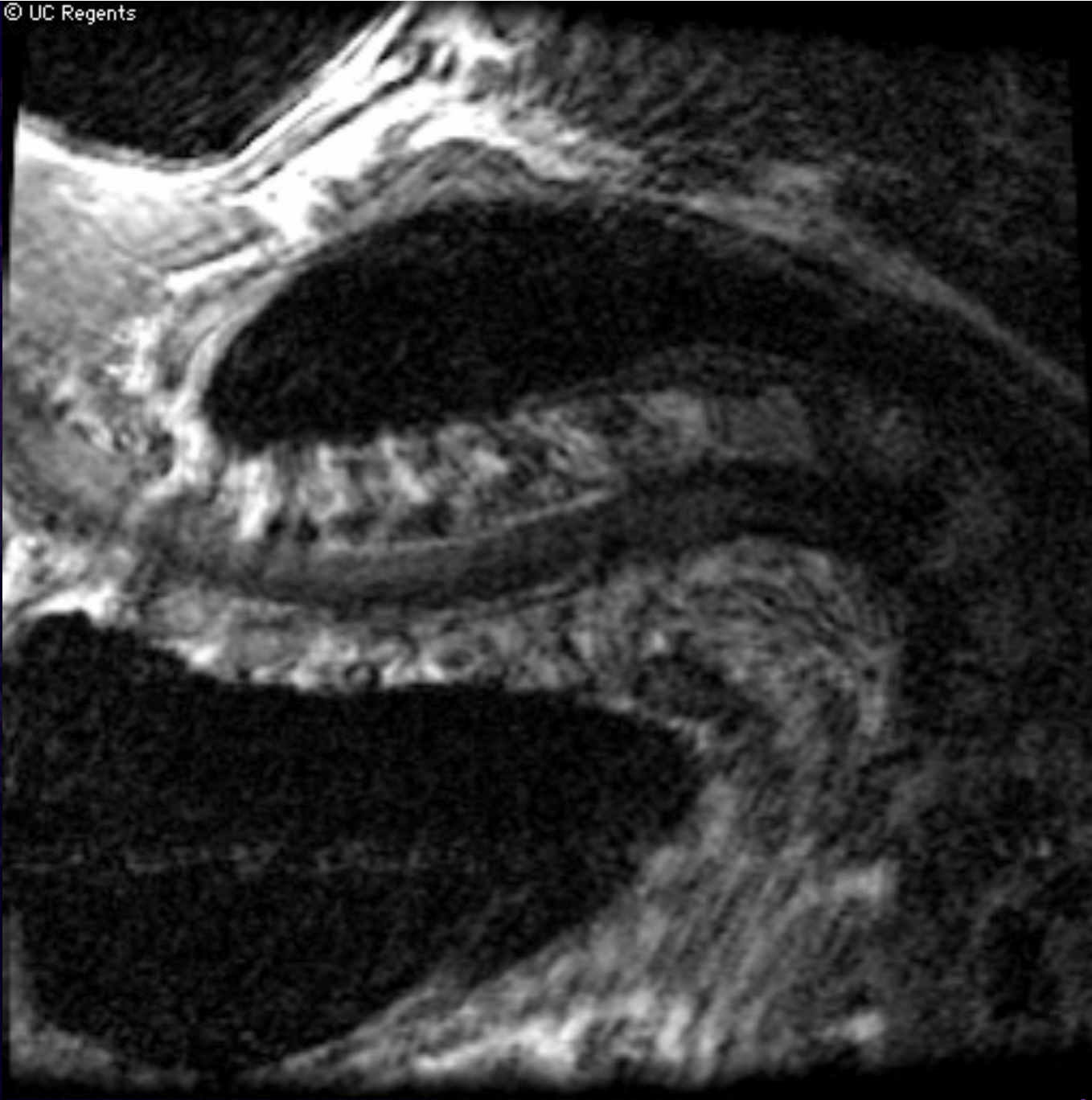


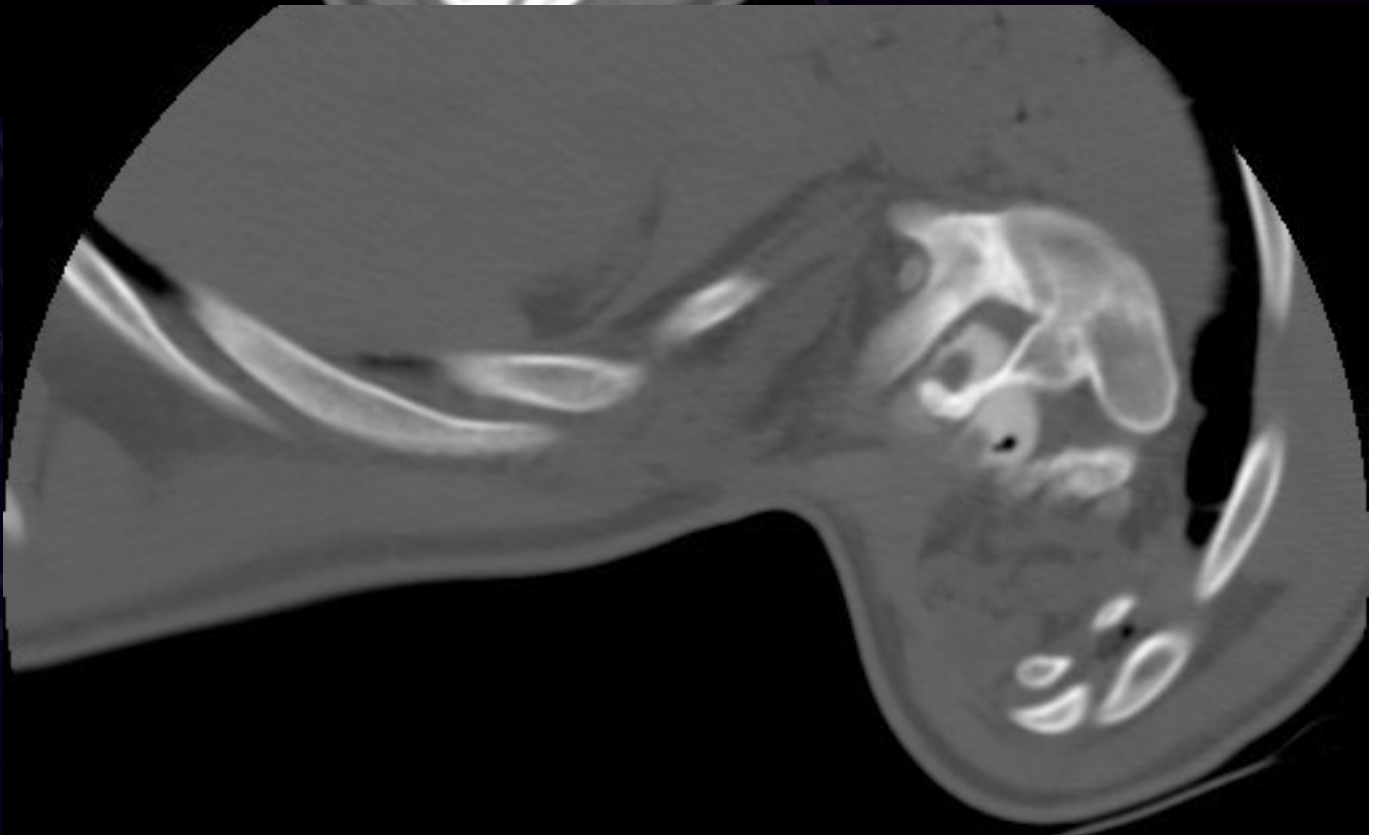
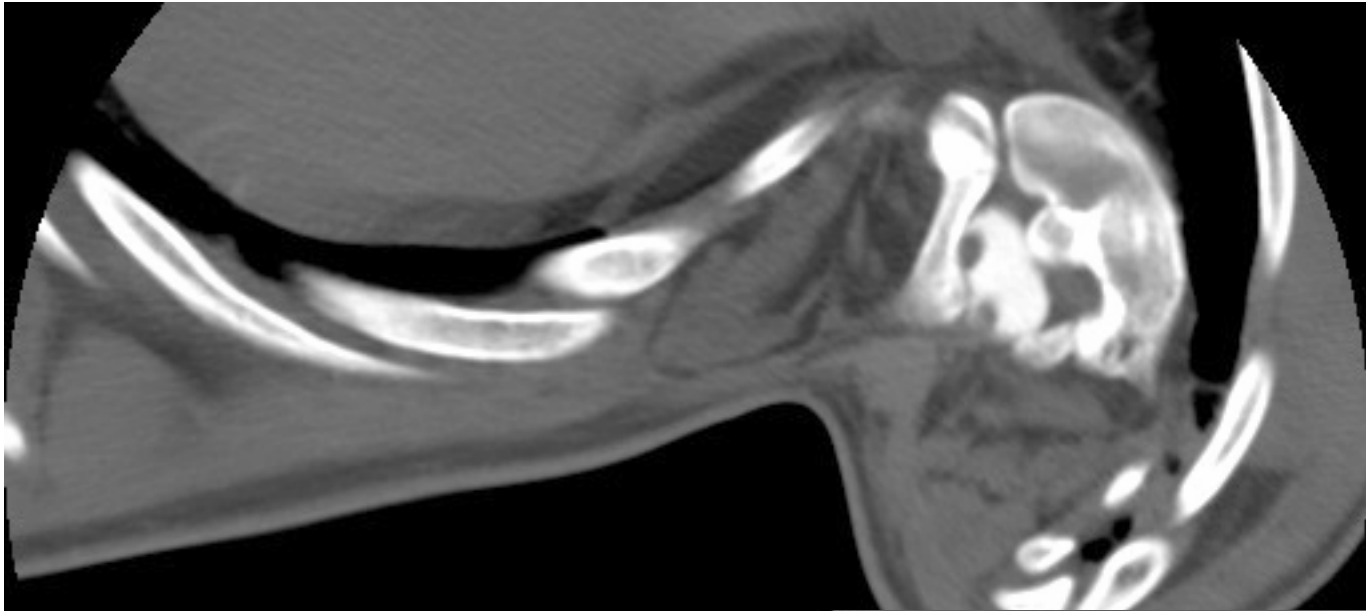


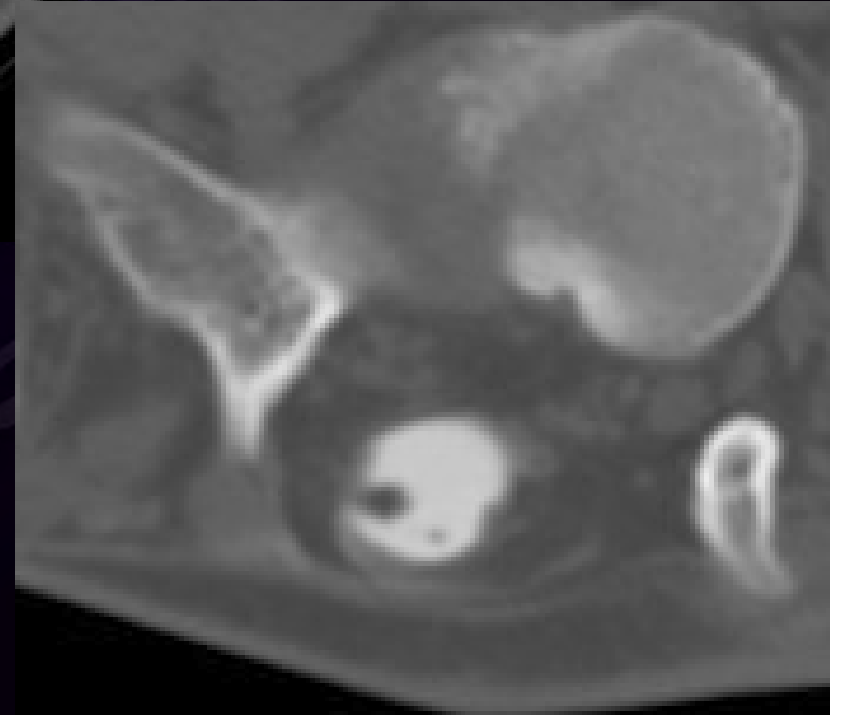
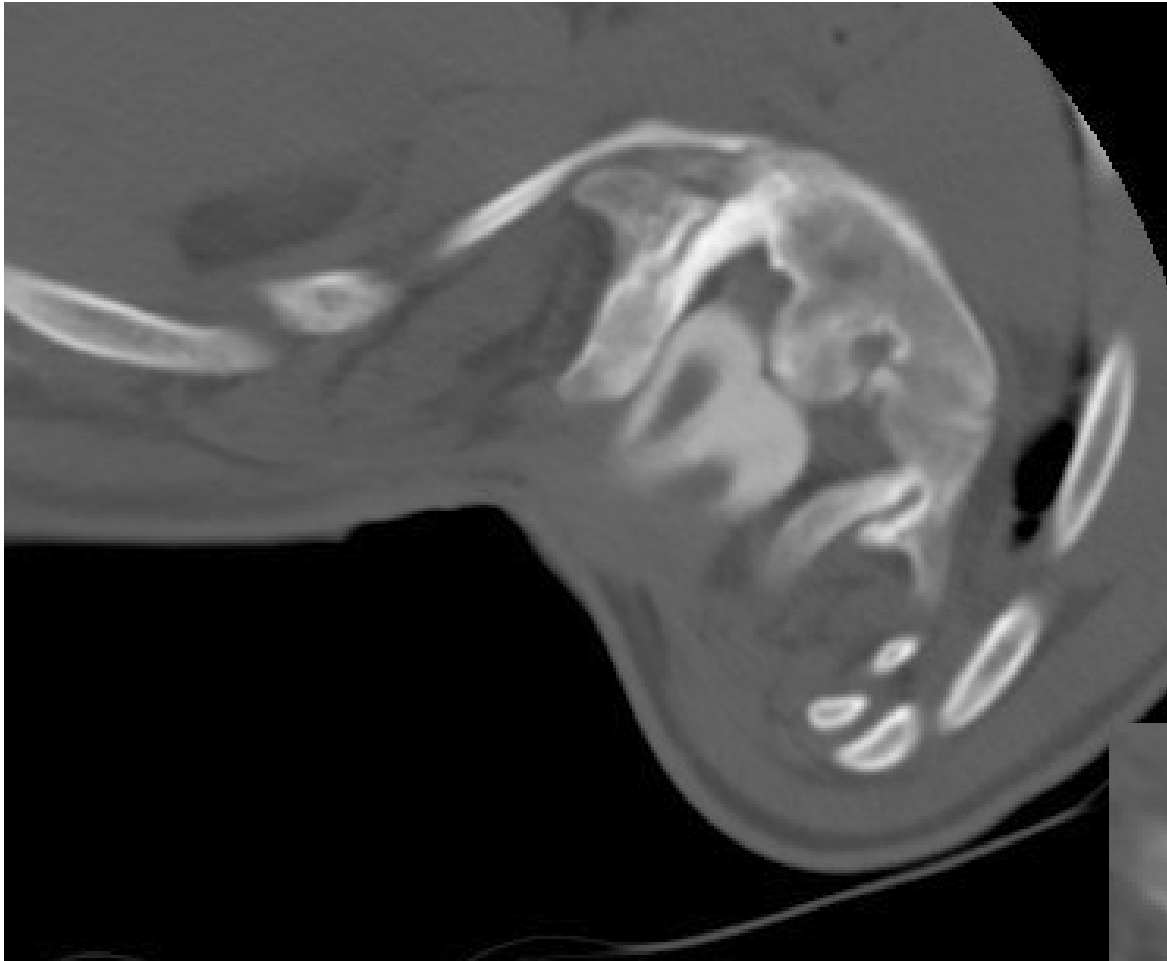


© UC Regents







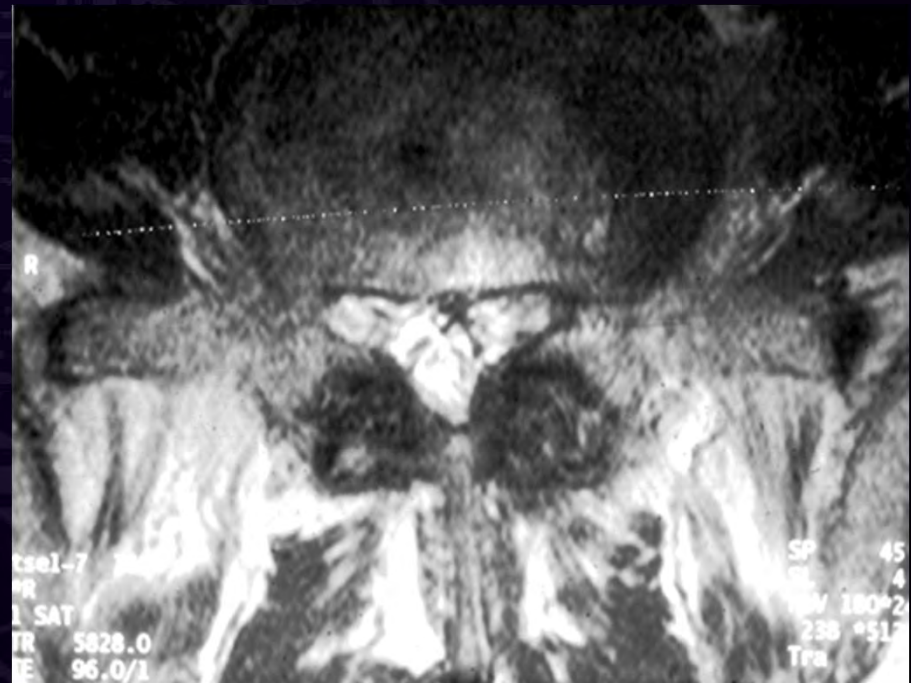
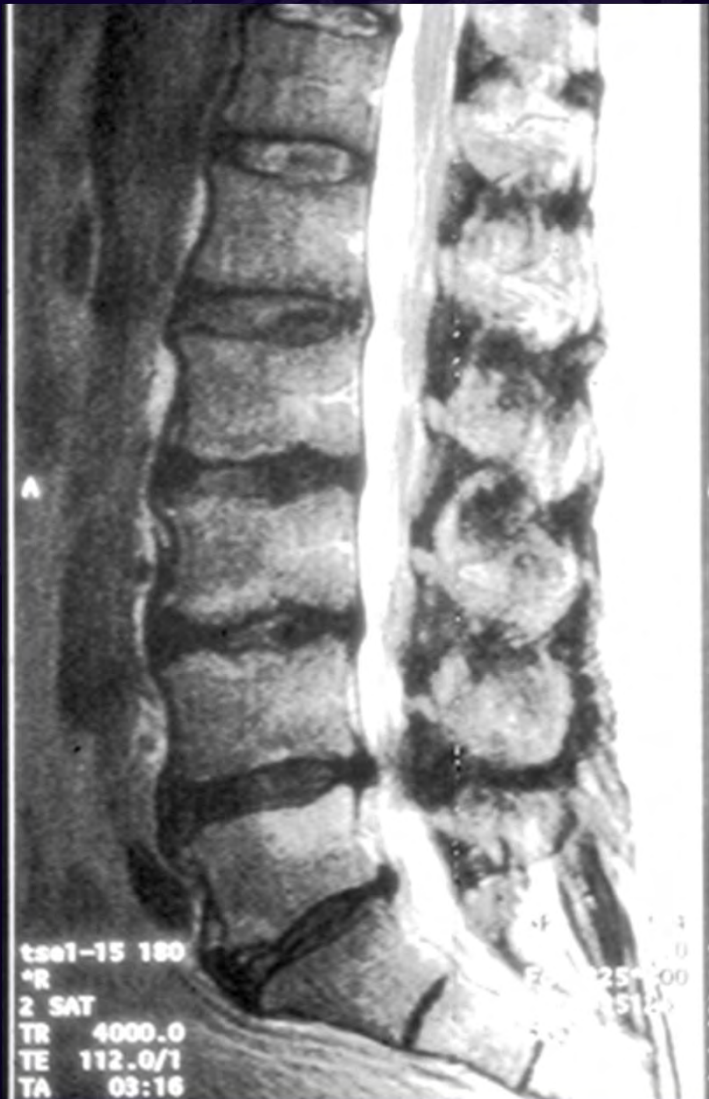

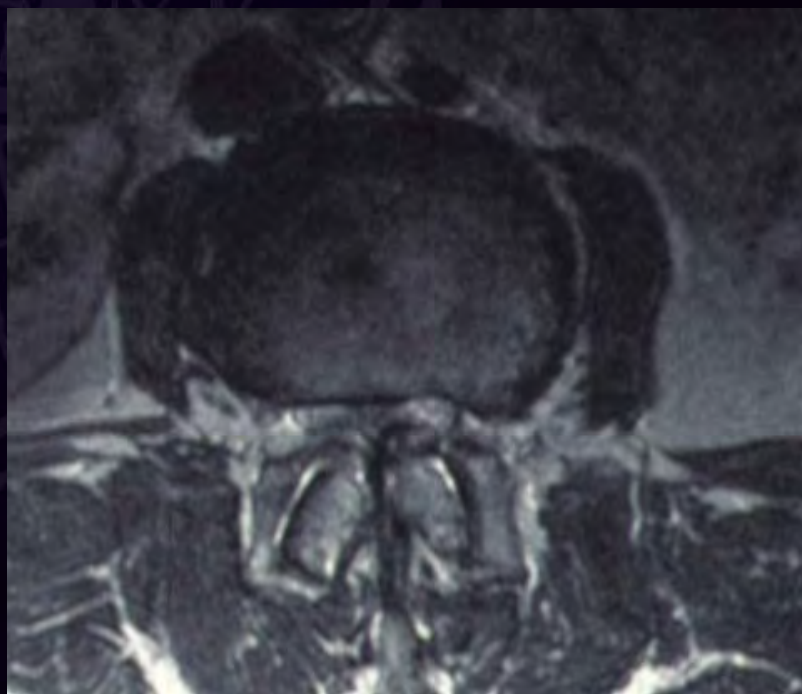
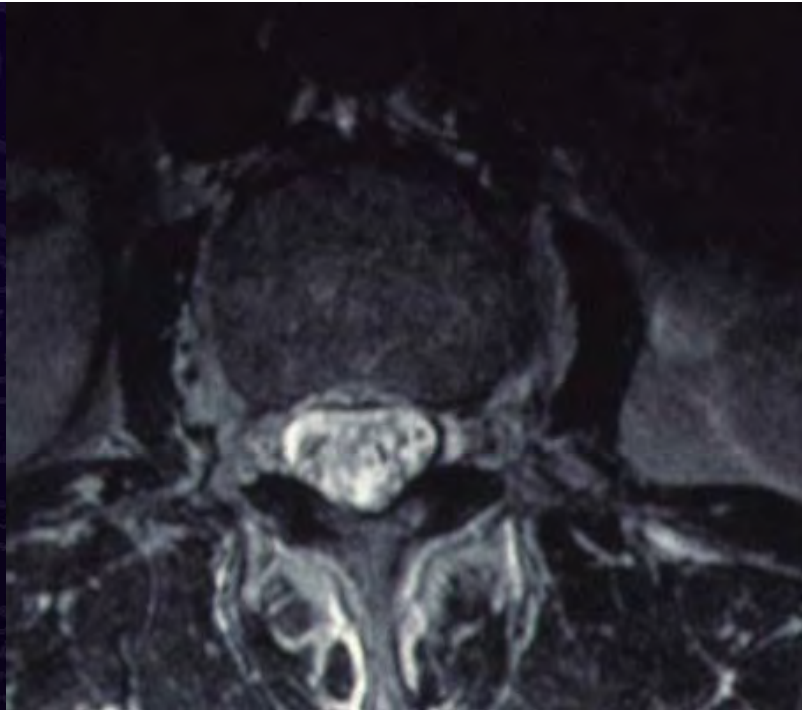

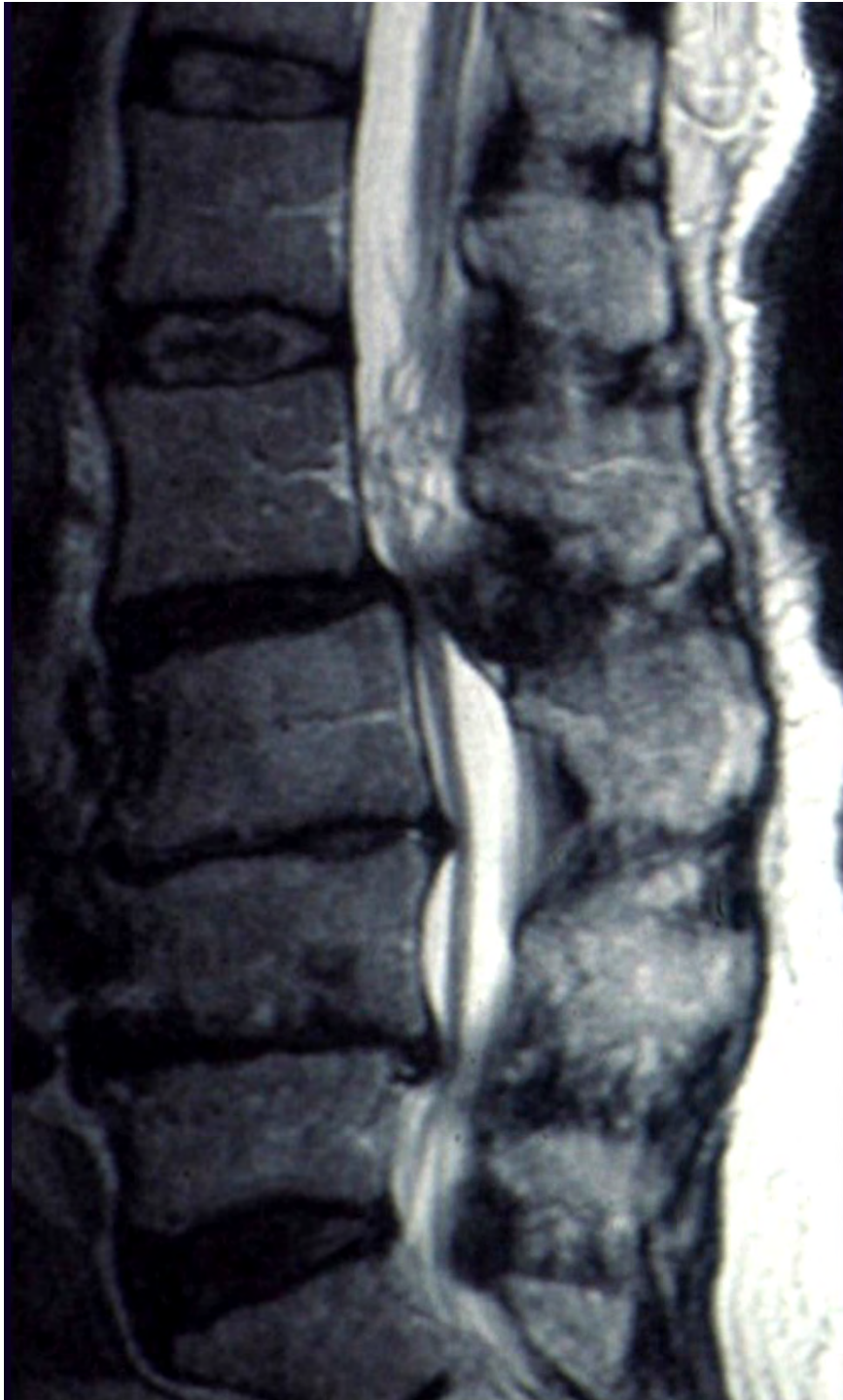
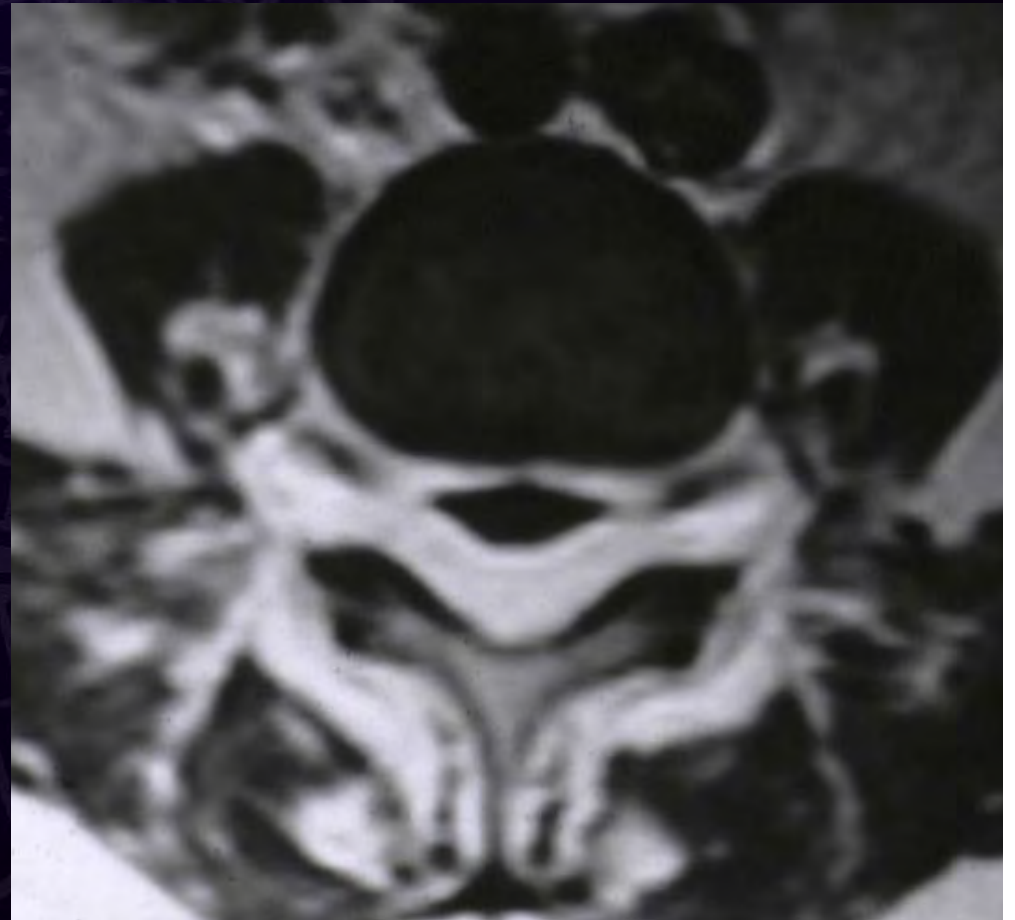
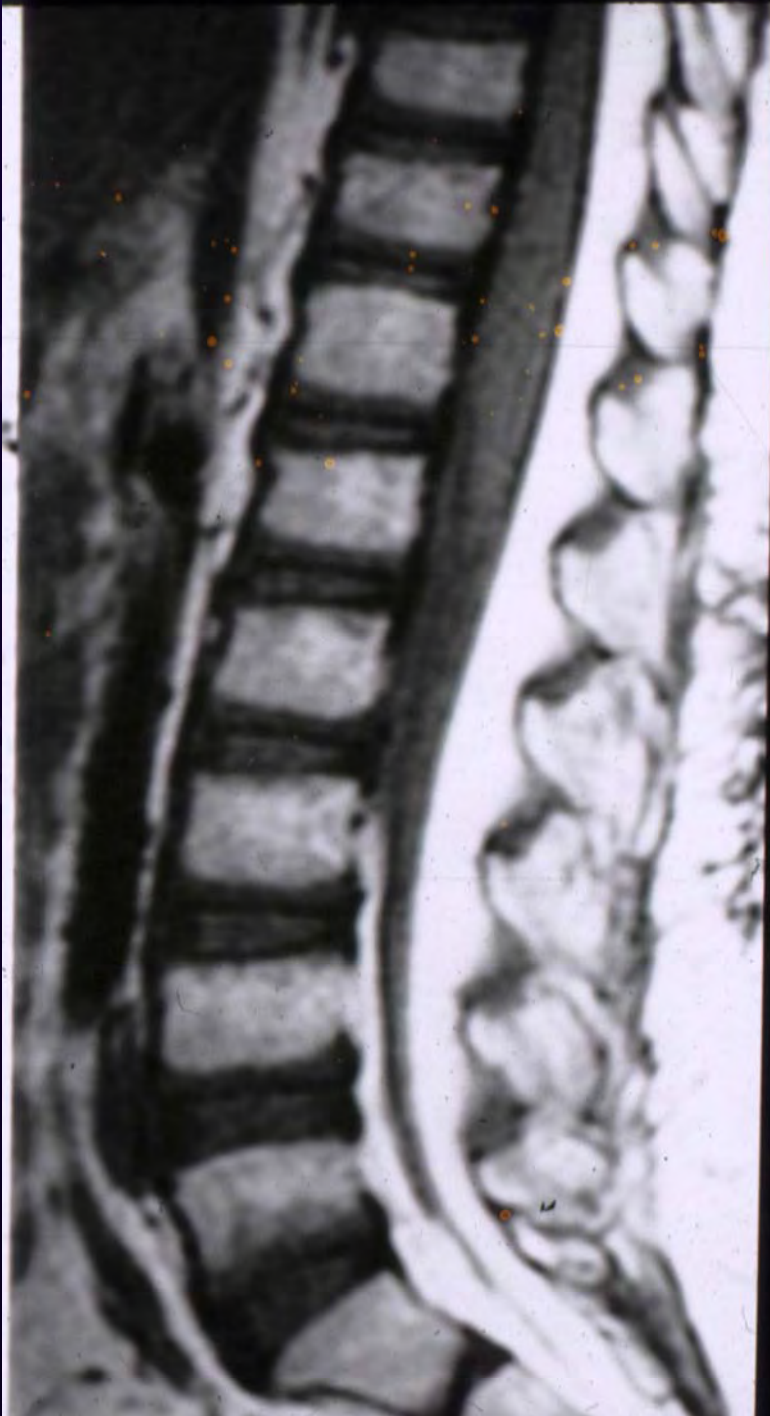# Stenosis

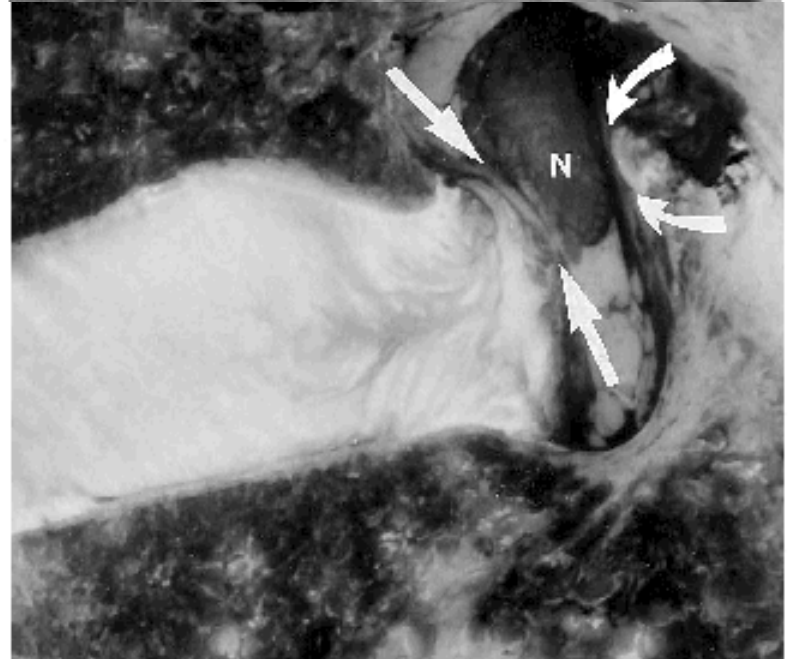
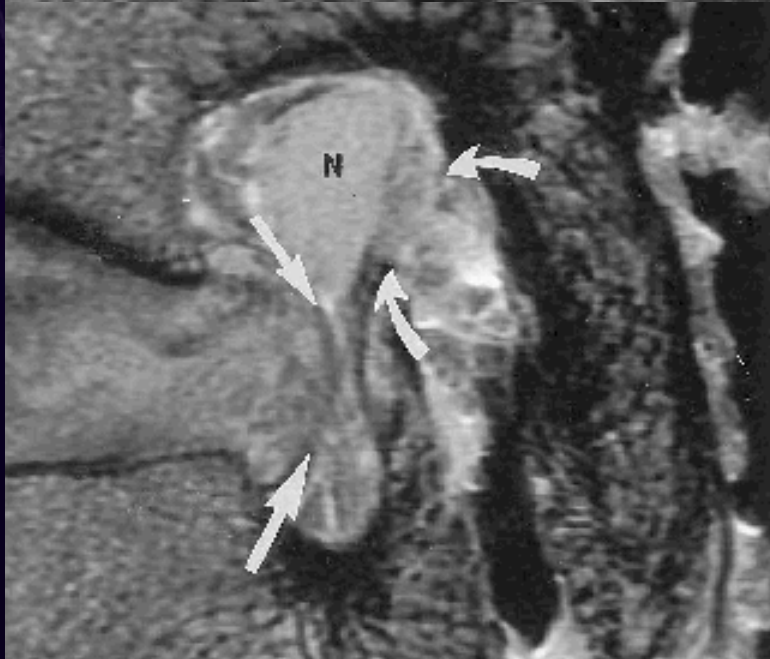
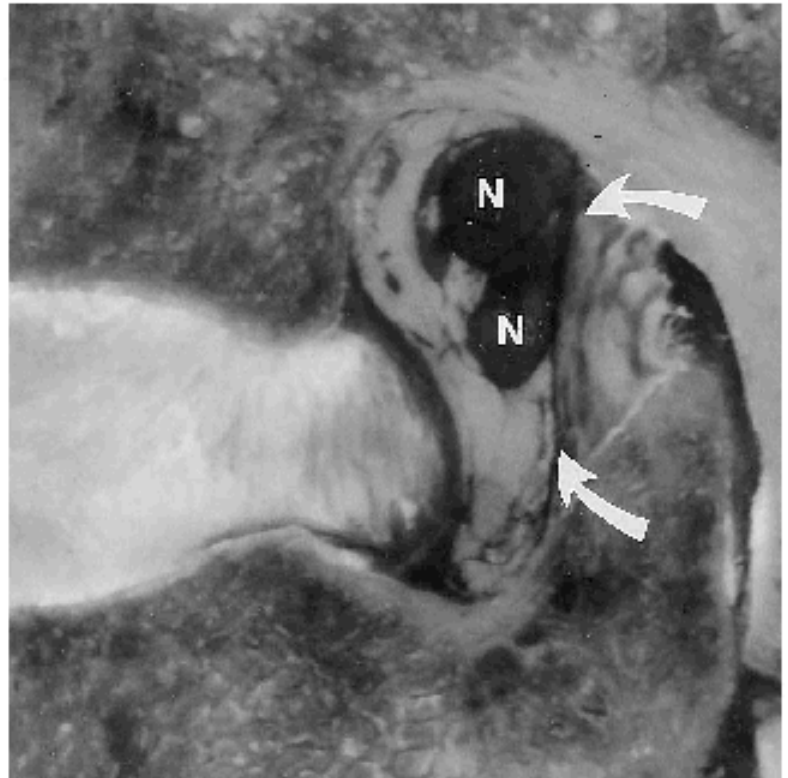
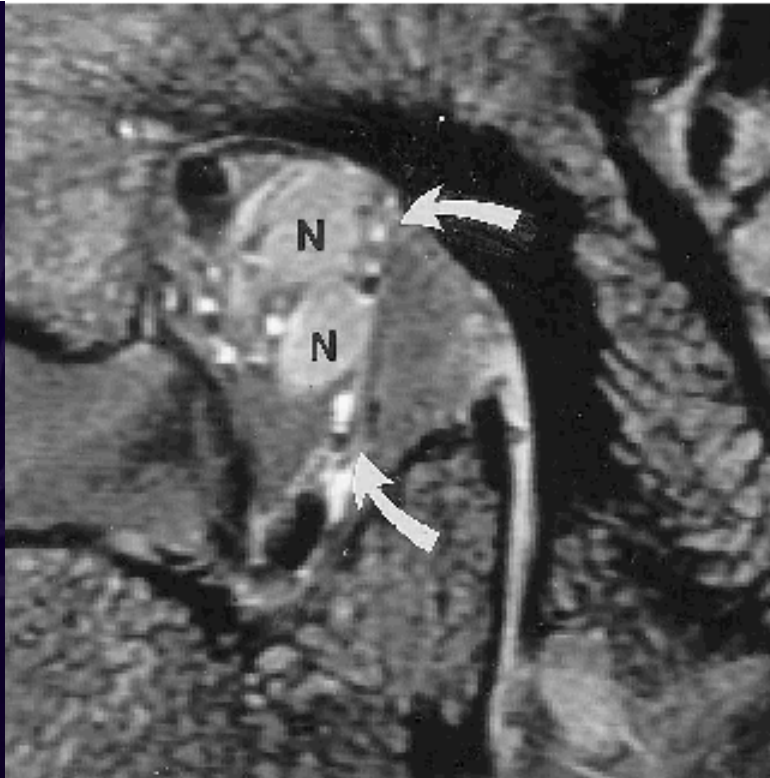- Reduction in diameter of spinal canal, lateral nerve canal or neural foramina
- Central stenosis - hypertrophy of facet, ligamentum flavum, disc, spondylolisthesis
- Lateral stenosis - common cause of radiculopathy, posterolateral disc, hypertrophy of superior articular process

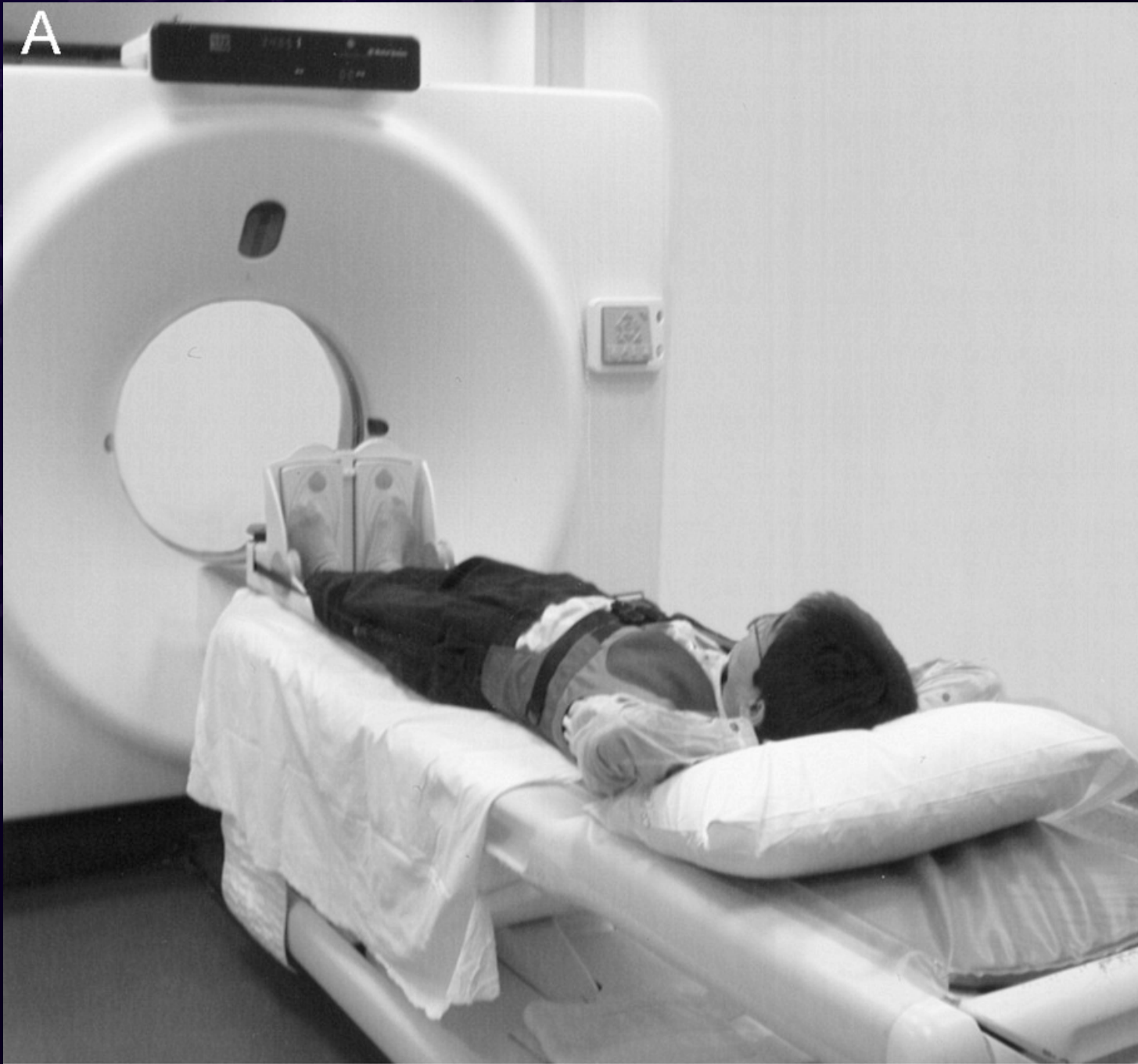






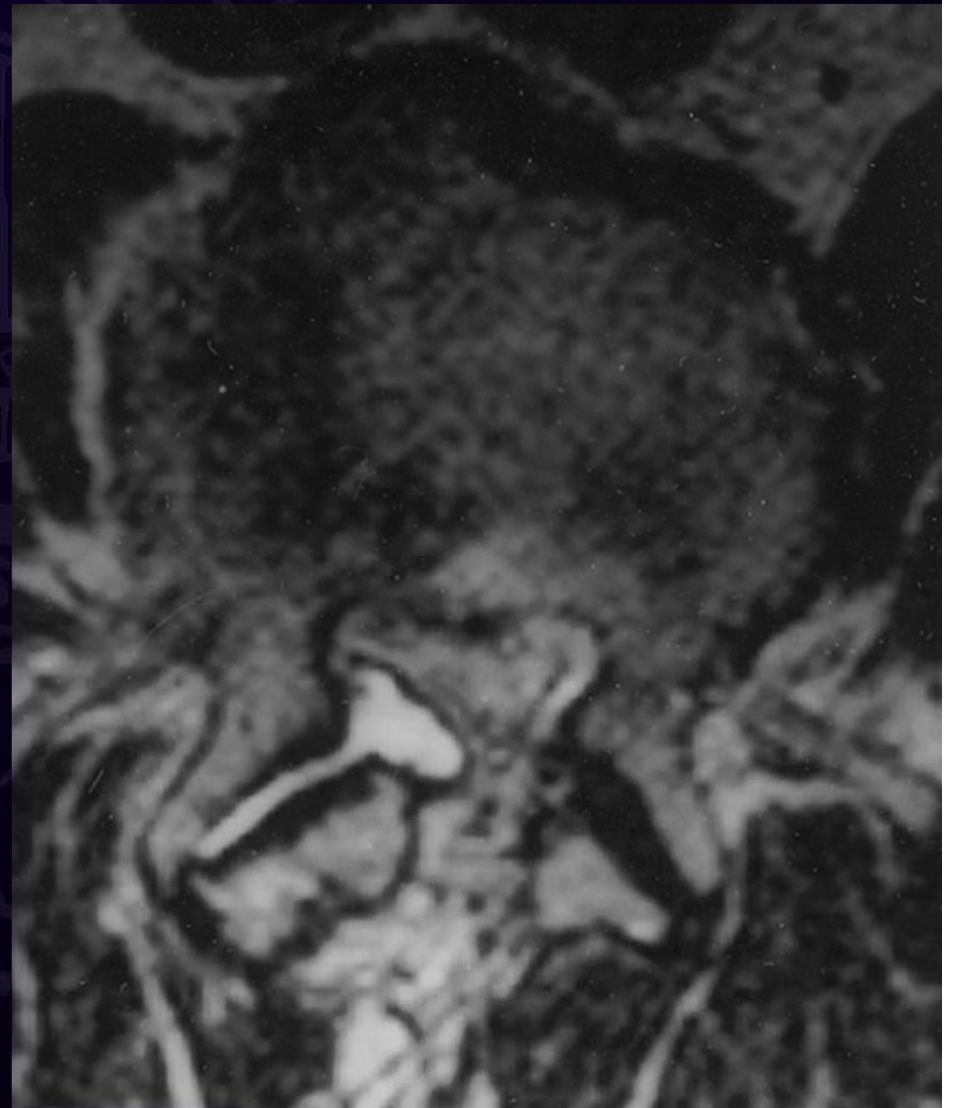
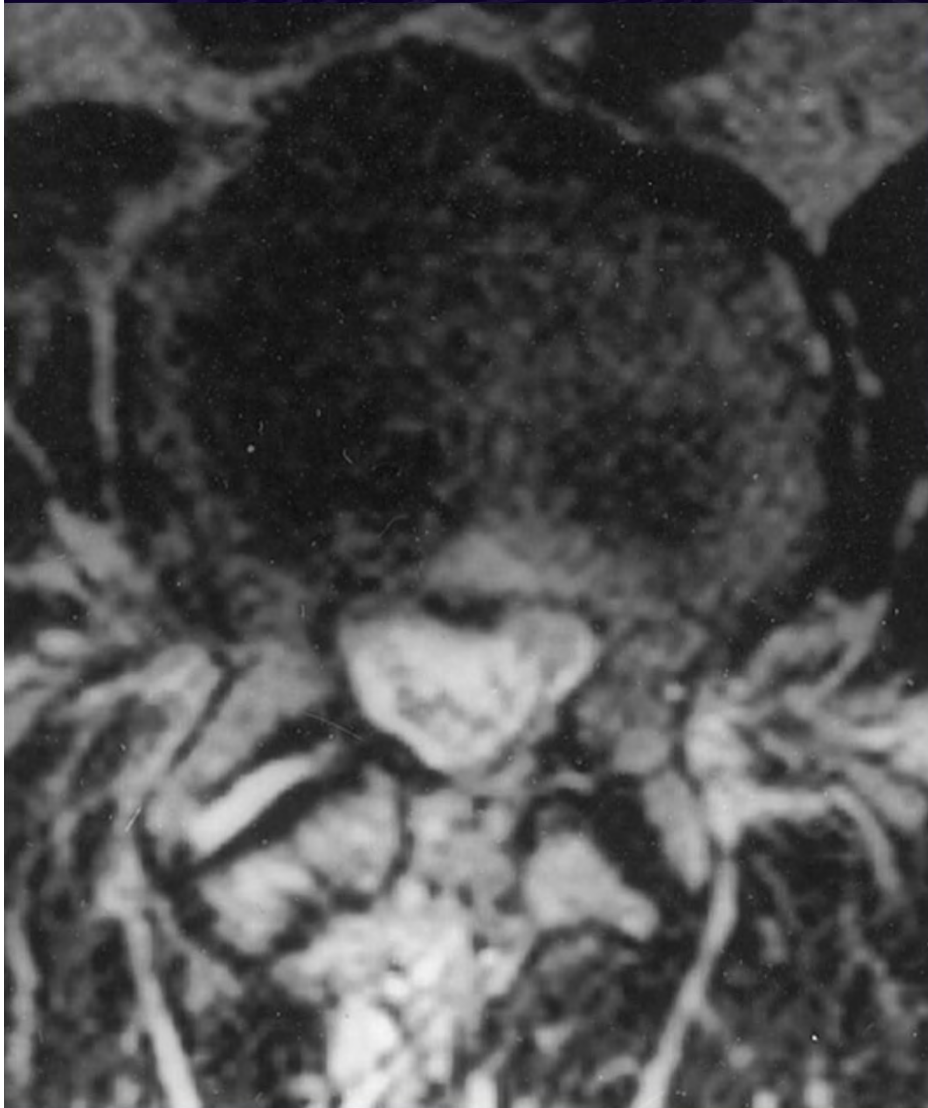




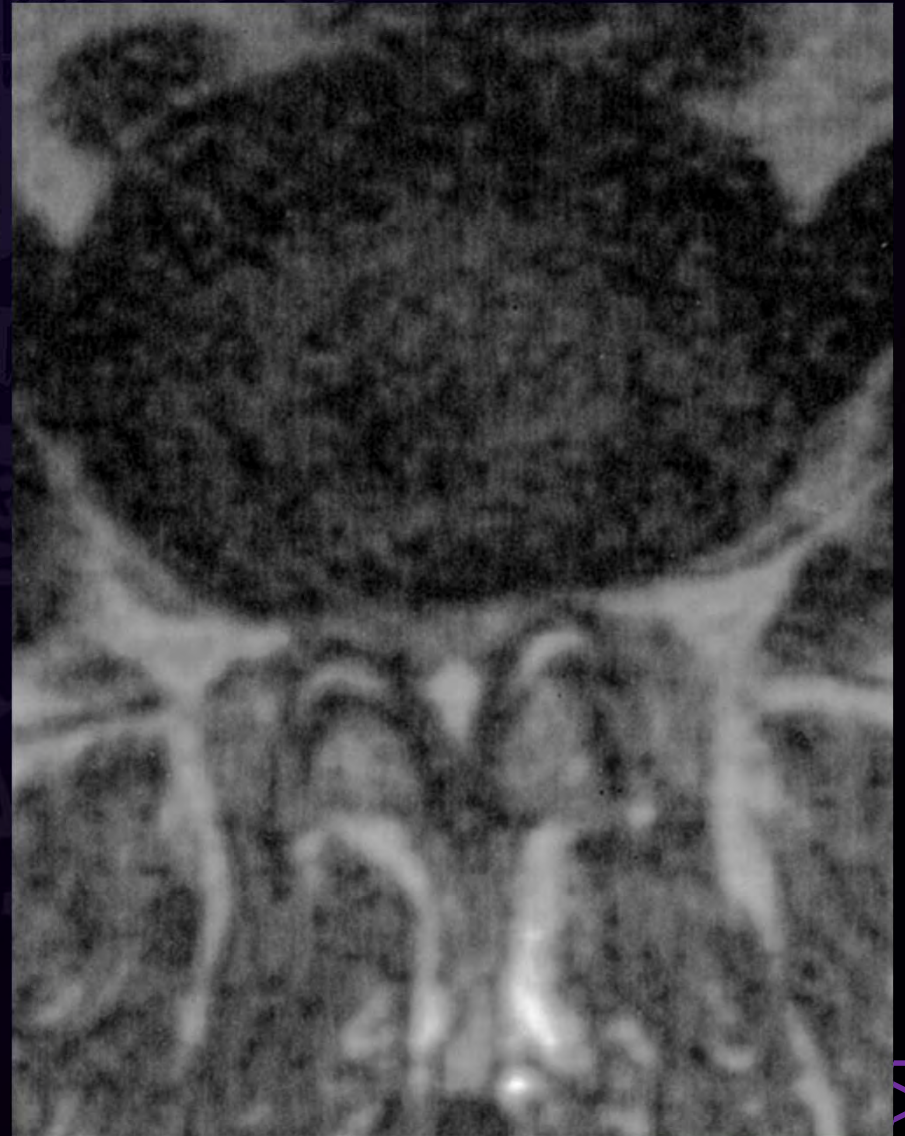


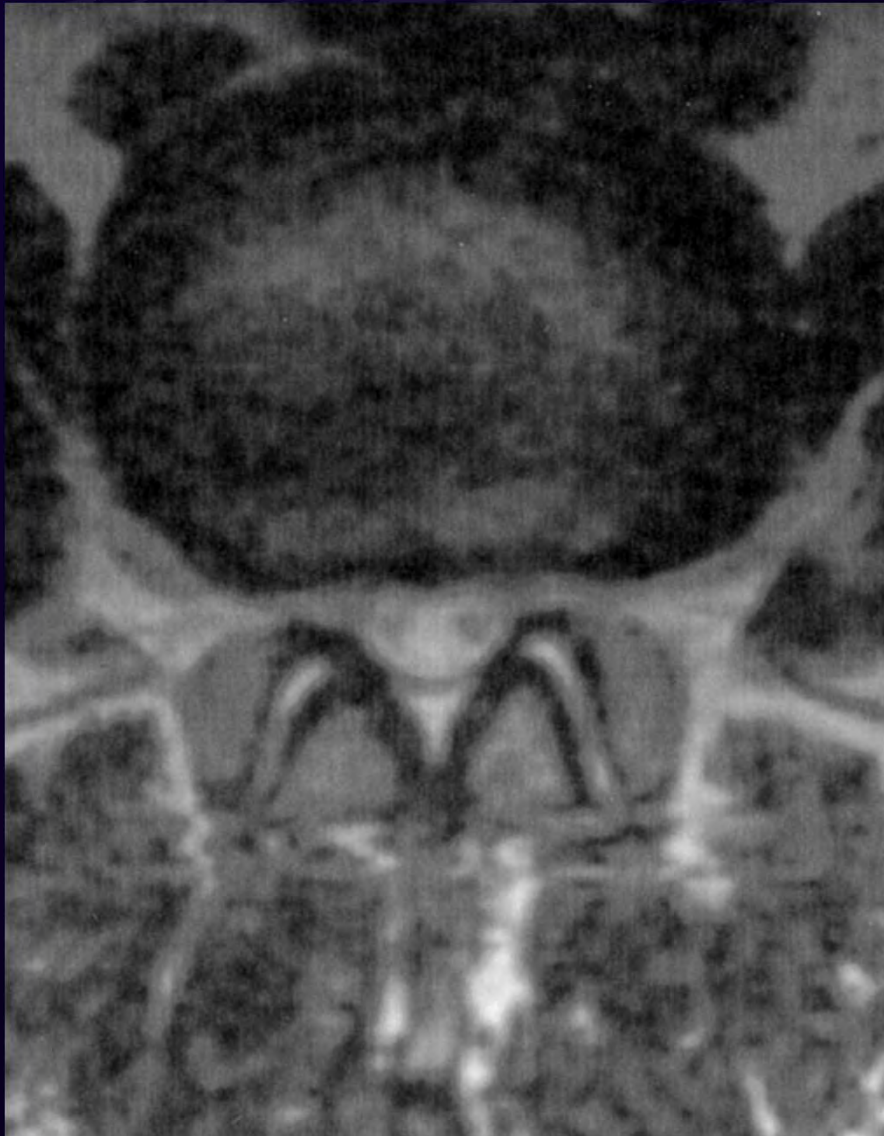# 77 yo L4 radiculopathy





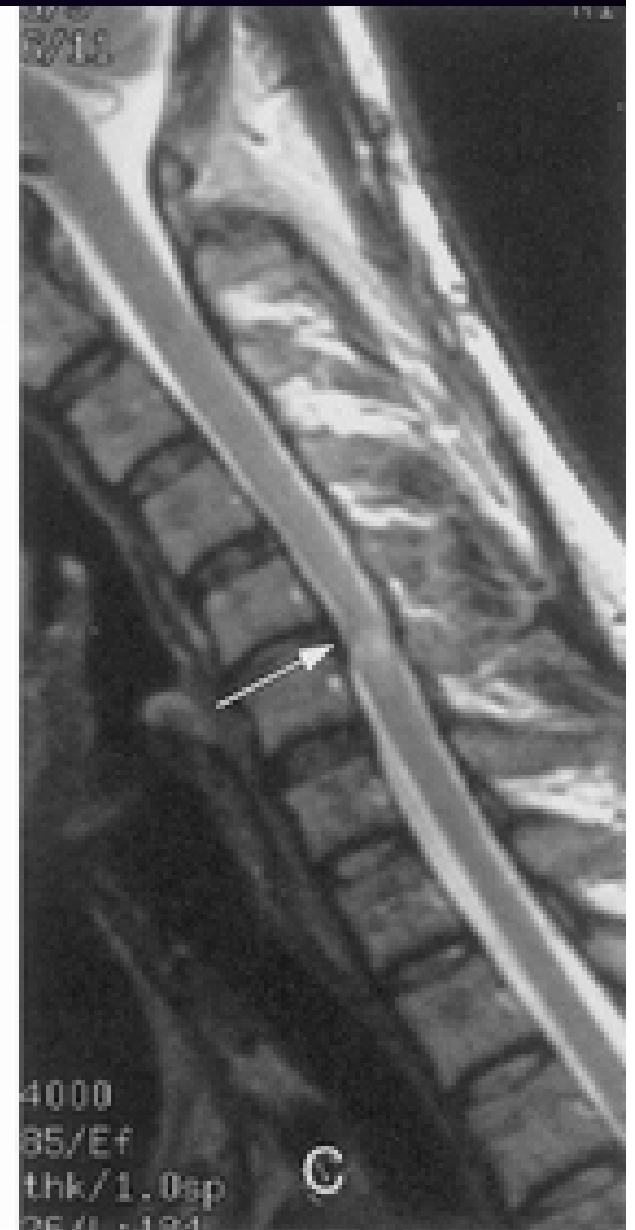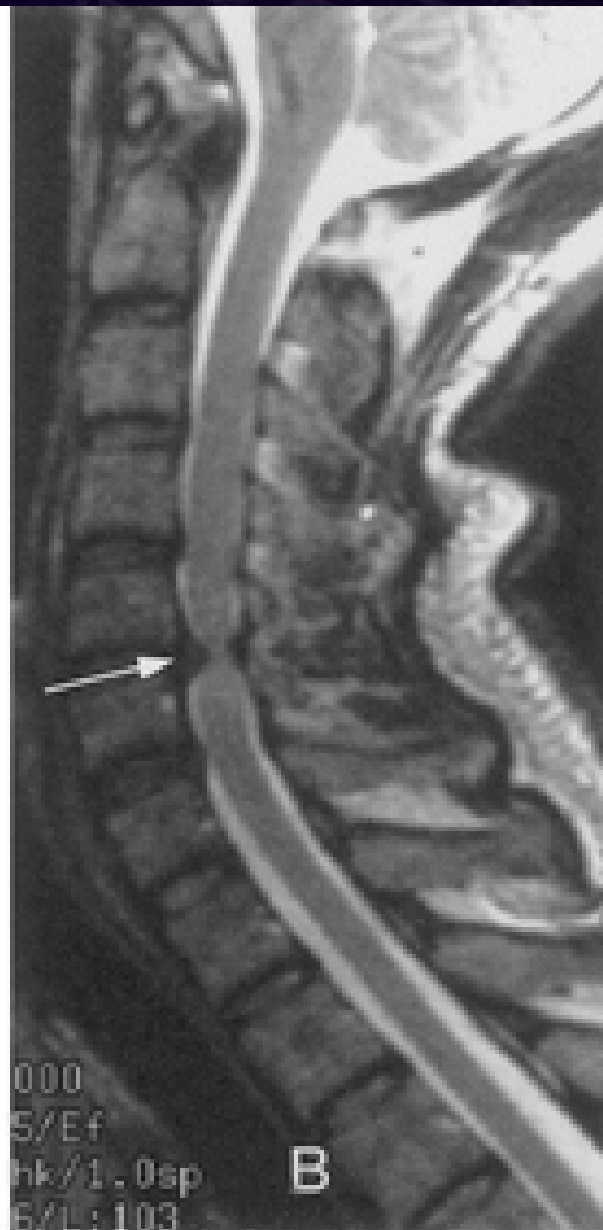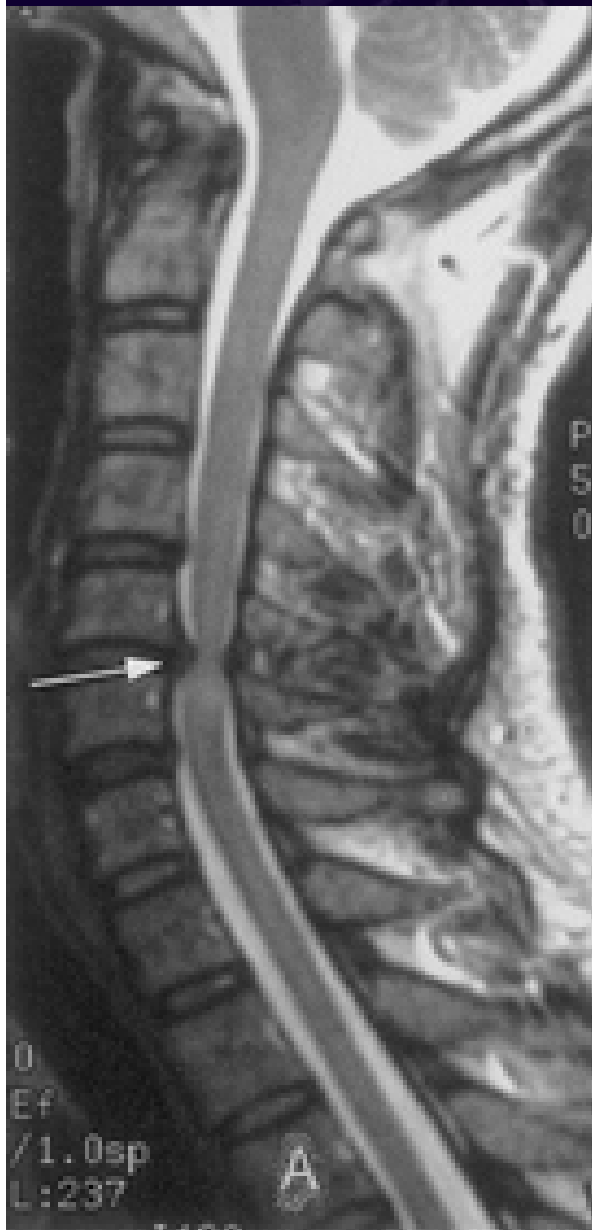# 56 yo bilateral sciatica claudication

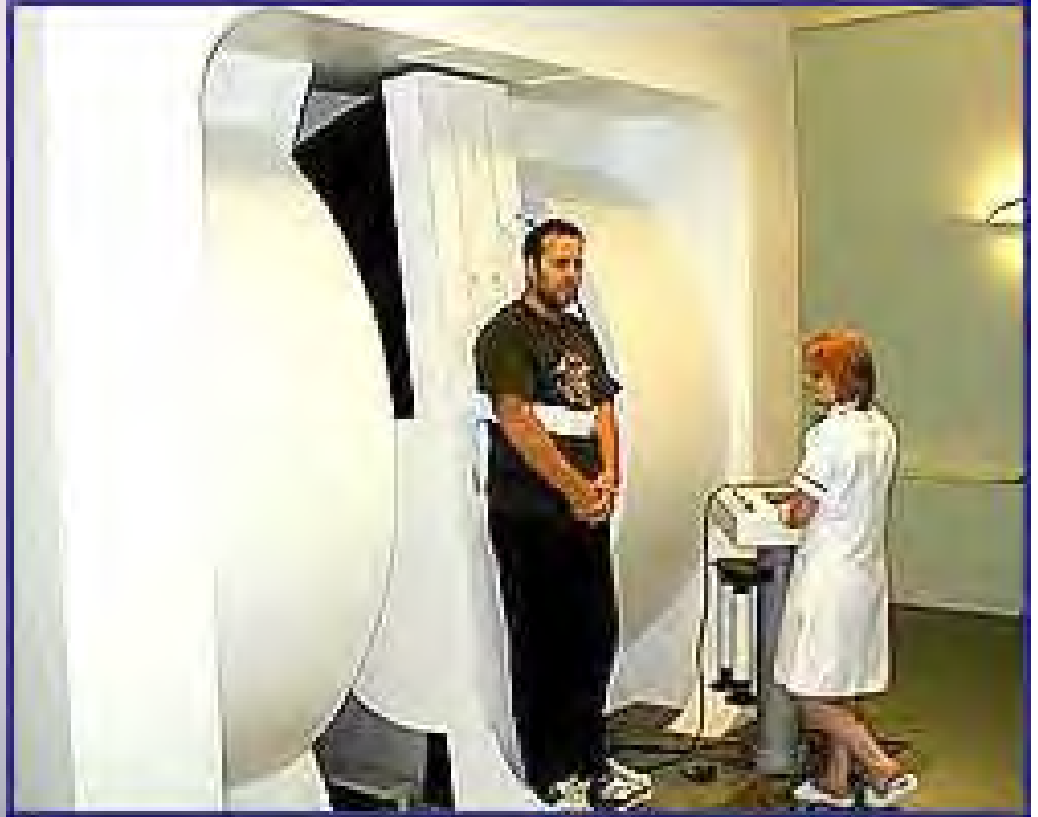

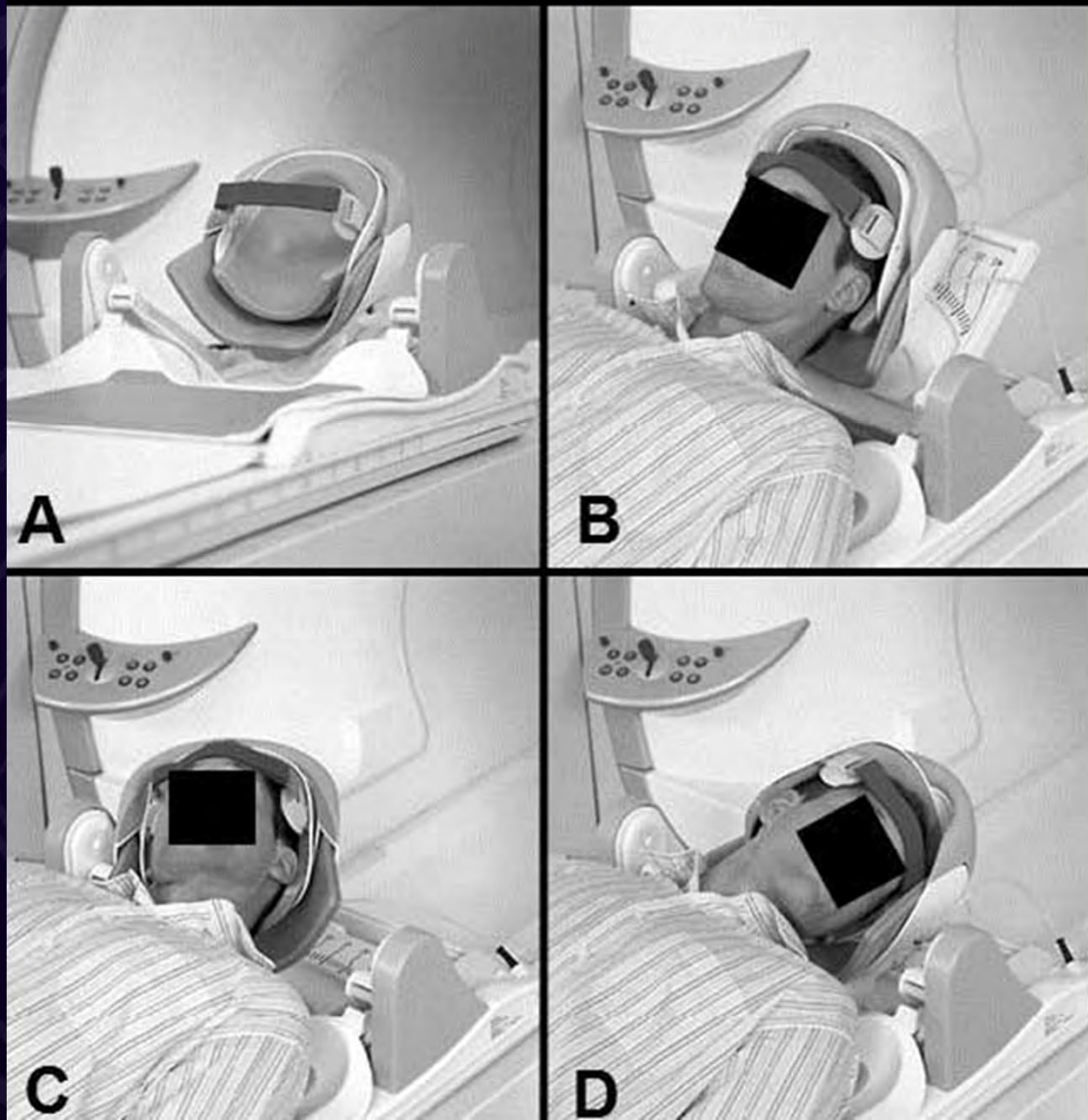
neutral

extension

flexion

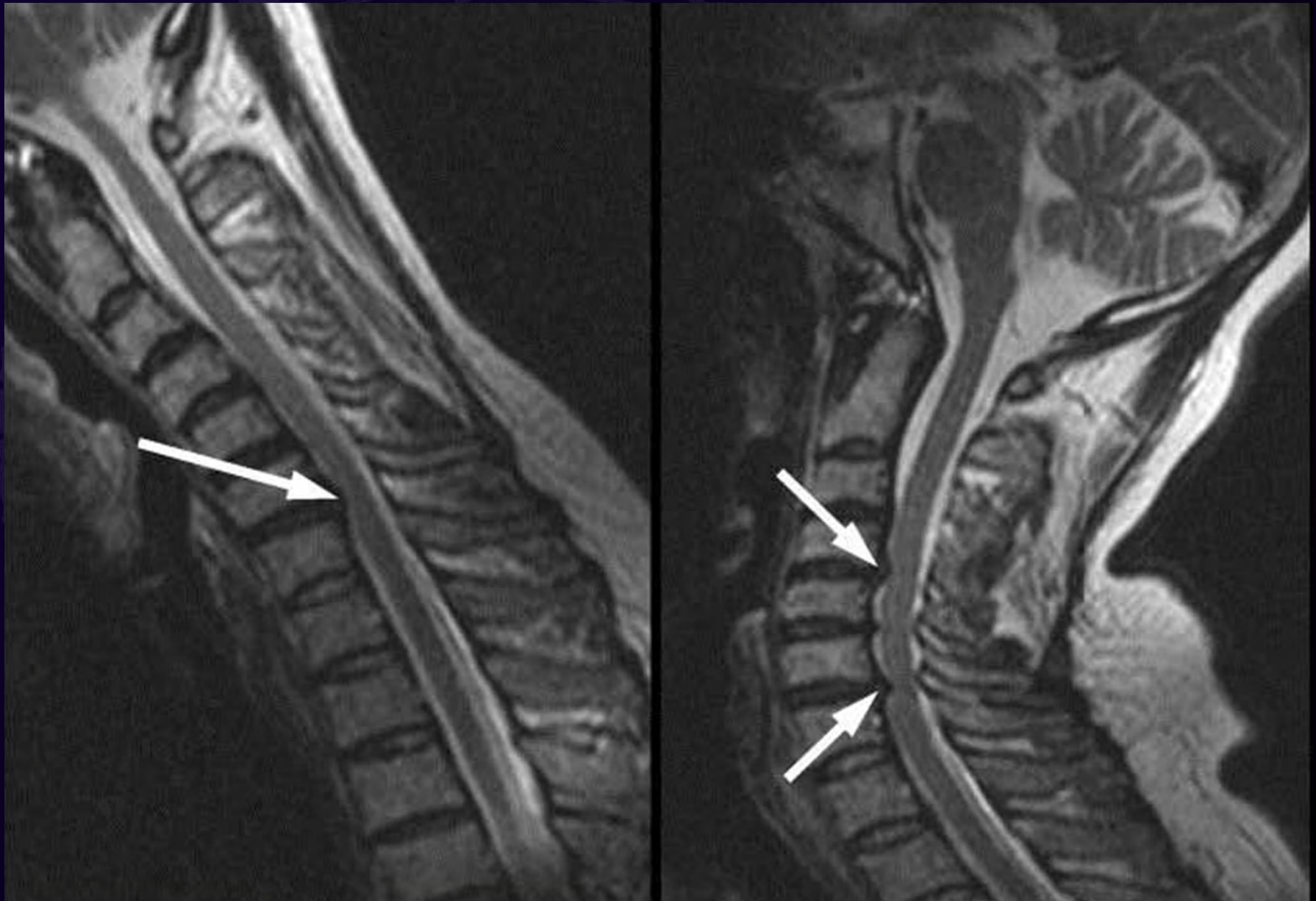






Neuroimaging Clin N Am. 2007 February ; 17(1): 117–136



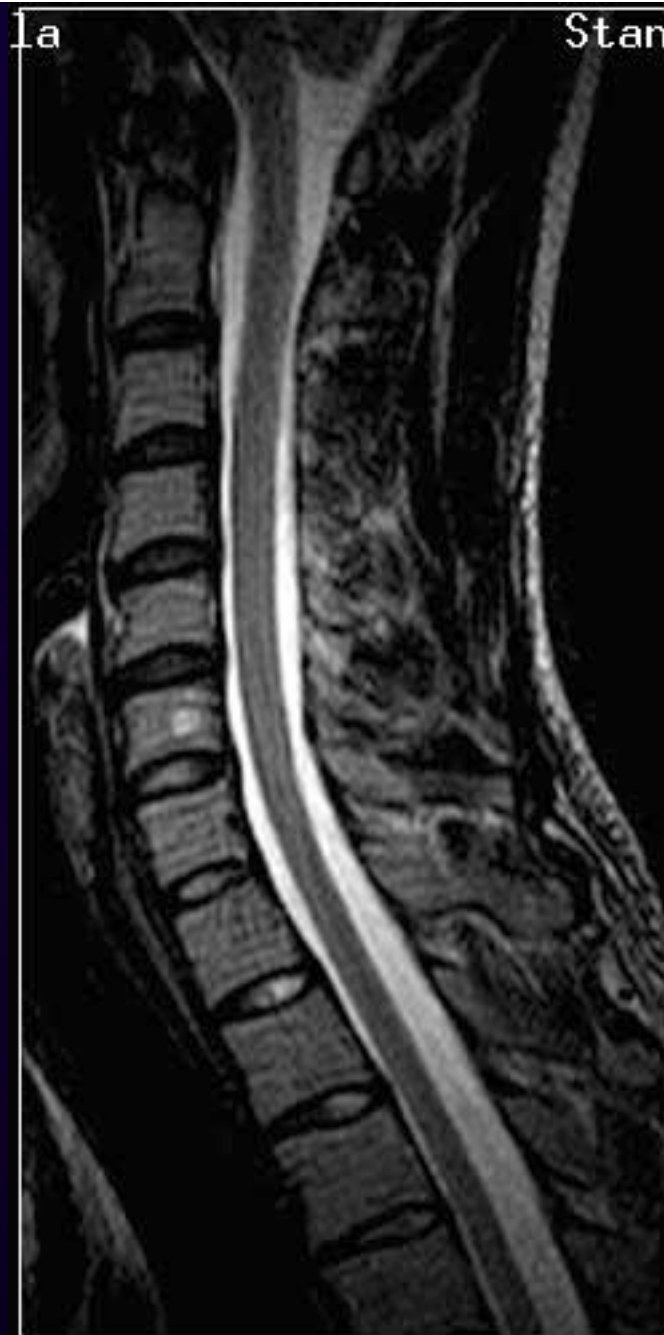

Neuroimaging Clin N Am. 2007 February ; 17(1): 117–136

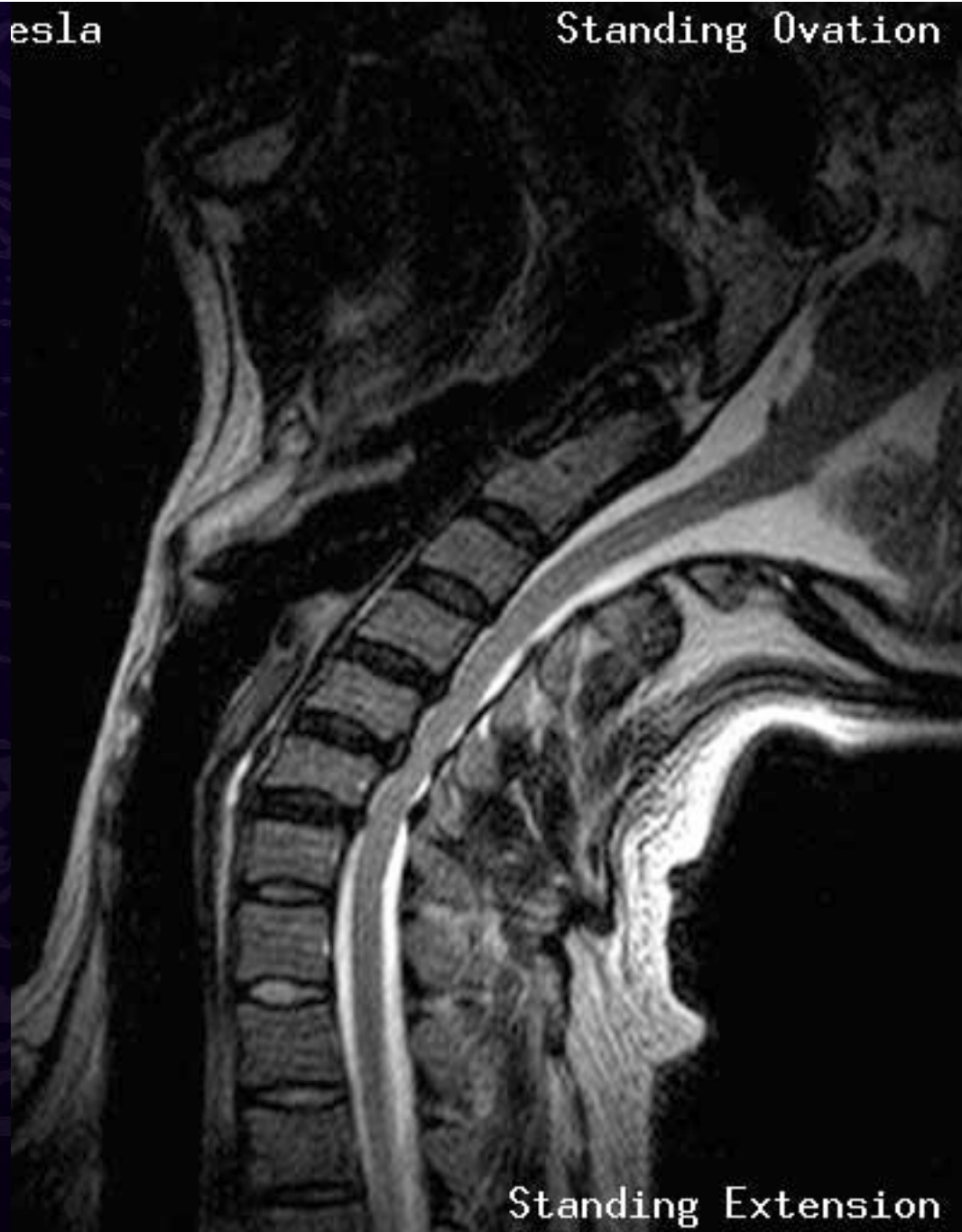

1a

Standing

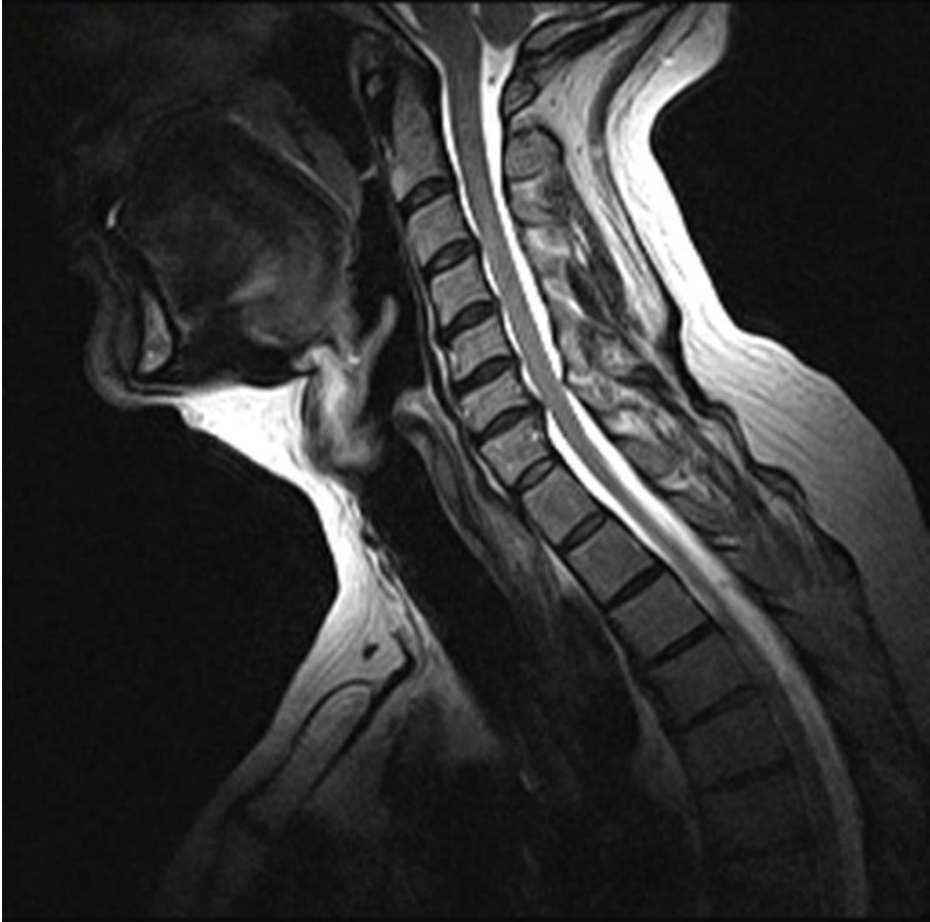


Standing Ovation

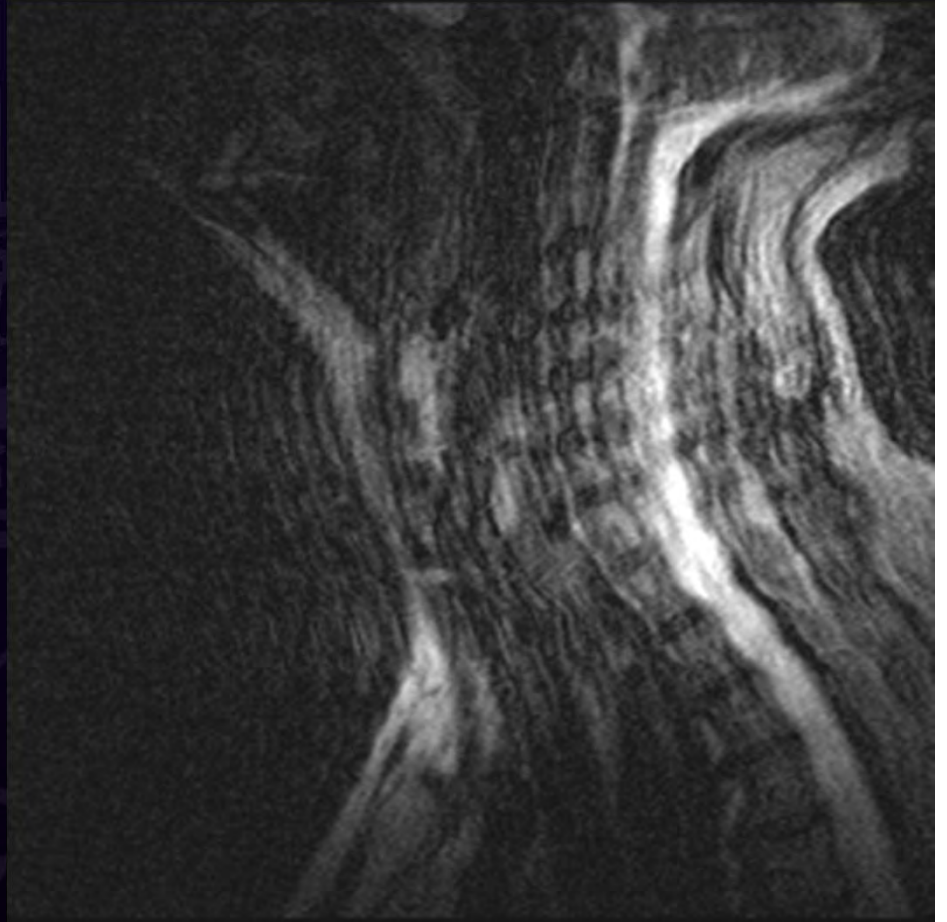


Standing Extension





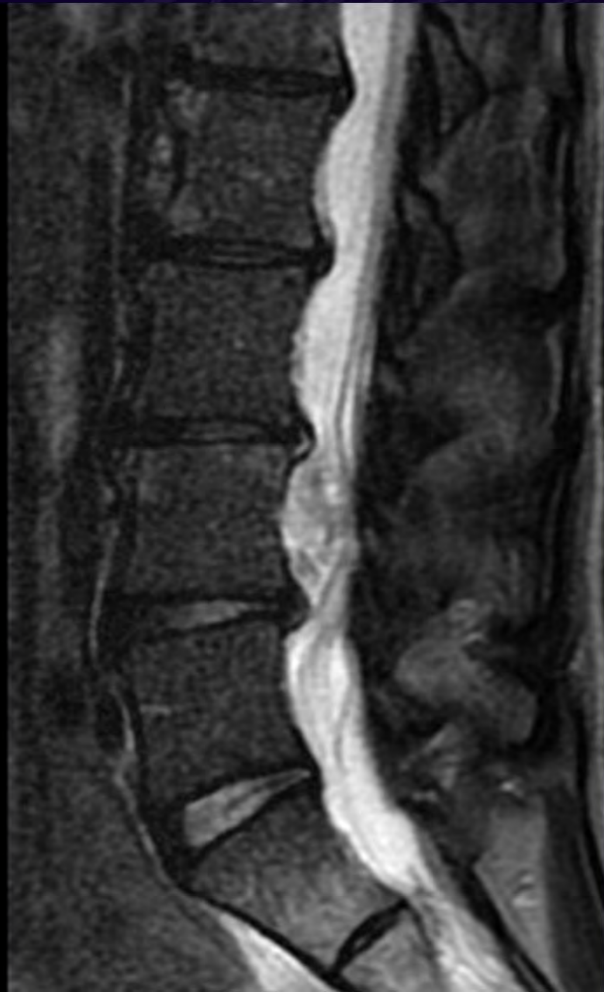neutral position



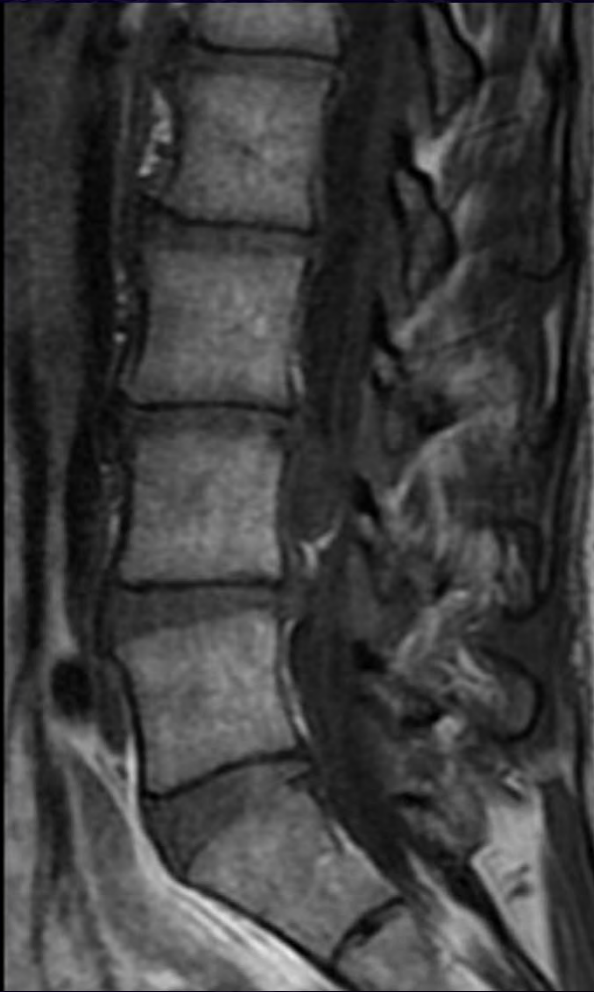painful extension



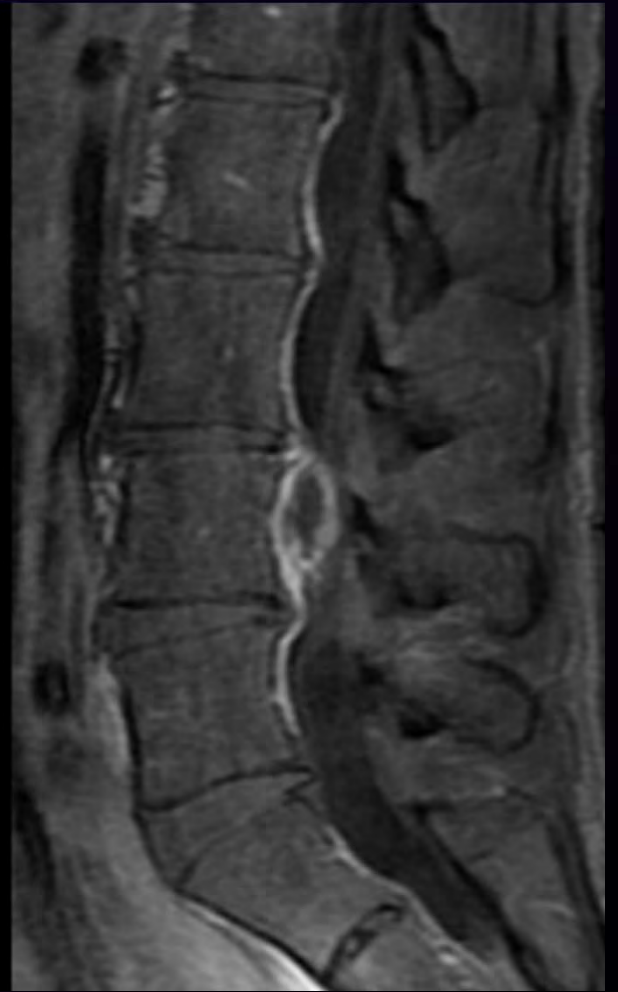
# 52 yo F R foot drop 2 weeks



T2



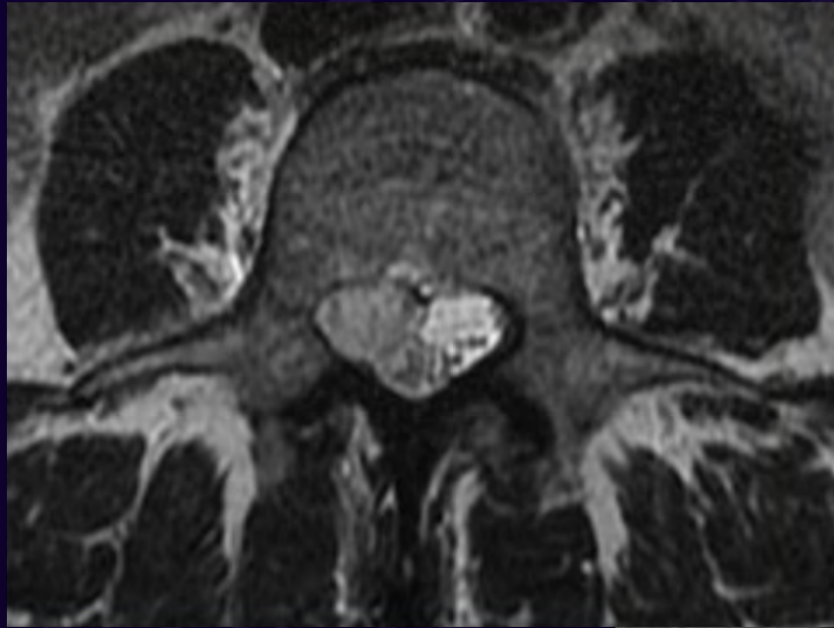T1



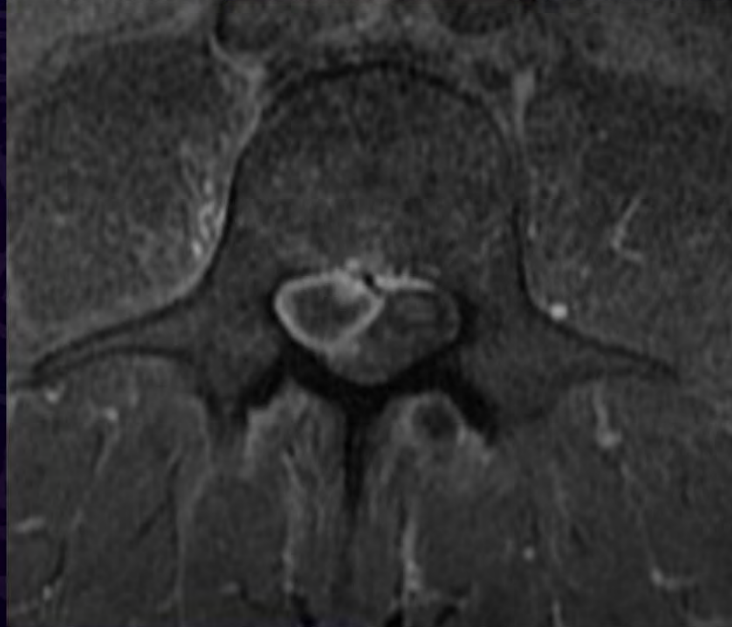
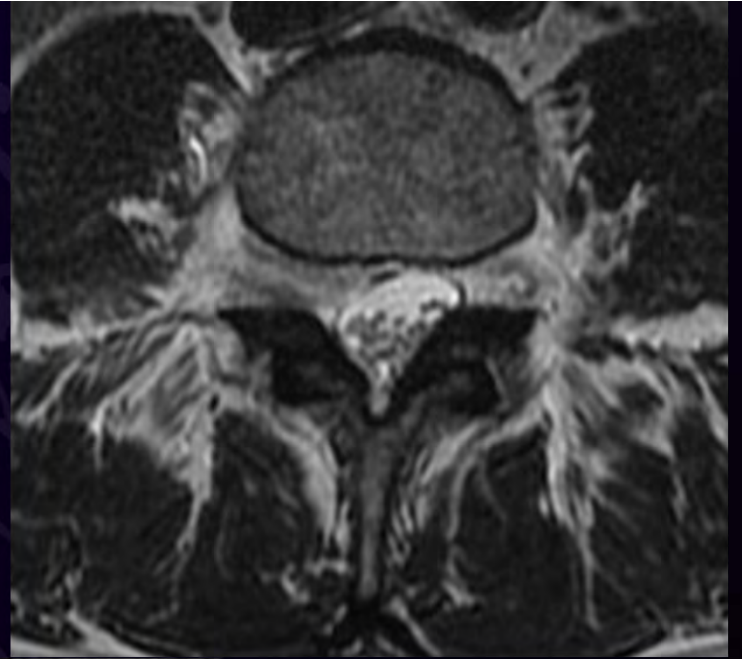
Gad







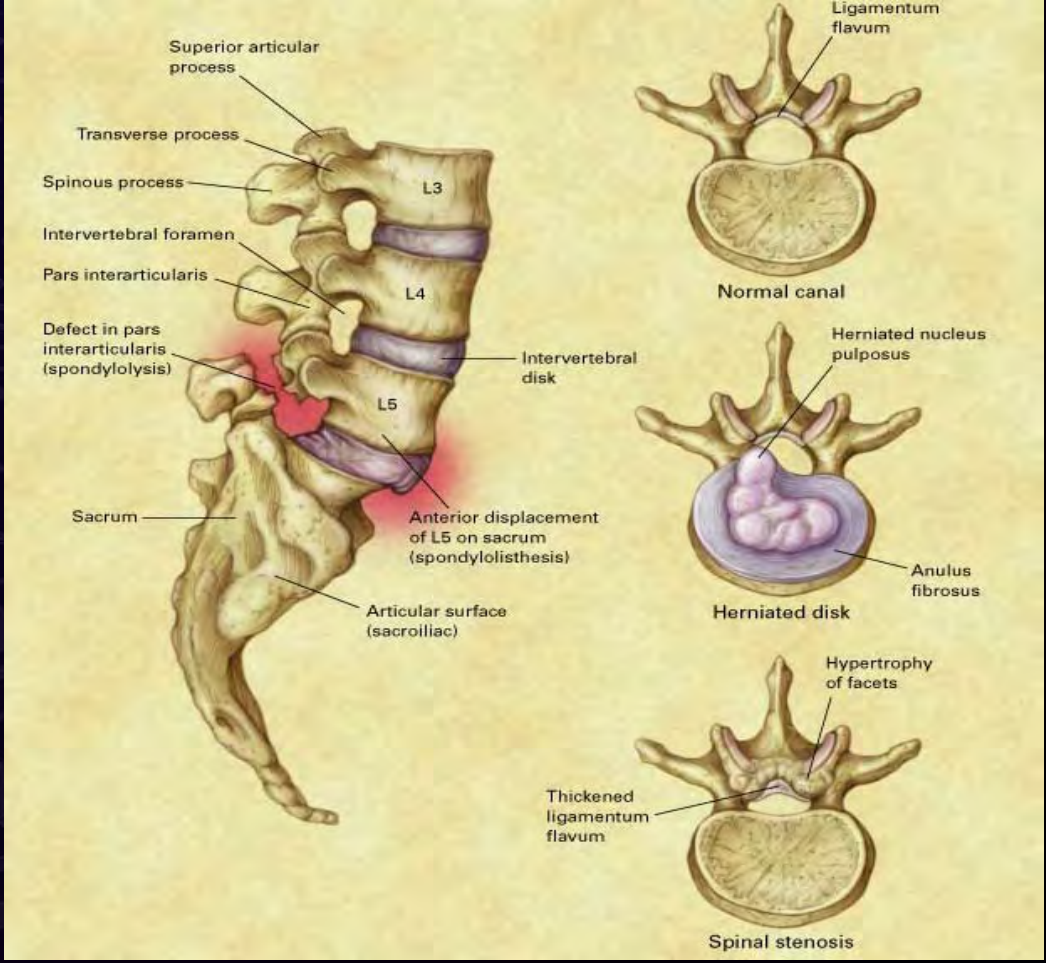
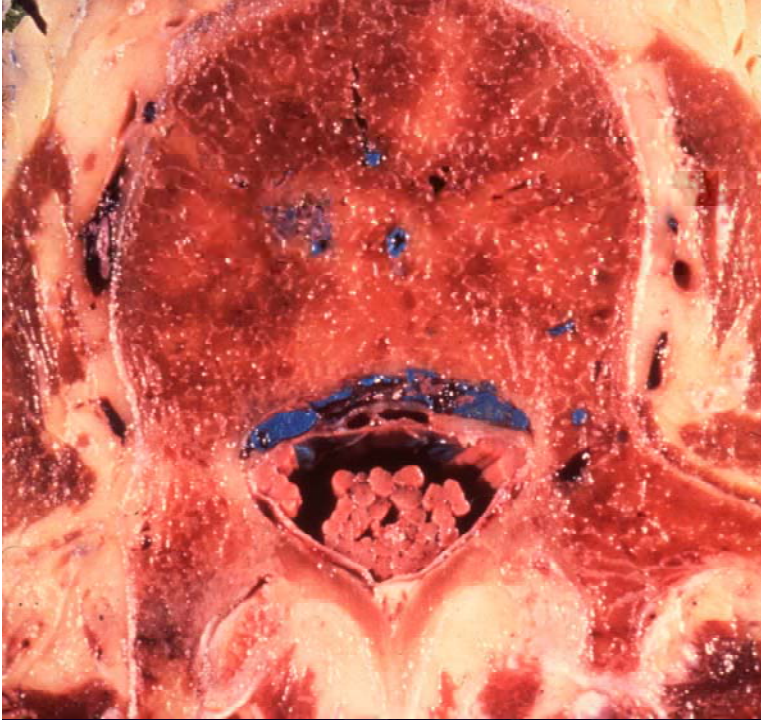
Axial  
T2



Gad



# Back Pain



Deyo et al NEJM 2001



# Spine Procedures

- Nerve blocks
- Facet blocks, medial branch blocks, ablation
- Extrapapinal injections

# Nerve blocks

- 641 pts – 23.4 mth f/u
- Disc – 286; stenosis 141; listhesis 136; FBS 24; pars 22; scoli 18; foraminal narrowing 14
- Obviated surgery 331 (52%) pts



# Rationale

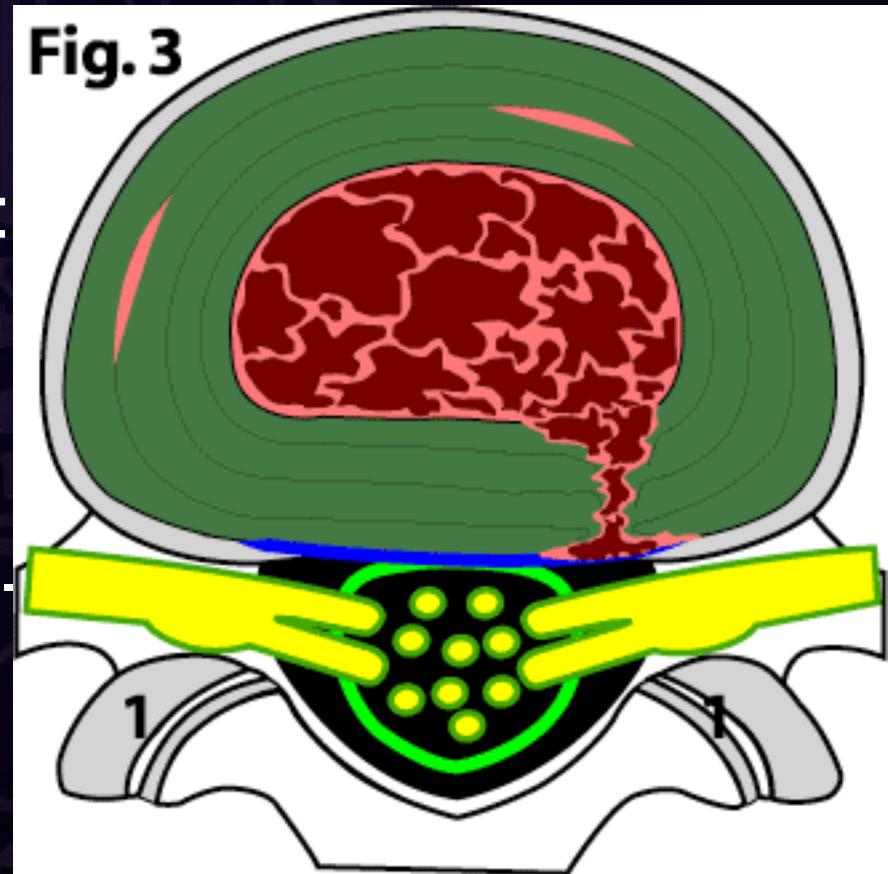
- Diagnostic and therapeutic potential
- Minimally invasive
- Can reproduce pain
- Can guide surgeon in patients with multilevel disease

# Mechanism

Autoimmune reaction -  
inflammation -  
macrophages

Non-immune inflammation:

- Histiocytes, fibroblasts, chondrocytes
- Cytokines (interleukin-1 alpha, interleukin 6, TNF-alpha)
- Phospholipase A2, prostaglandin E2, leukotrienes



D. Gillard

# What was injected in the first reported epidural injection?

- 1. Saline
- 2. Cocaine
- 3. Steroid
- 4. Lidocaine

# Epidural Injection History

- JA Sicard – radiologist 1901
- F Cathelin – urologist 1901 (a week later)
- G Caussade P Queste – 1909 – sciatica
- E Pages – 1921 – lumbar anesthesia

Singh V Pain Physician 2002 5(2)133-148



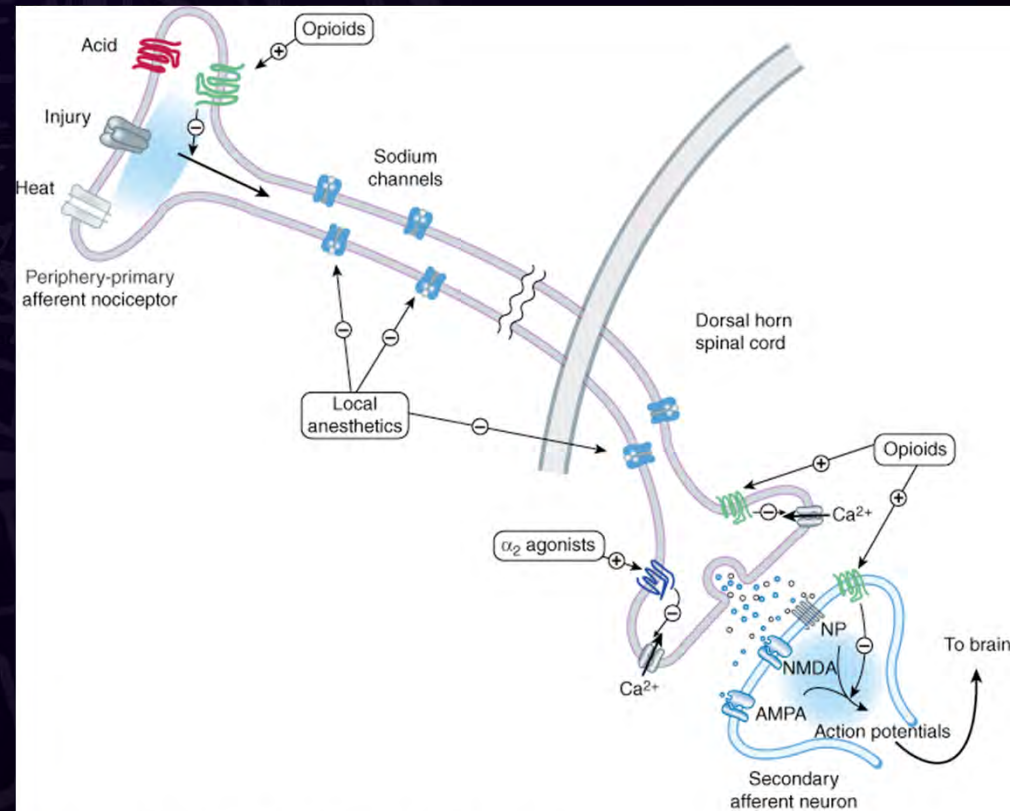


# Medications

- Radiocontrast agents
- Local anesthetics
- Corticosteroids
- Administered in smallest dose that will reliably produce desired effect - increased total dose/vlm should not be used to compensate for inadequate injection technique

# Local anesthetics

- Reversibly interrupts nerve impulse conduction - blocks sodium channels internal neuronal membranes - inhibiting sodium permeability necessary for action potential propagation



Source: Katzung BG, Masters SB, Trevor AJ: *Basic & Clinical Pharmacology*, 11th Edition: <http://www.accessmedicine.com>

Copyright © The McGraw-Hill Companies, Inc. All rights reserved.

Katzung BG Basic and Clinical Pharmacology



	%	onset	Duration (hr)	Max dose (mg)
lidocaine	0.5, 1 2, 4	fast	1-2	300
bupivacaine	0.25 0.50 0.75	slow	2-4	175

# Corticosteroids

- Mineralocorticoids
- Glucocorticoids:  
clinically used for  
pain
- Adrenal androgens



# Corticosteroids

Therapeutic mechanisms:

- Anti-inflammatory
- Direct neural membrane stabilization
- Modulation of peripheral nociceptor neurons and spinal cord dorsal horn cells



	1/2 life(hr)	Anti- inflamm	Salt retention
Hydrocortisone (hydrocortone)	8-12	1	1
Triamcinolone (kenalog-40)	12-36	5	0
Methylprednisolone (depo-medrol)	12-36	5	0.5
Dexamethasone (decadron phosphate)	36-72	25	0
Betamethasone (celestone soluspan)	36-72	25	0

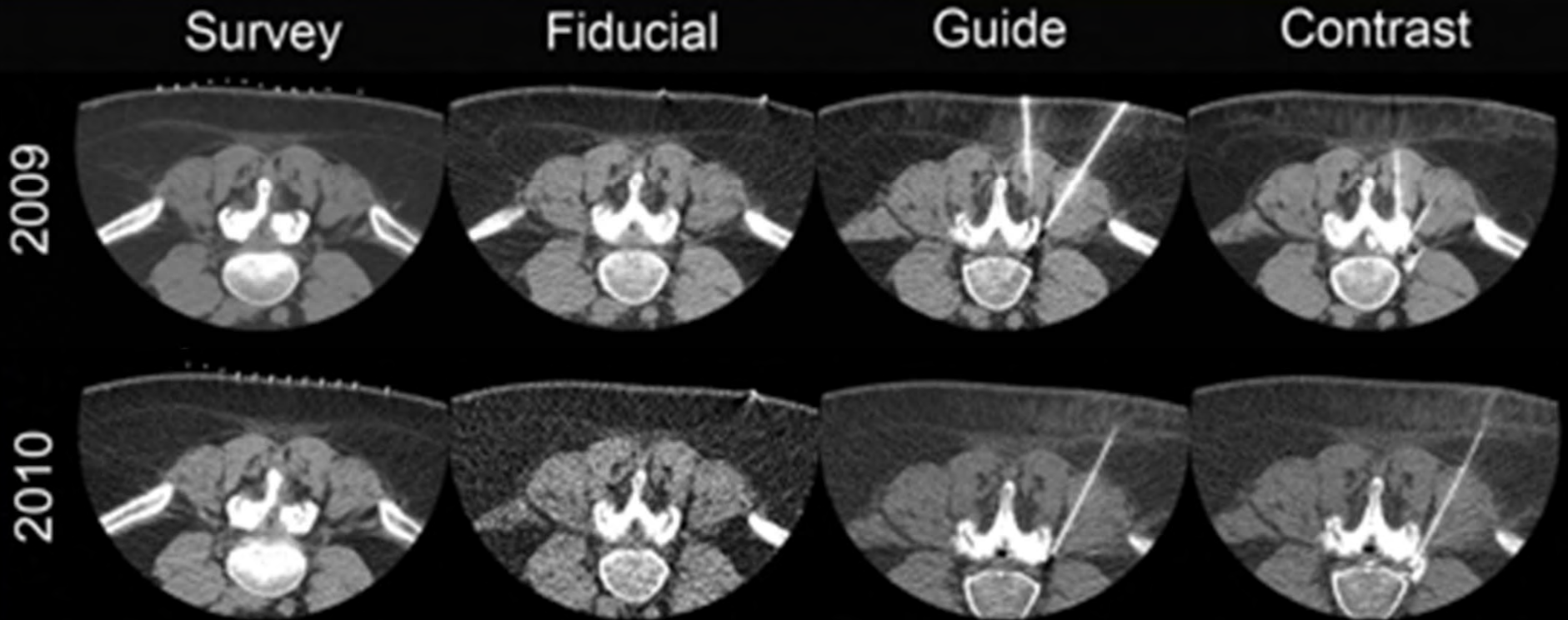


# Image-Guidance

- Precision and Comparison of CT, MRI and DL-controlled Interventions Exemplified by Lumbar Facet Infiltration: An Experimental Study. (Gronemeyer JJ et al. Biomed Tech 2000; 45:228-237)
- Value of CT Fluoroscopy for Lumbar Facet Blocks. (Meleka S et al. AJNR 2005; 26:1001-1003)



# CT dose reduction >90%

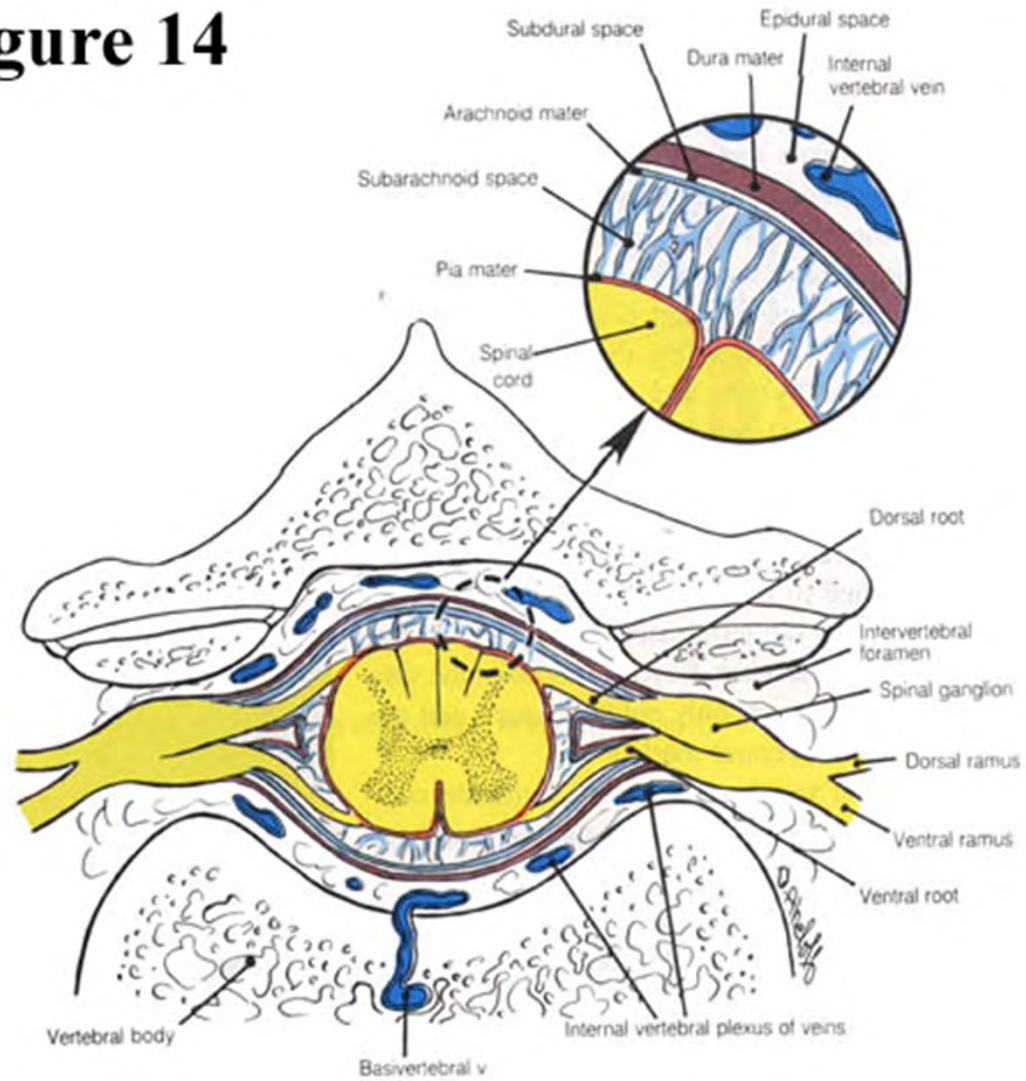


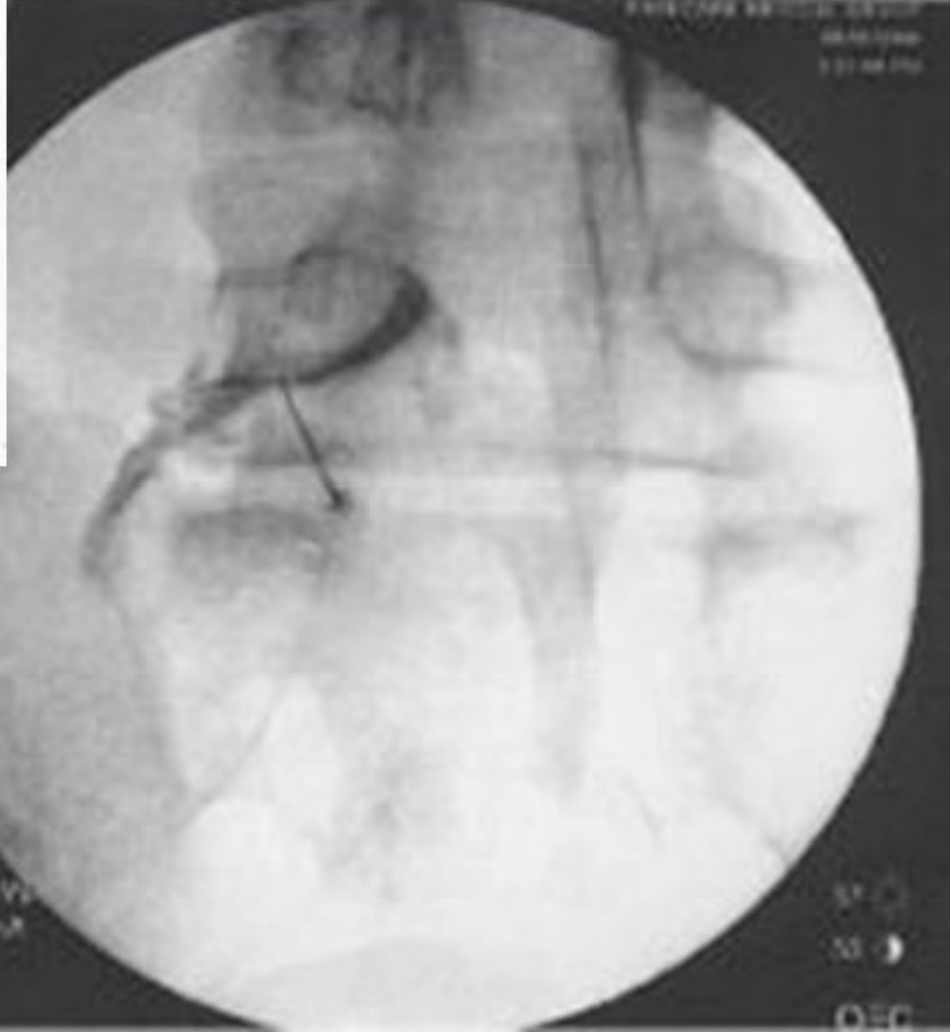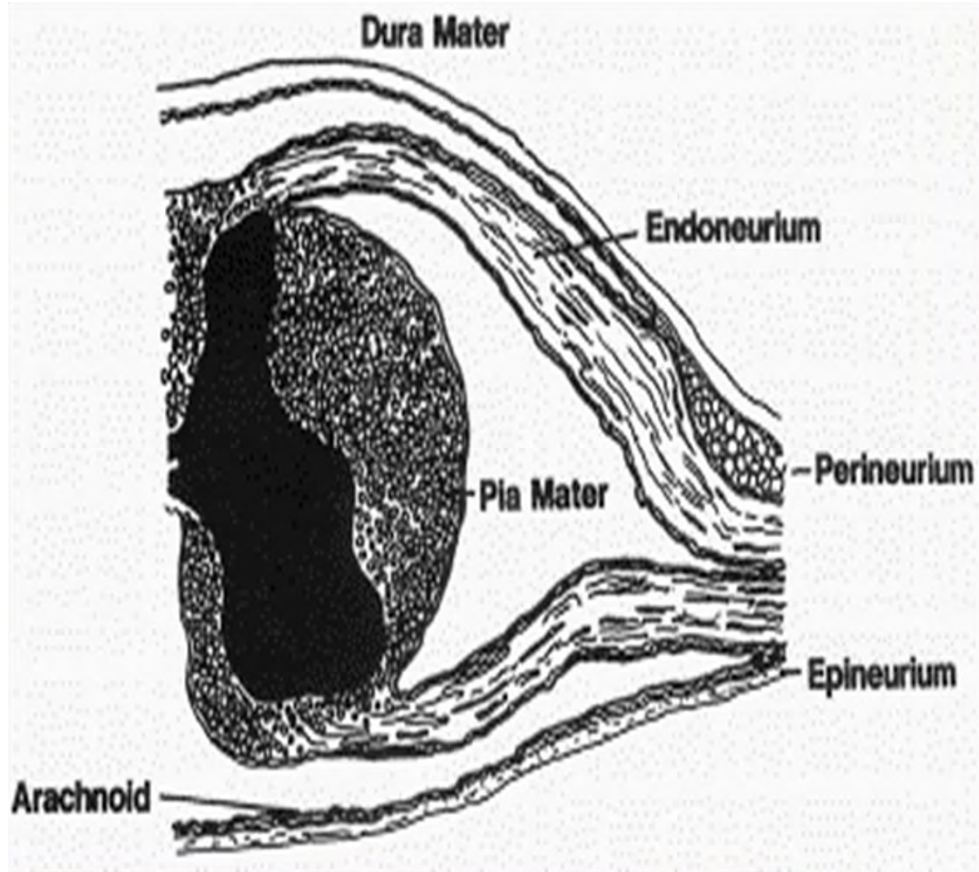
Shepherd T et al AJNR 2011



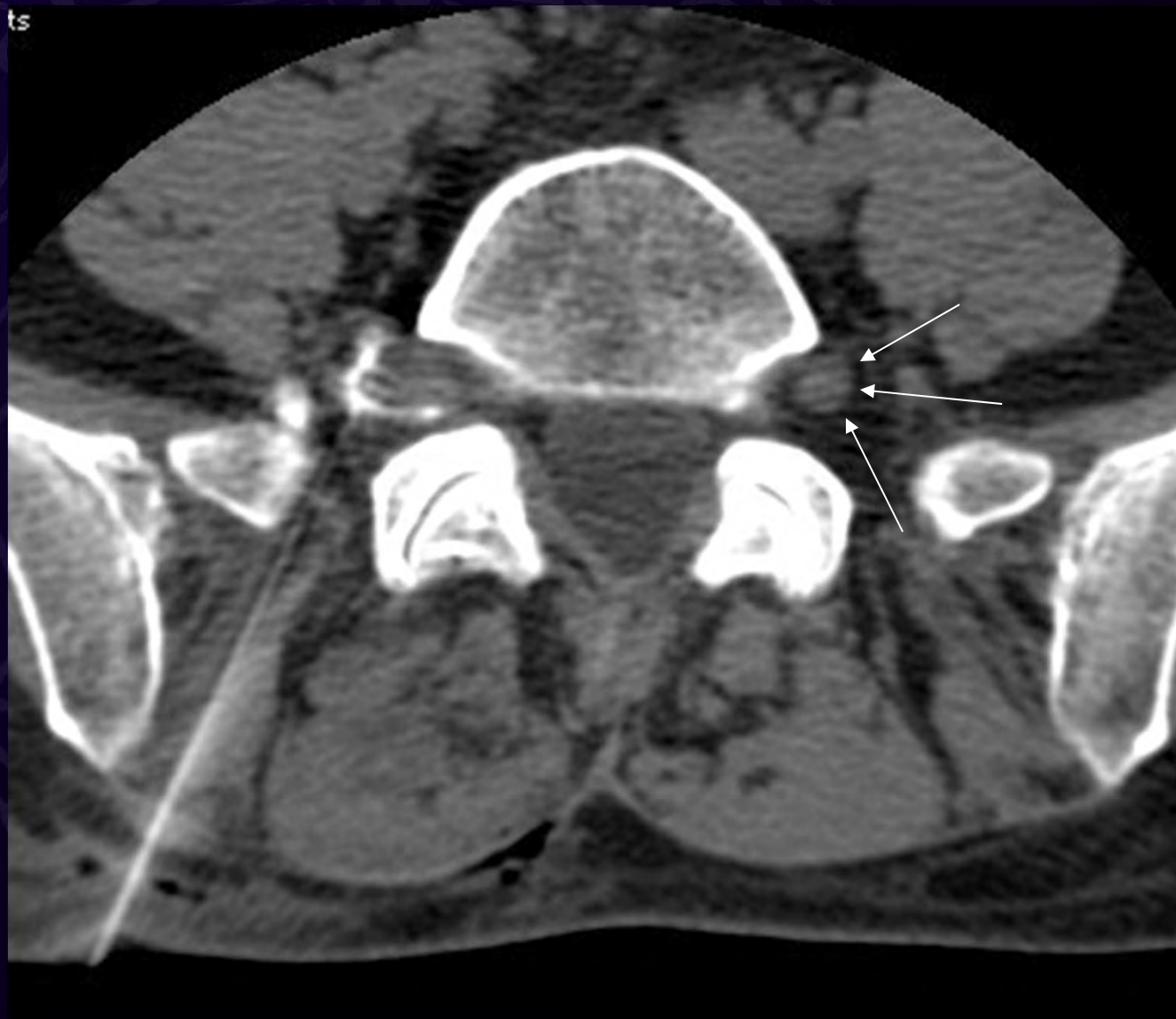


# Figure 14

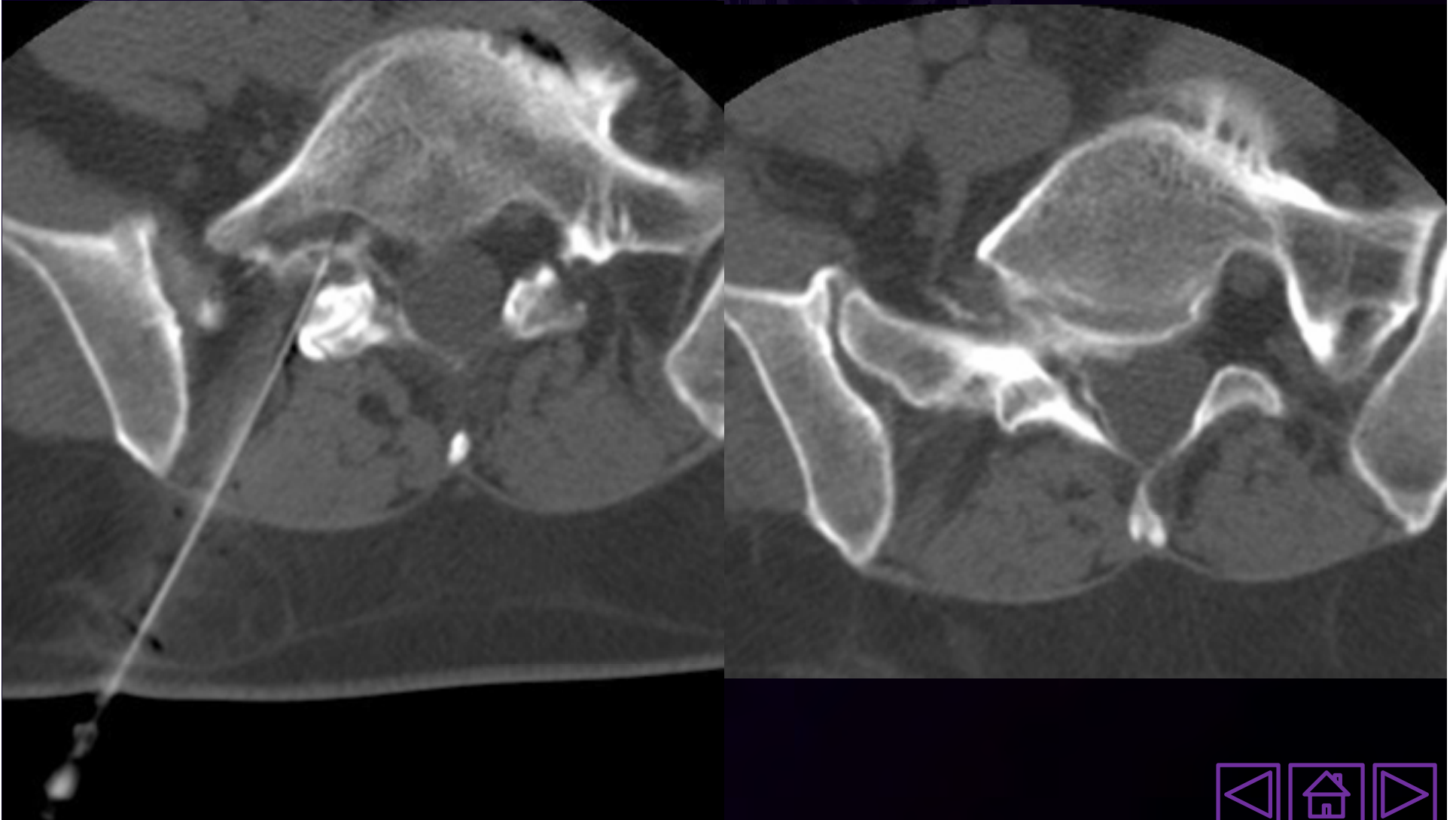


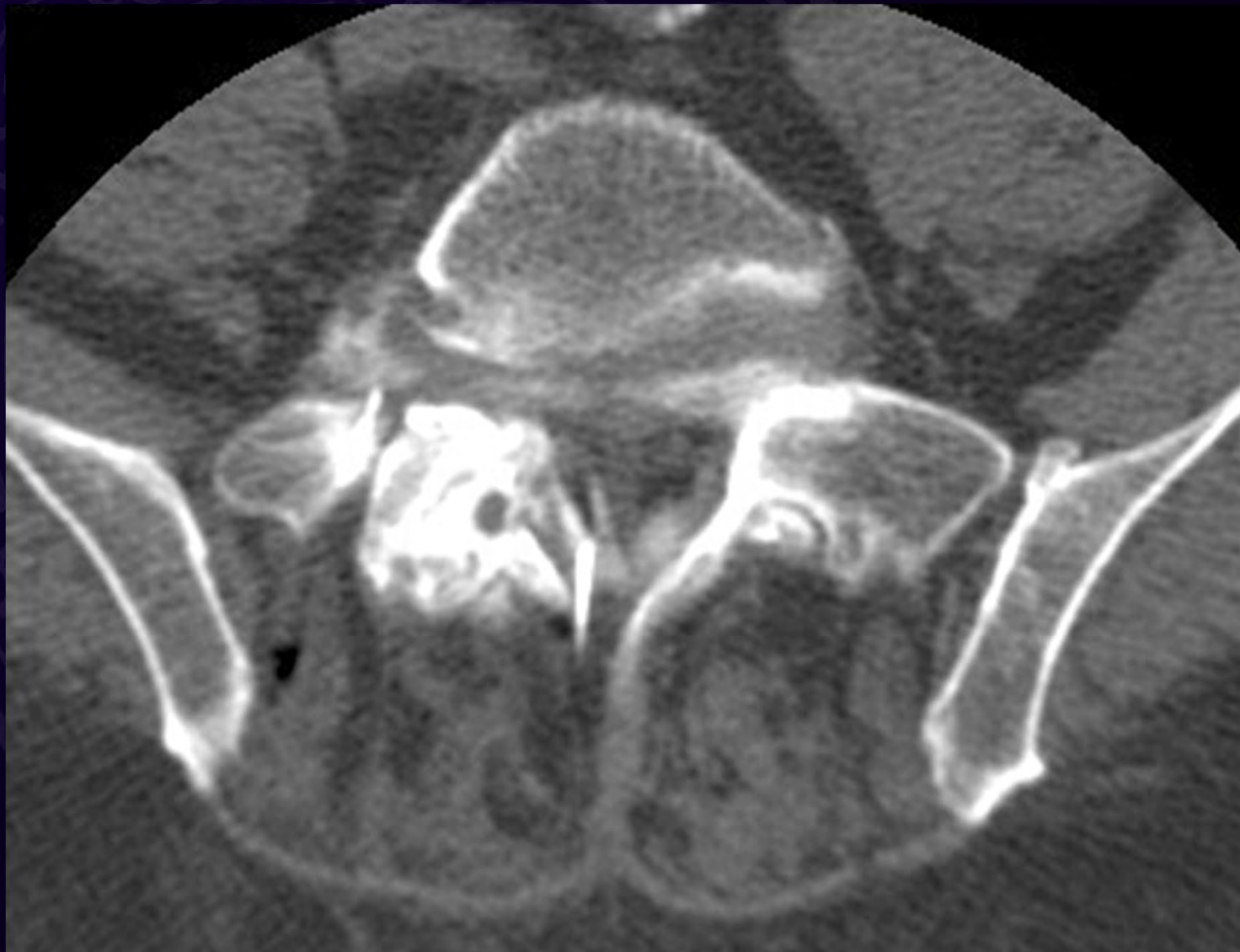


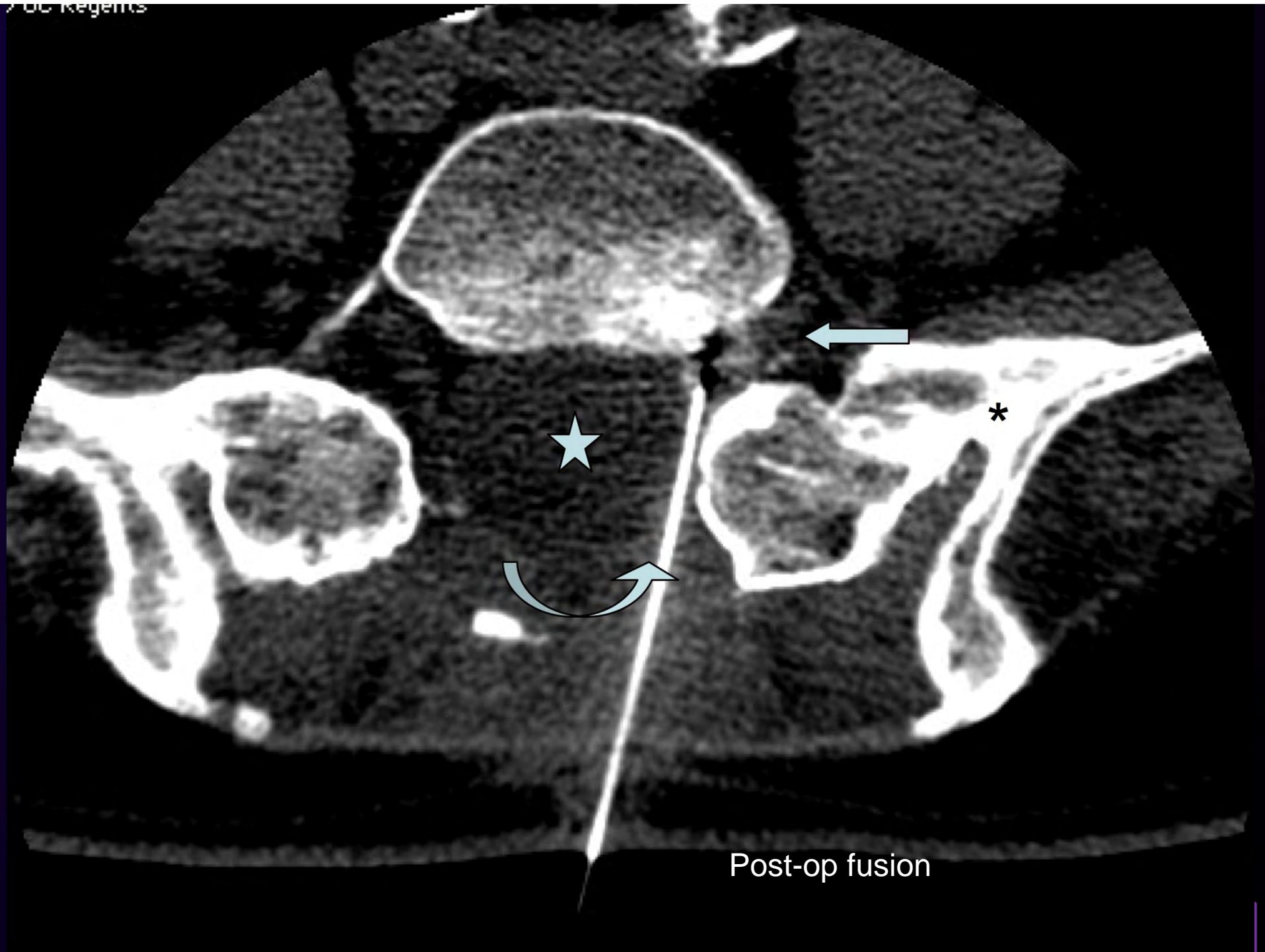
# L5 Nerve Block



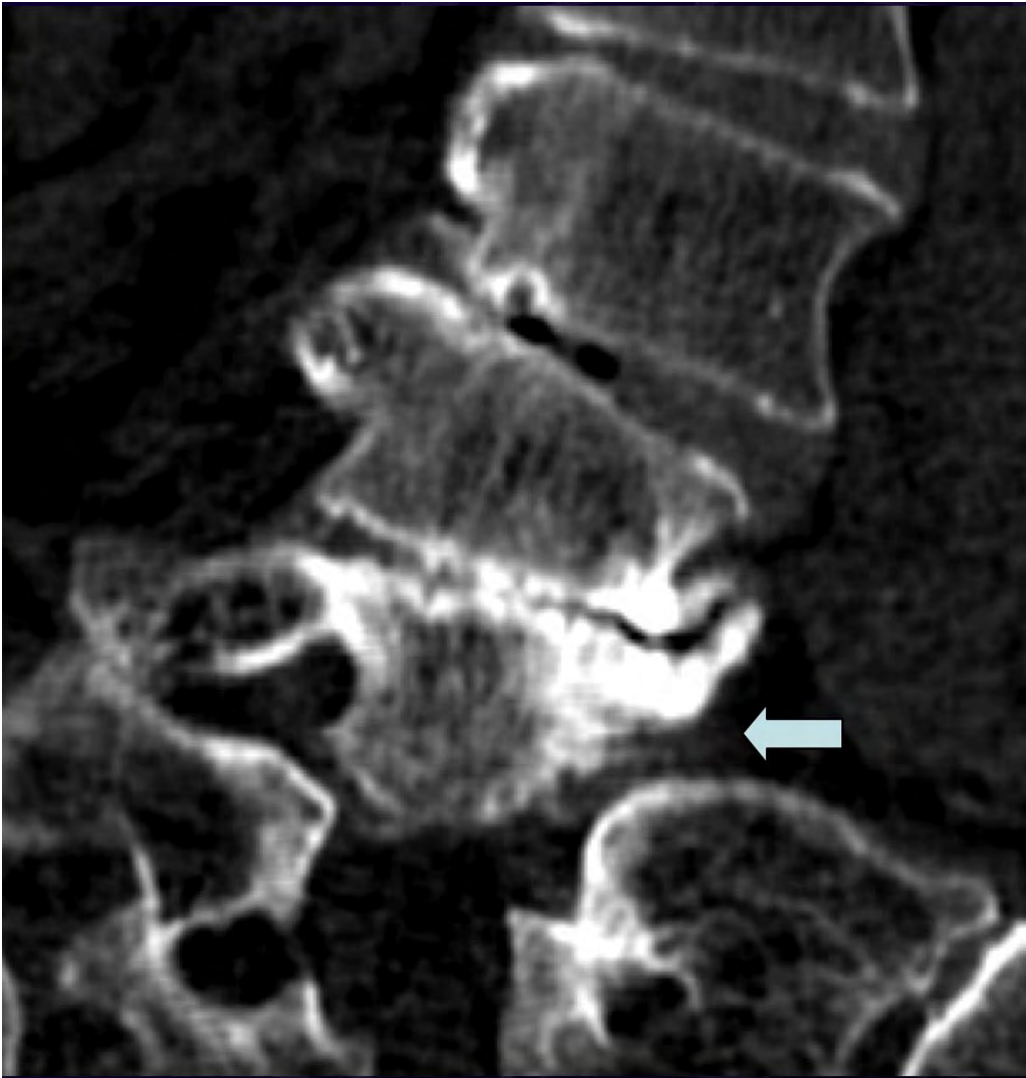
# TRANSFORAMINAL EPIDURAL NERVE BLOCK



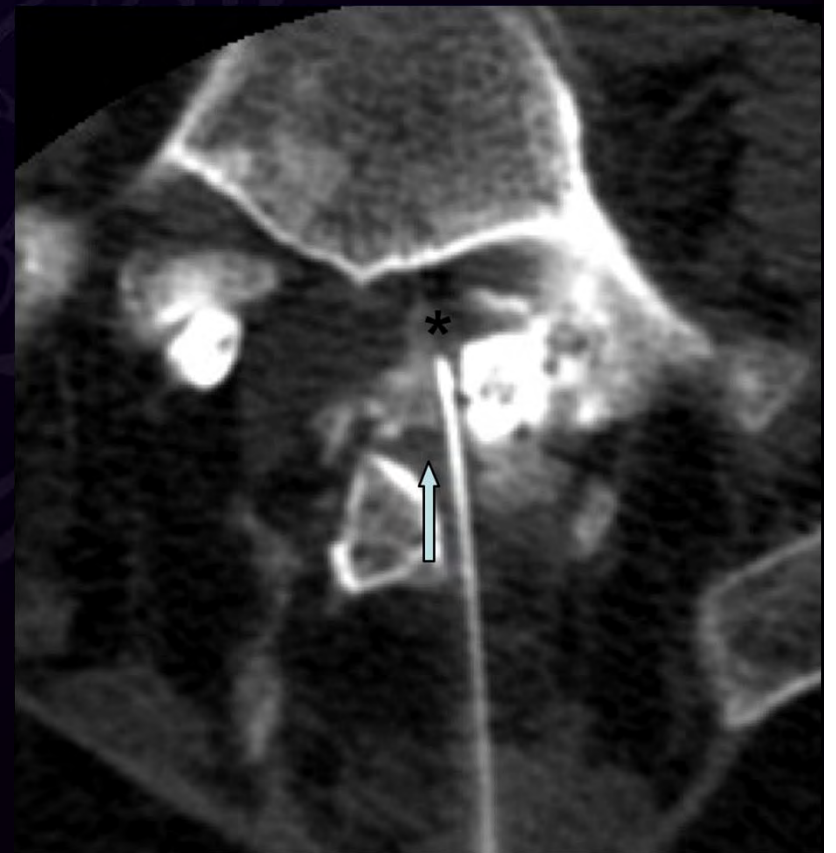


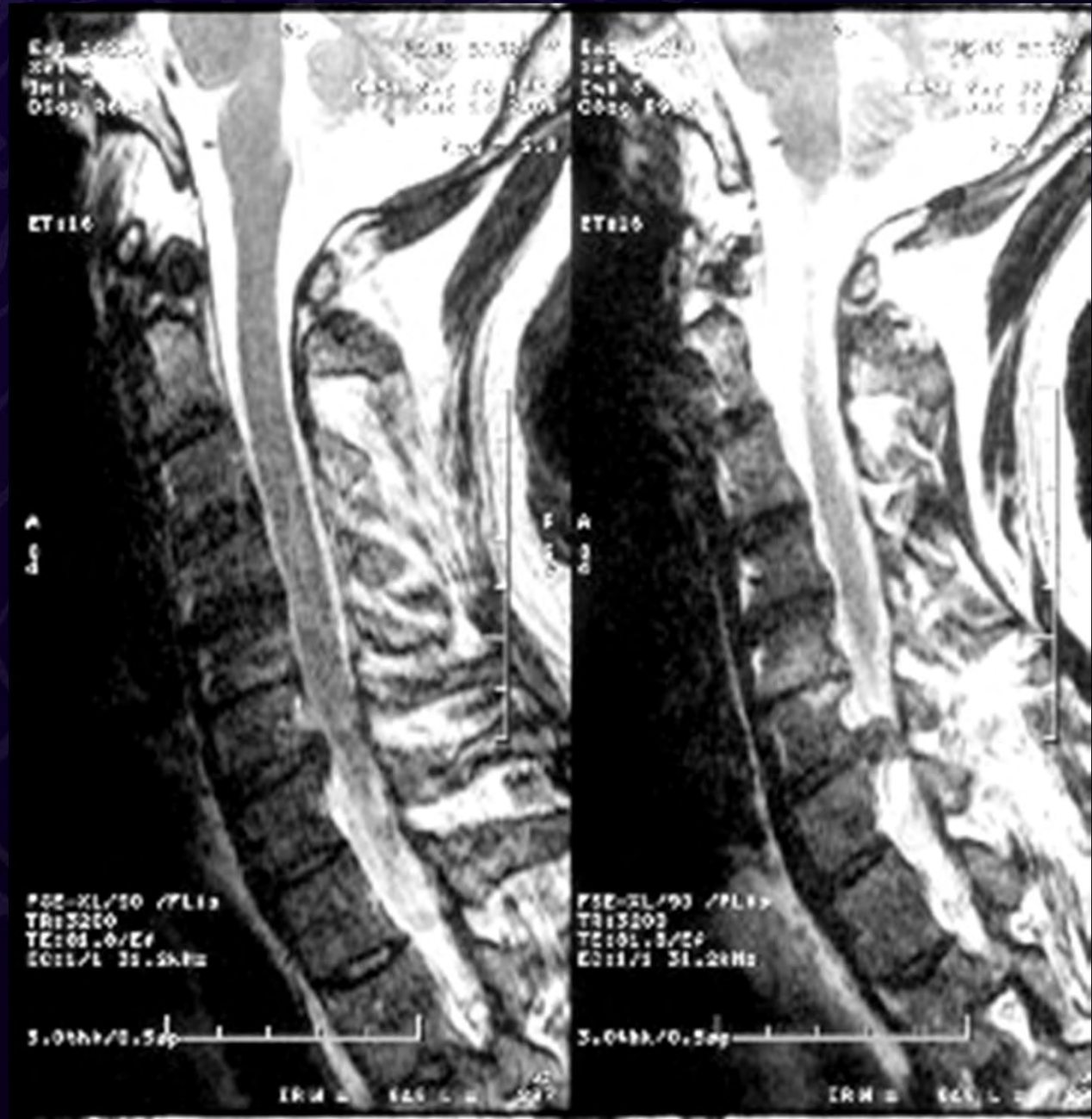
Post-op fusion

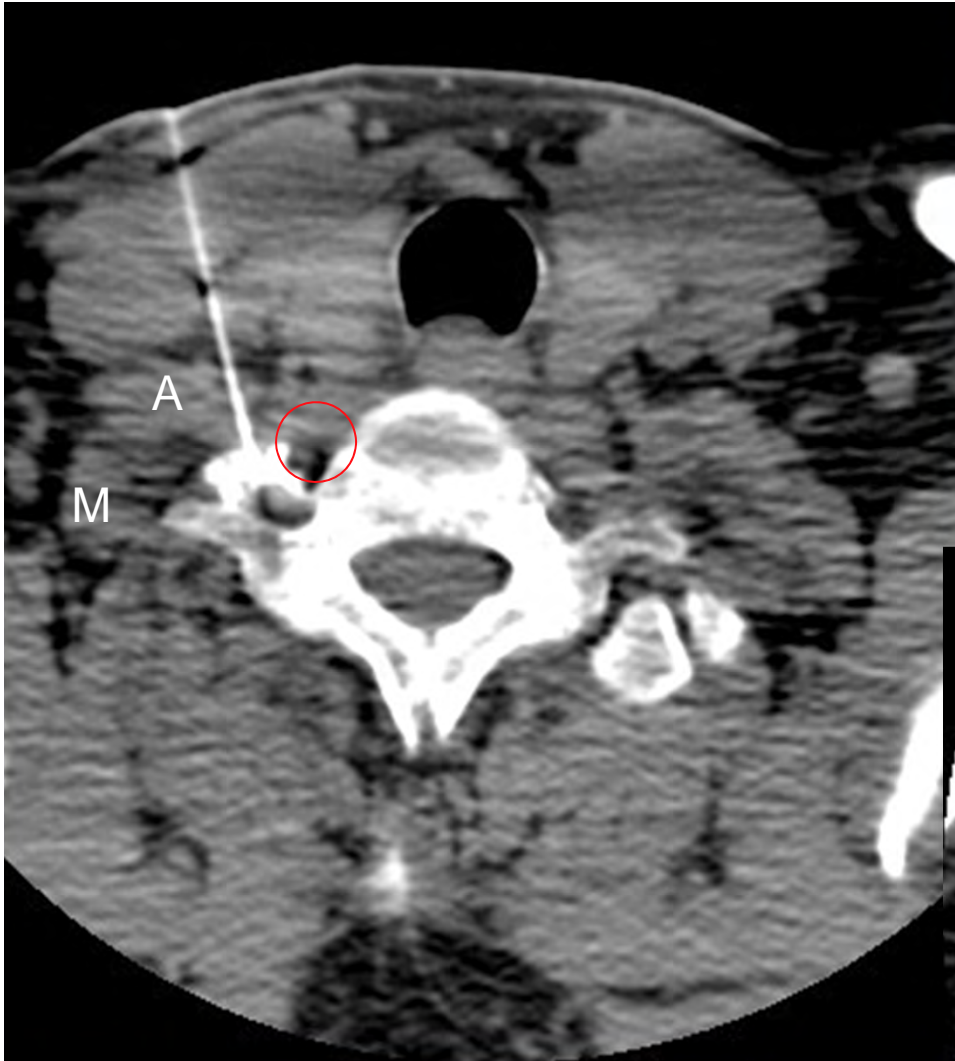


Scoliosis

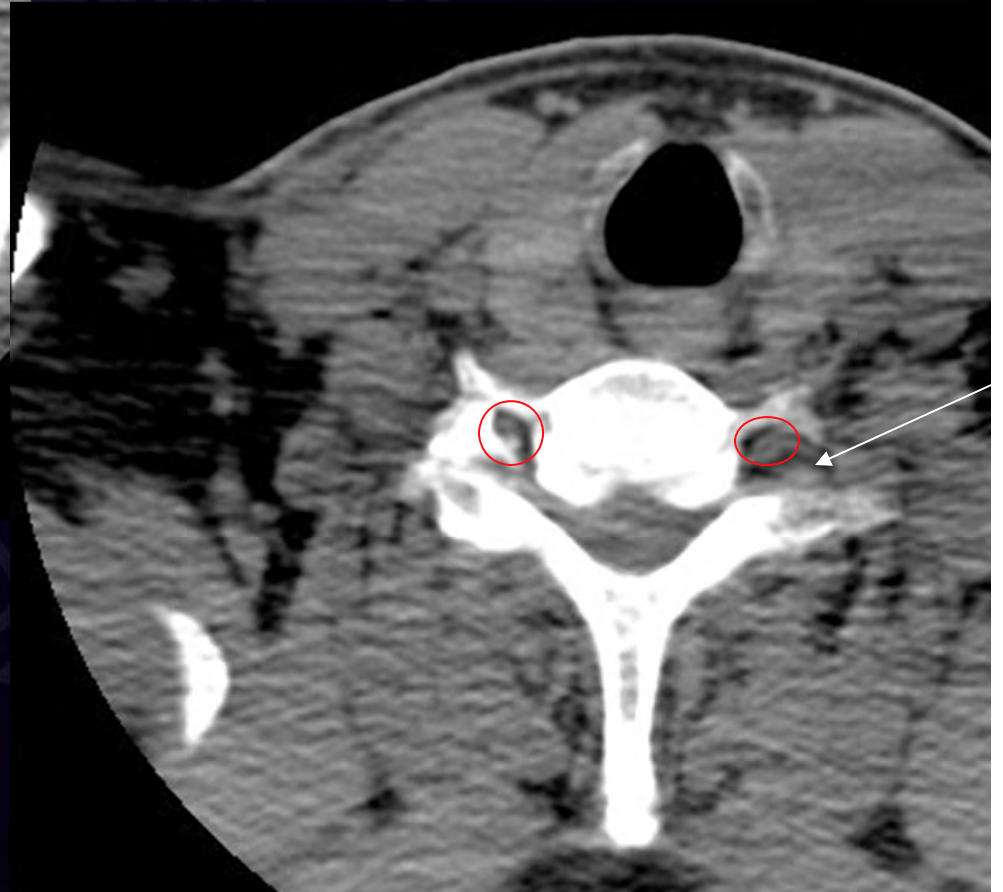








Caution - vertebral arteries



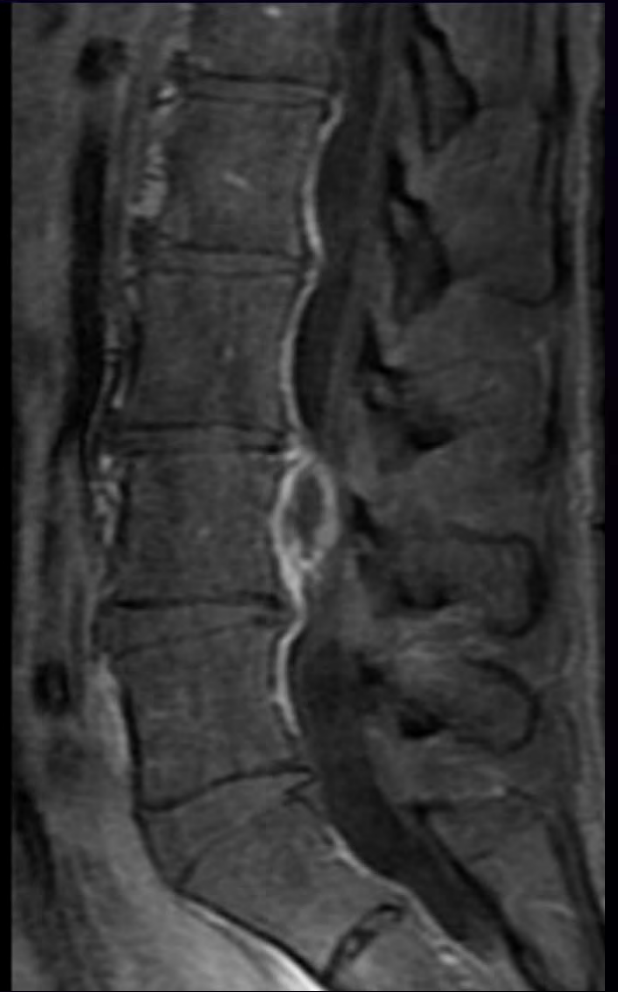
# 52 yo F R foot drop 2 weeks



T2



T1

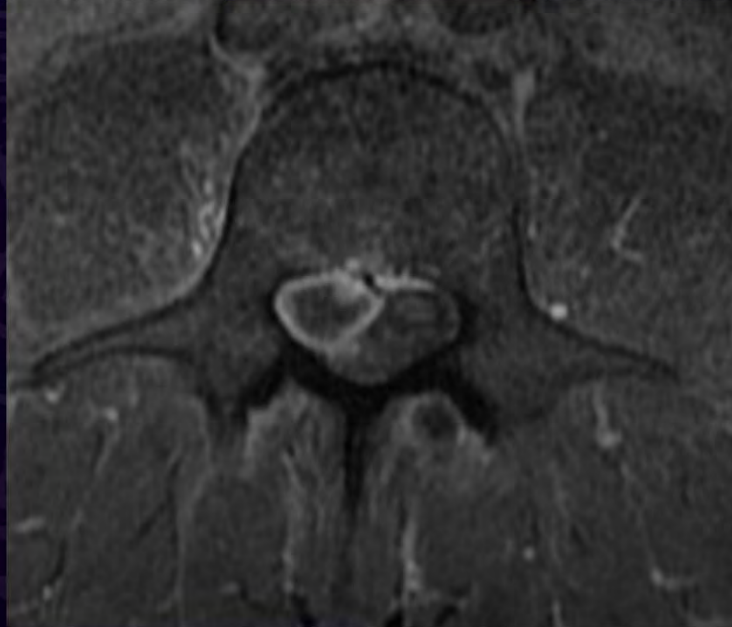
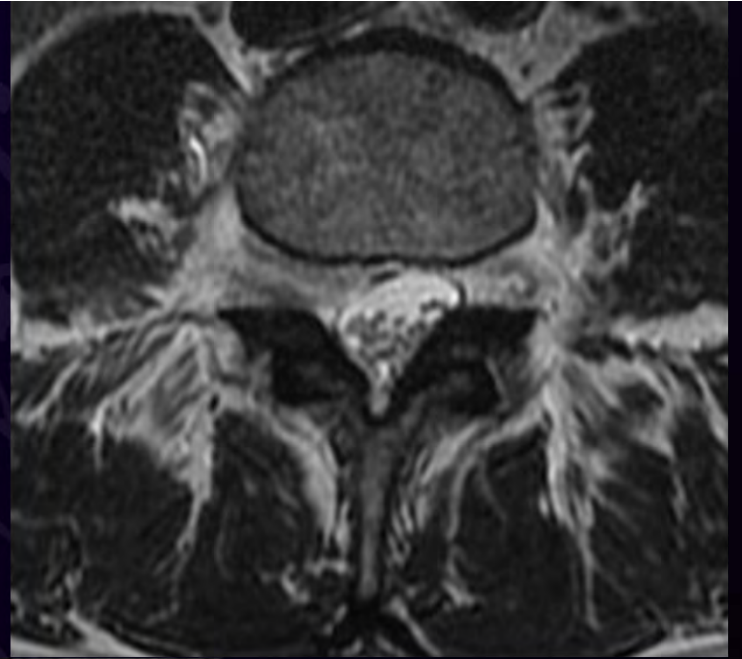


Gad



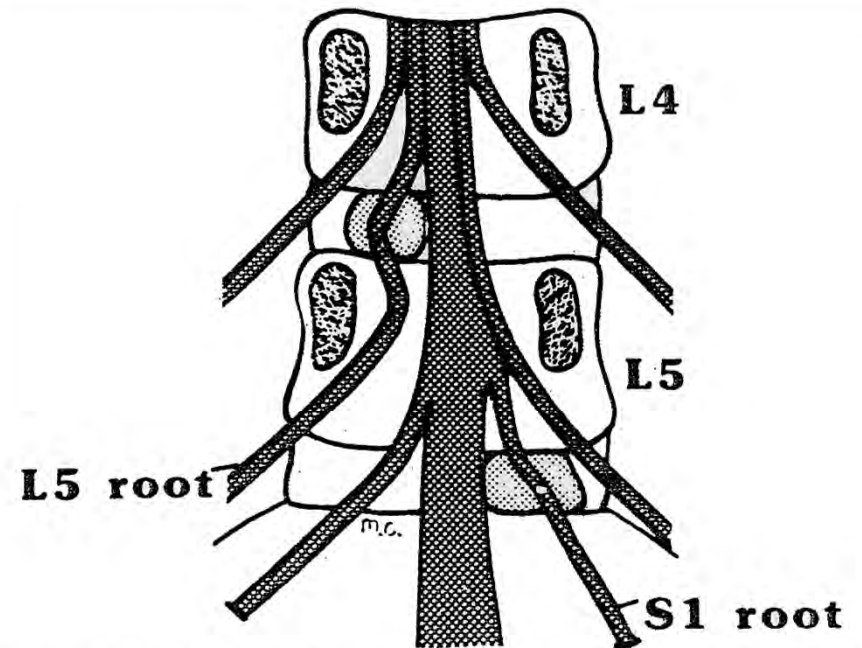
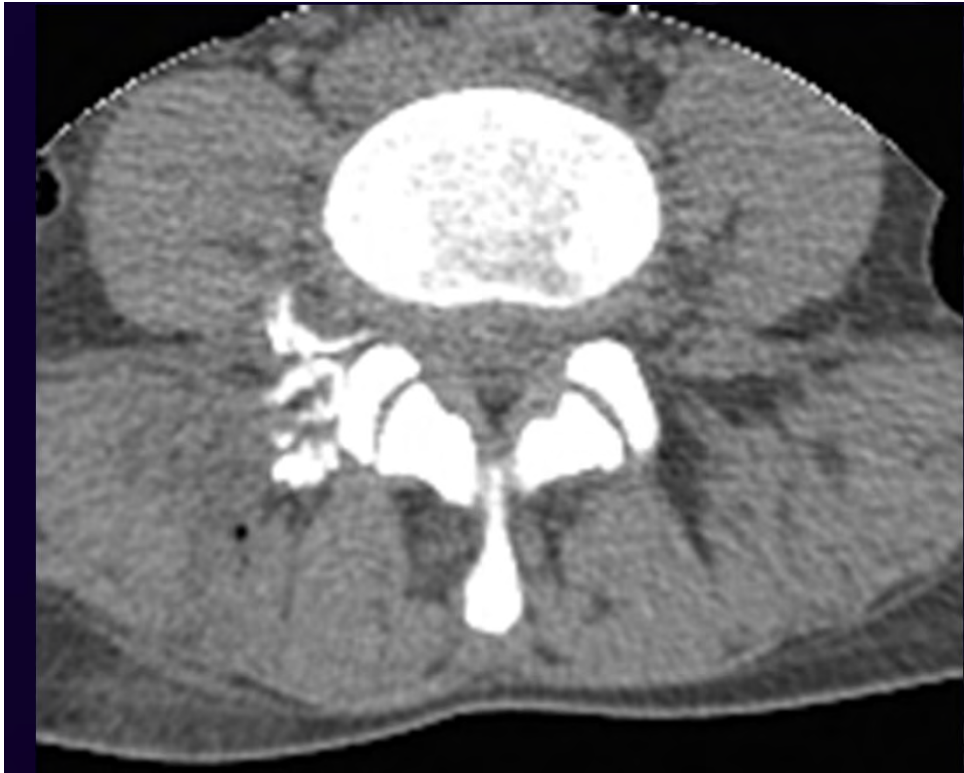

Axial  
T2



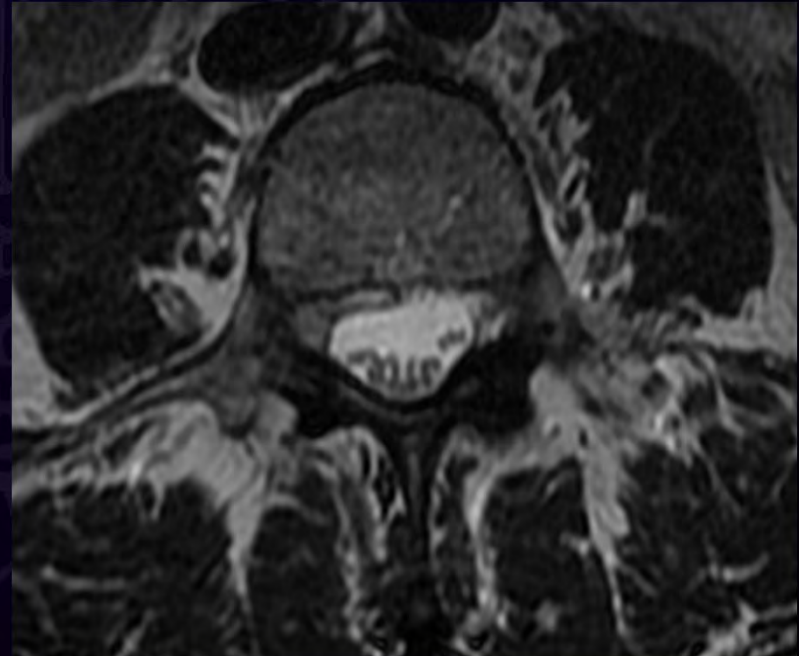
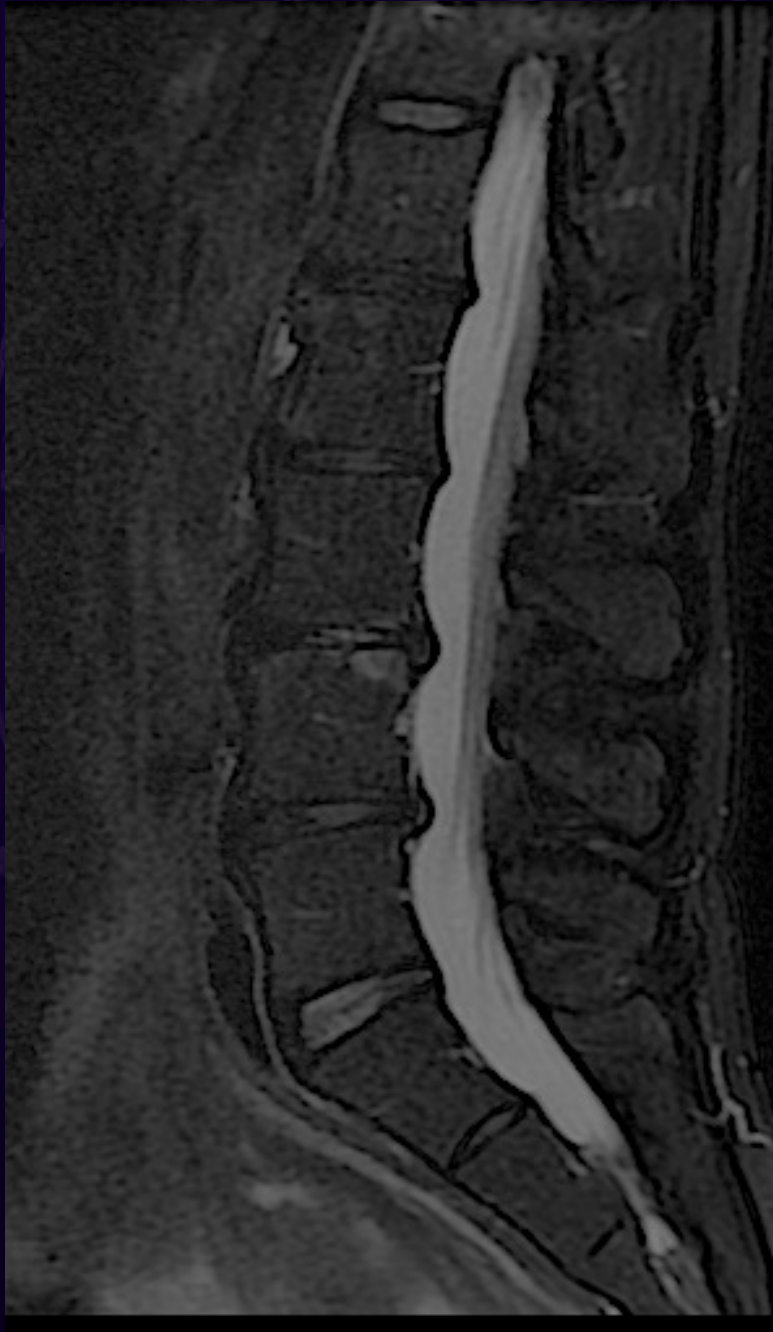Gad





**Figure 6-27. Disc Herniation.** Often an L4-L5 disc herniation will compress the L5 root; an L5-S1 herniation will compress the S1 root. (Modified from MacNab I: Backache. Baltimore, Williams & Wilkins, 1977.)

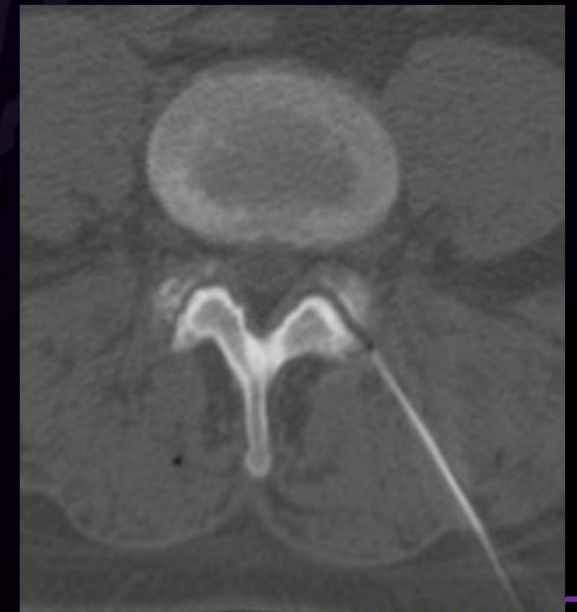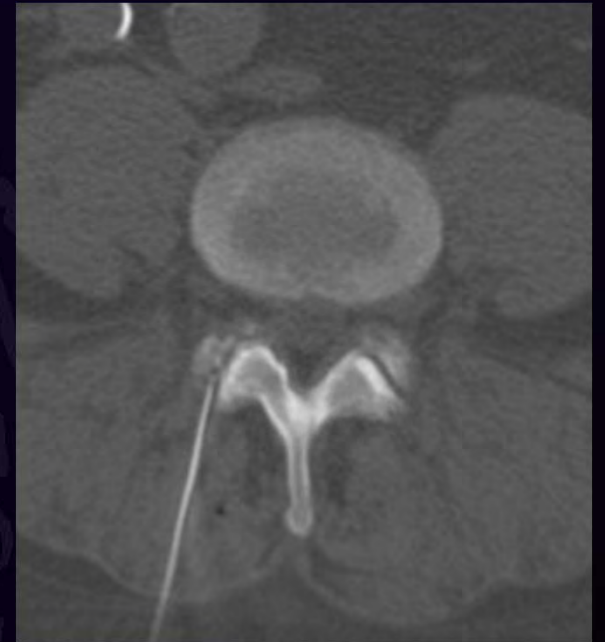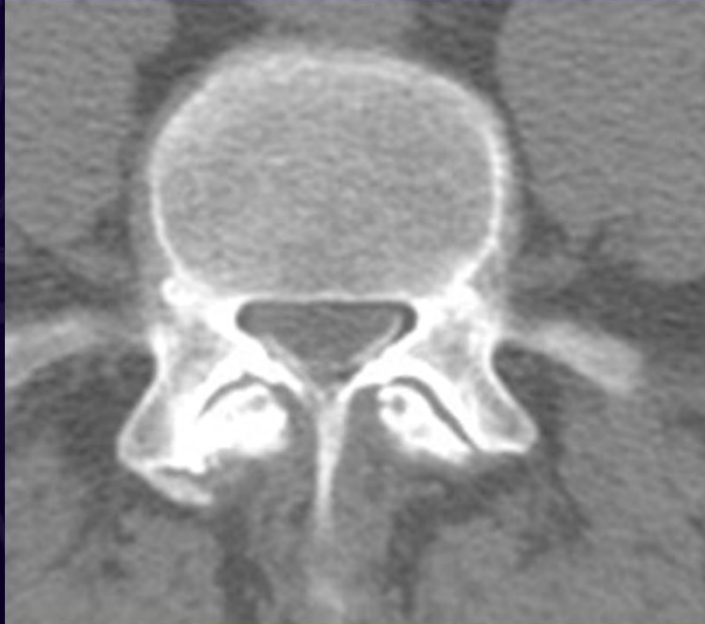2 months later



T2



## FACET PAIN

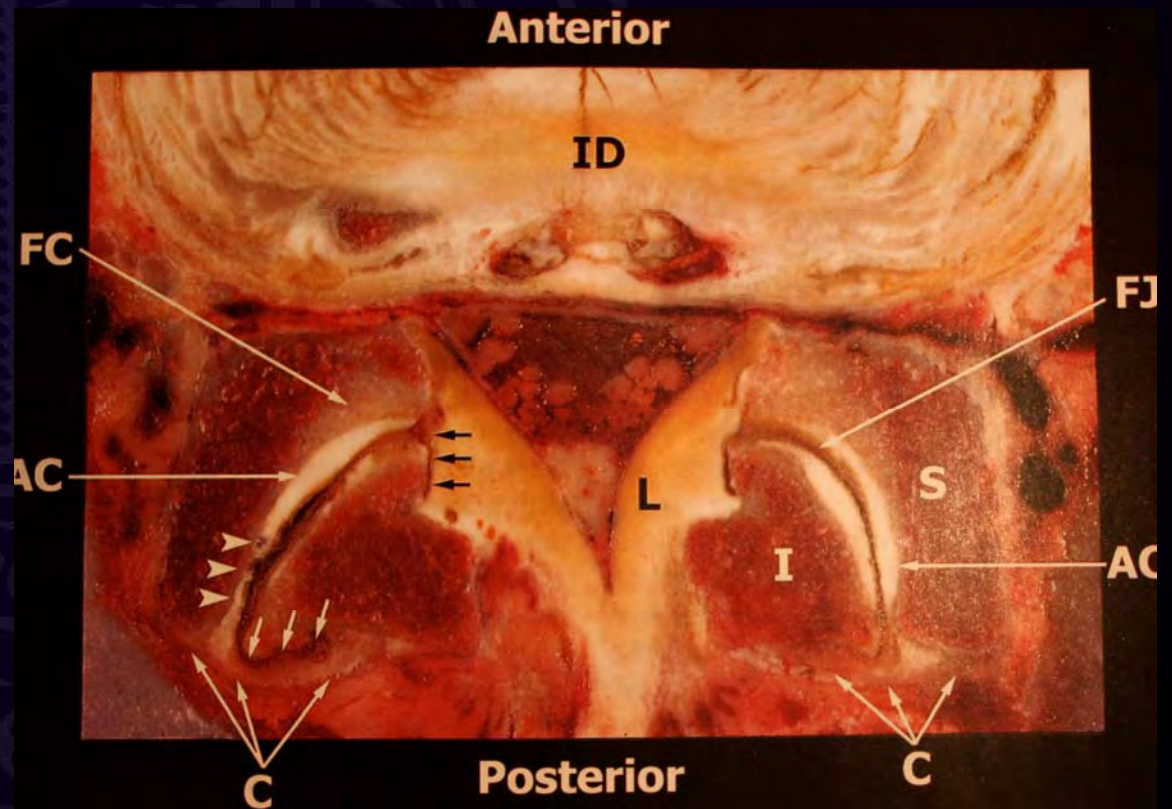


Able to go hours on stationary bike  
But could not walk more than a couple  
blocks



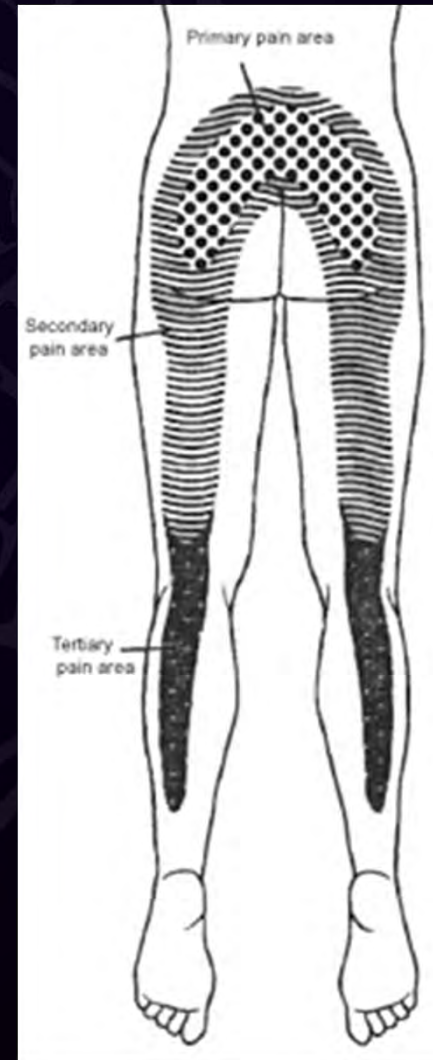
# Facet Joint

- True synovium lined
- Allows flexion, extension, rotation
- Major disease - osteoarthritis
- Loss joint cartilage, erosions, bony overgrowth, instability and subluxation
- Prevalence facet pain unknown



# Lumbar Facet Syndrome

- Standing: carry 16% compressive load
- Relatively unloaded when sitting
- Disc space narrowing - increased load upon facets, esp. in extension
- Ghormley 1933: primarily low back - frequently into groin, hip, thigh and occasionally below knee - not into feet





# Lumbar facet pain

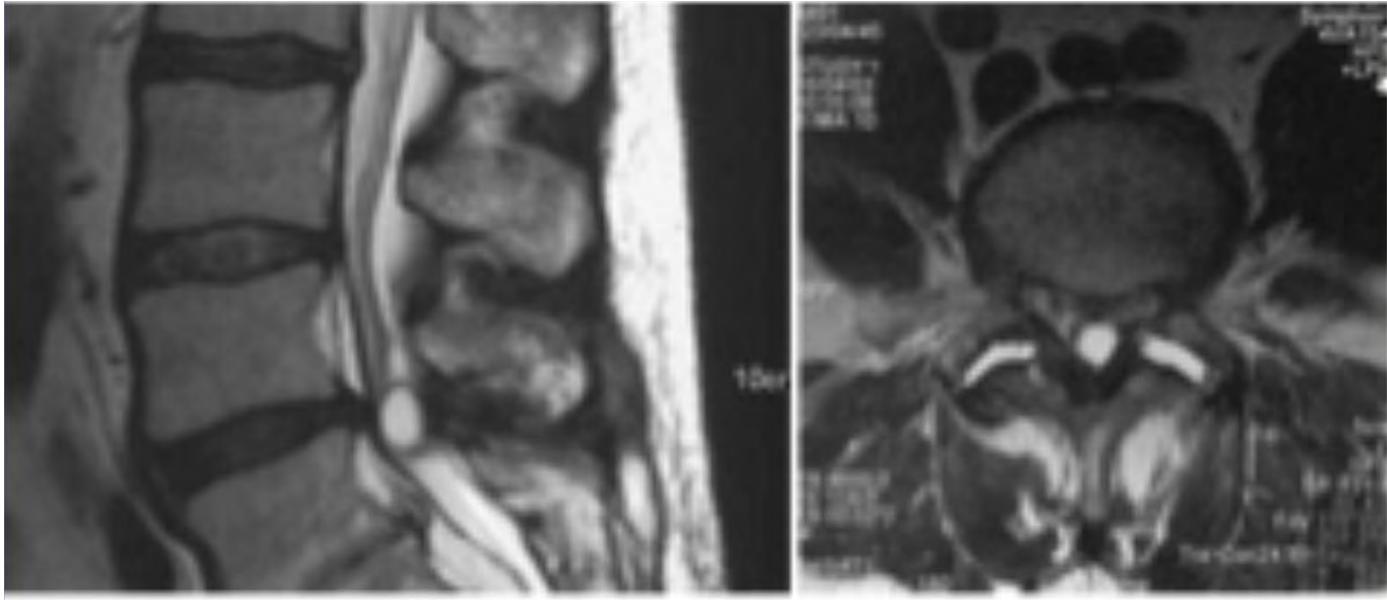
- Sudden “catching” or “locking”
- Usually aggravated with prolonged standing (relative extension)
- No typical change with valsalva
- 1963: Hirsch et al: pain in upper back and thigh  
- 10% hypertonic saline
- Contrast injection also results in pain
- Intensity of pain proportional to volume fluid injected

# NEJM – LBP Facet blocks

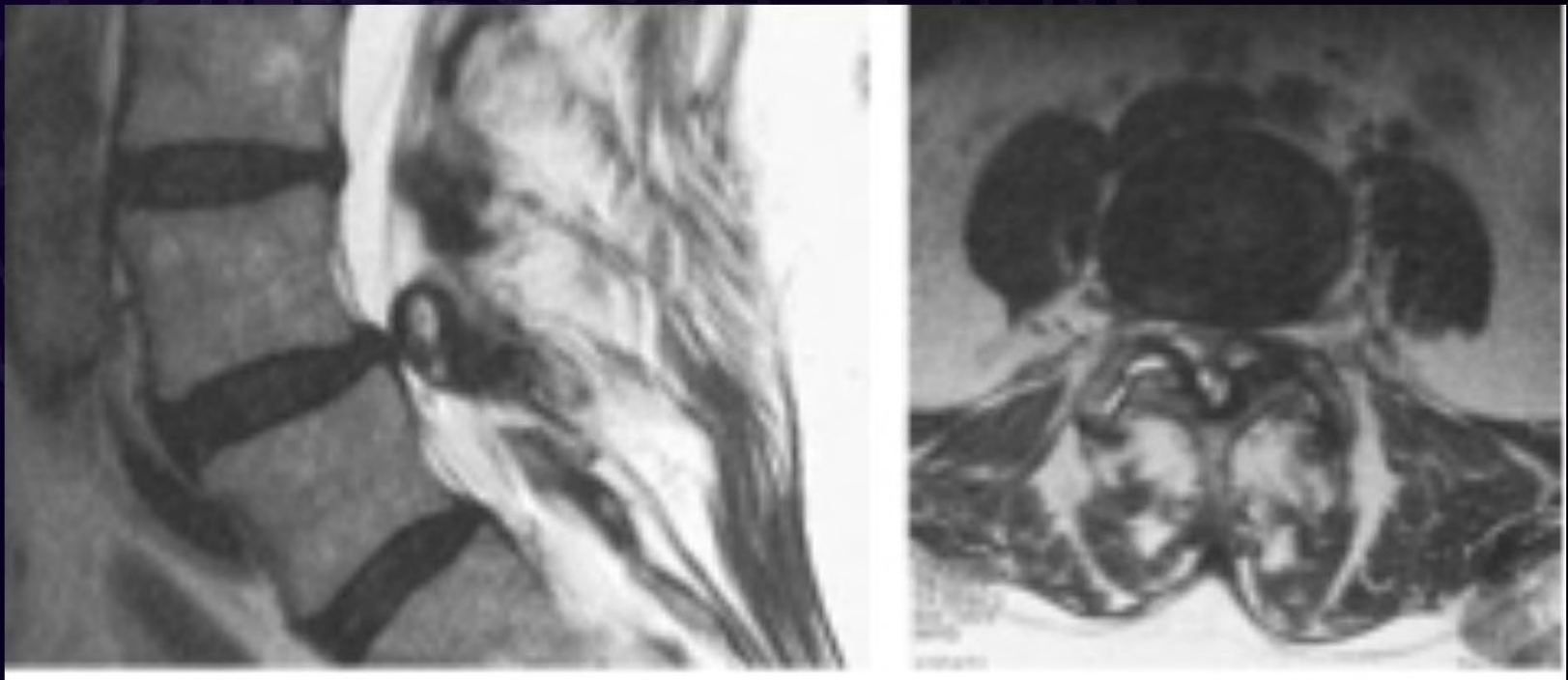
- 46% pts marked improvement back pain at 6 mths – depomedrol
- 15% pts placebo
- Statistically significant ( $p=0.002$ )

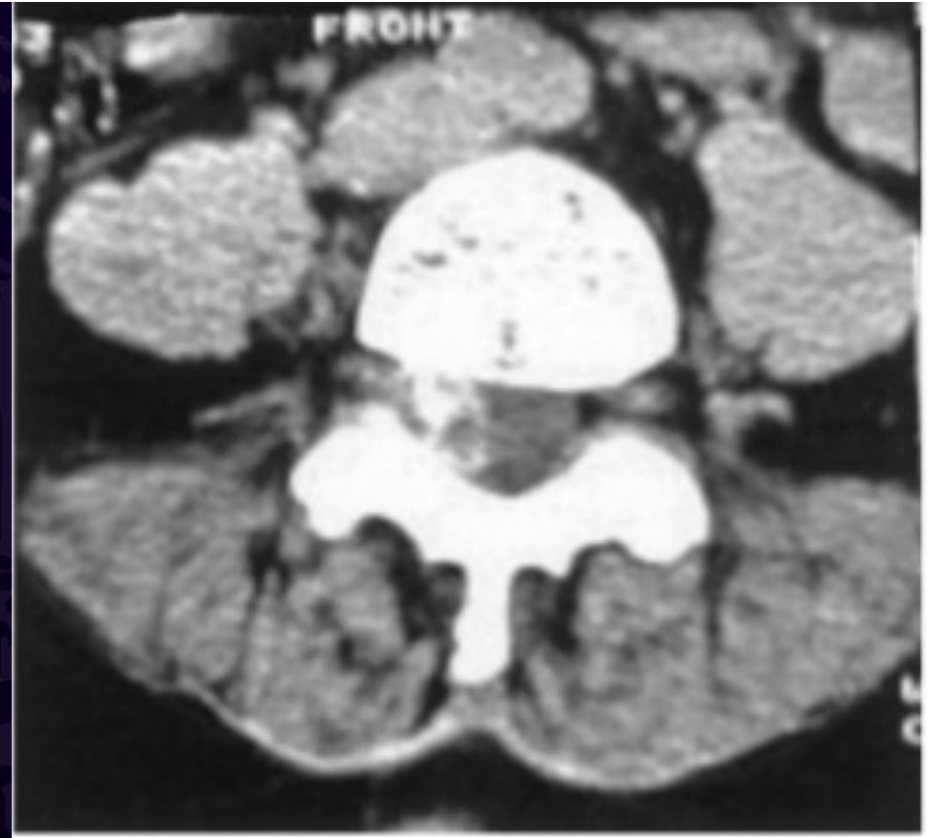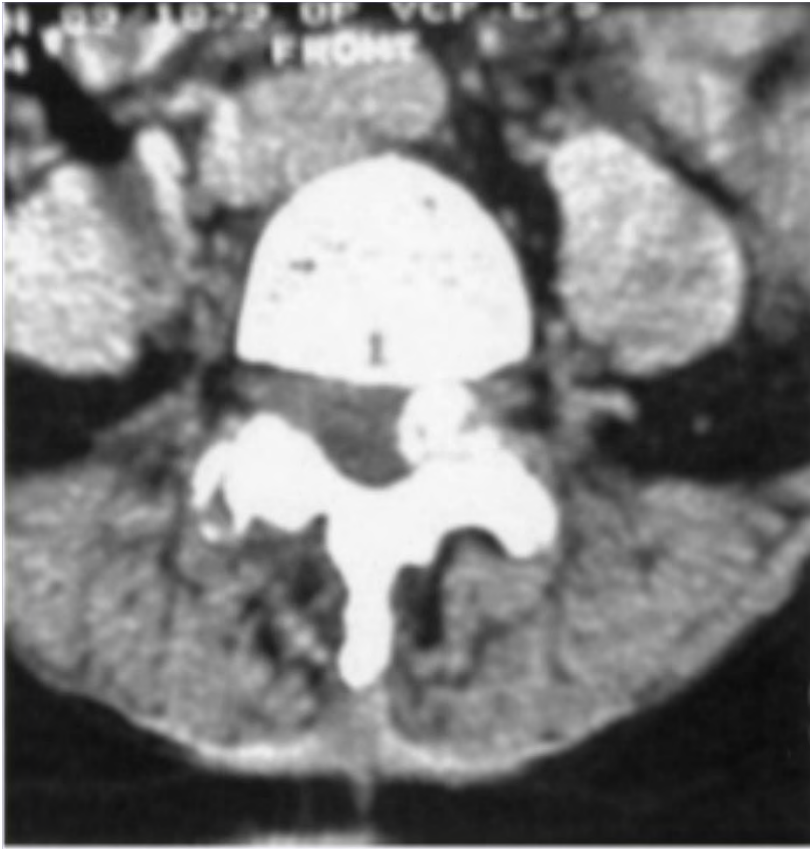Carette S et al 10/1991



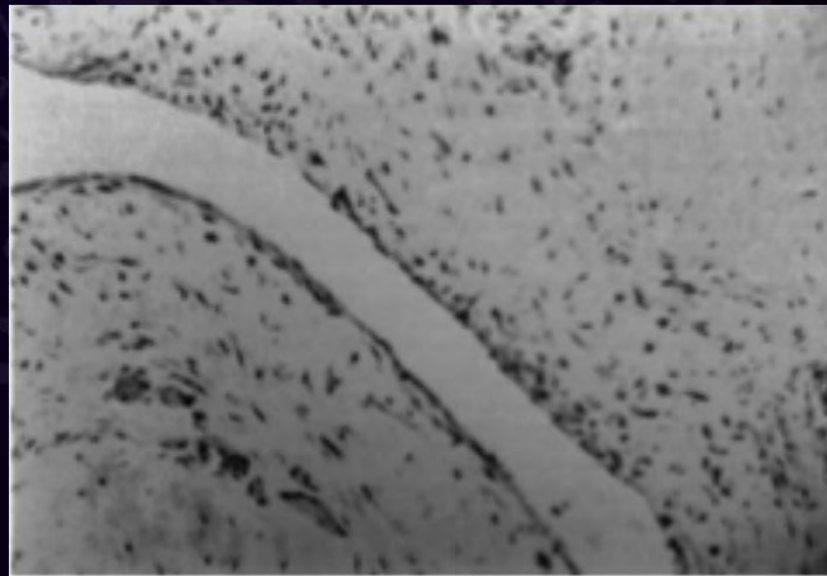


Gout



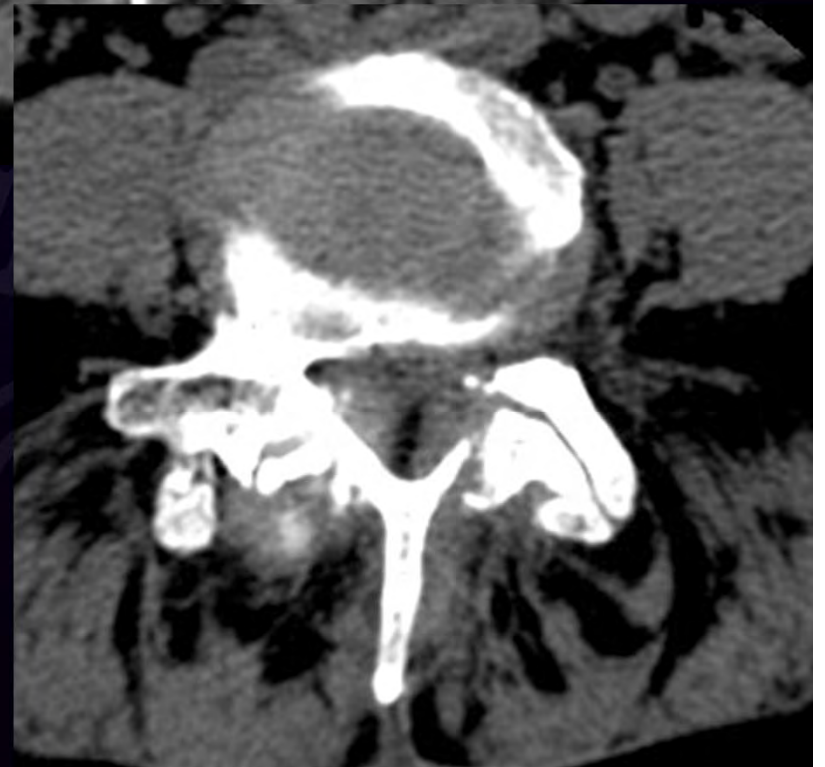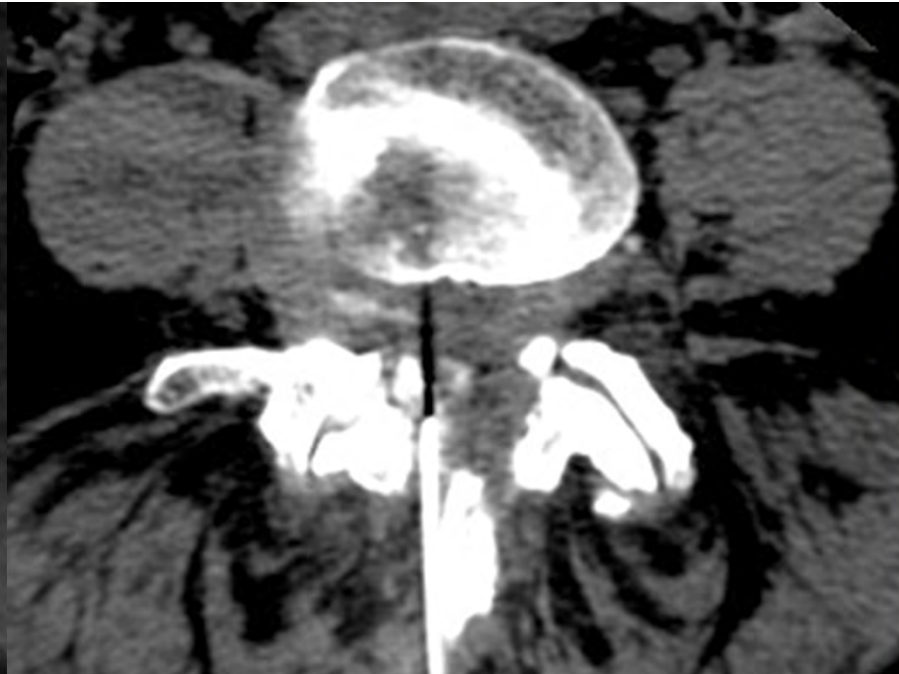
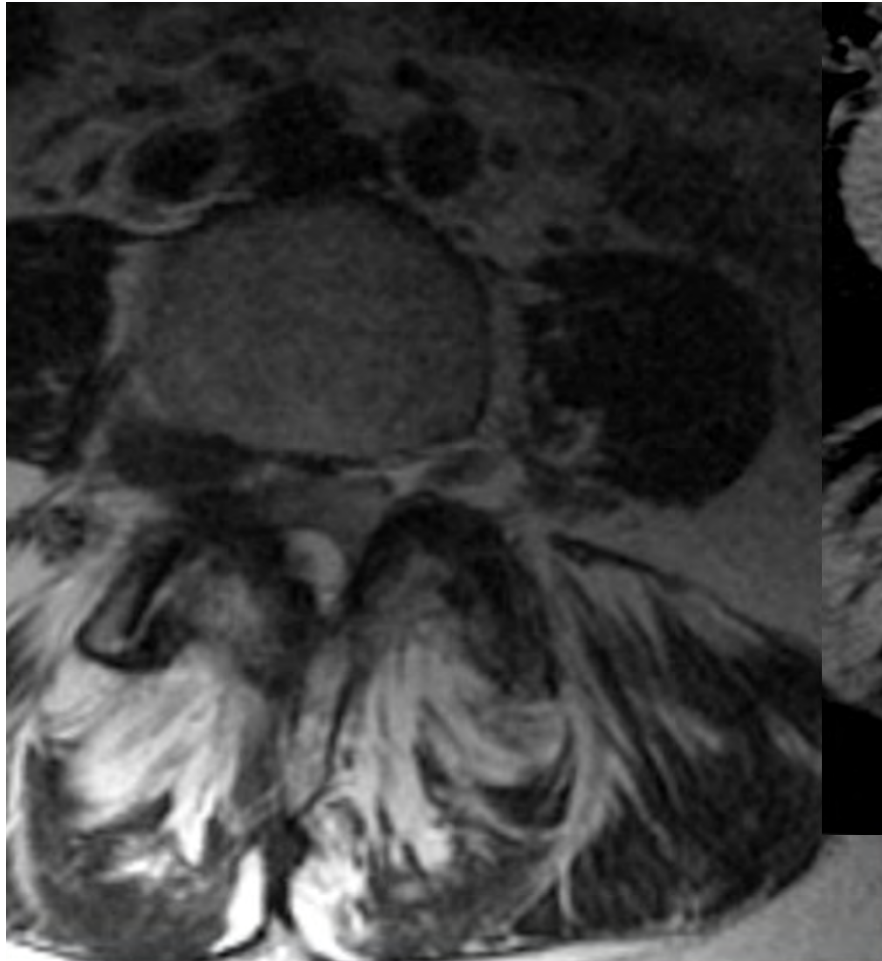


CPPD



Gadgil et al  
Spine 2002





SYNOVIAL CYSTS  
INJECTION/ASPIRATION -  
CONTENTS MAY BE  
VISCIOUS - CONSIDER GOUT,  
CPPD/PSEUDOGOUT

# Radiofrequency Ablation

ID: 10940583  
St: 13880 Se: 4  
2006/01/27  
08:41:12  
Kern: STANDARD  
CT  
VR  
Mag: 1.016

006/01/27  
8:41:12  
ern: STANDARD  
T  
R  
Mag: 1.674

140.000 kV  
285 mA  
Tilt: 0.000

140.000 kV  
285 mA  
Tilt: 0.000  
FOV: 248.000 mm  
Thickness: 2.500 mm



# Radiofrequency Lesioning

- Impedance: 200-500 ohms
- Sensory testing - 50 Hz 0-1 volt - look out for radicular sensation
- Motor testing - 2 Hz 1-10 volts - multifidus contractions ok - look out for gluteal or extremity contractions
- Lido after testing
- 80 degrees celsius 90 seconds





# NEJM - RFA

In pts. chronic cervical facet pain RFA can provide lasting relief

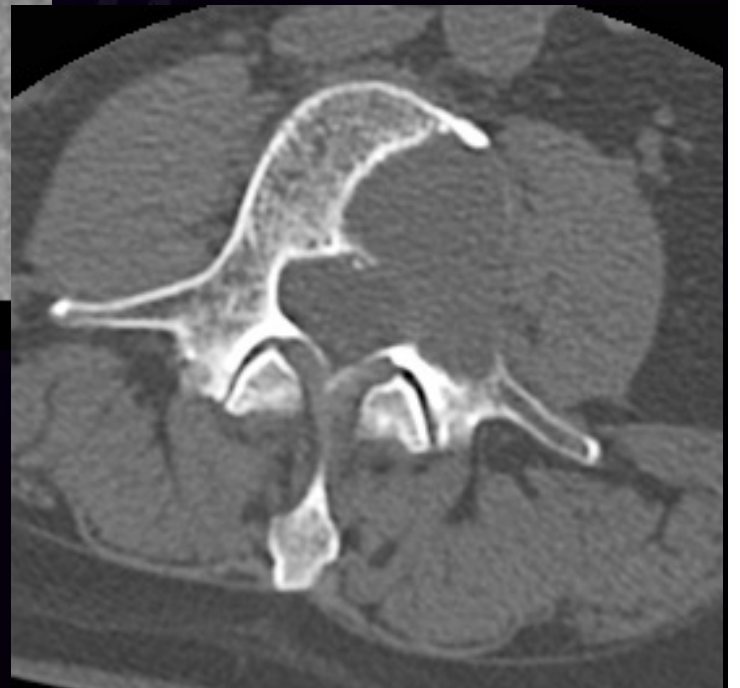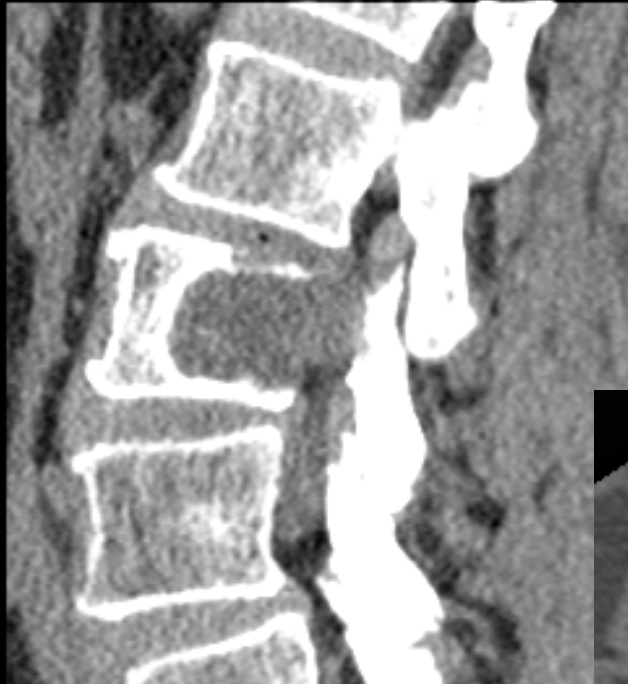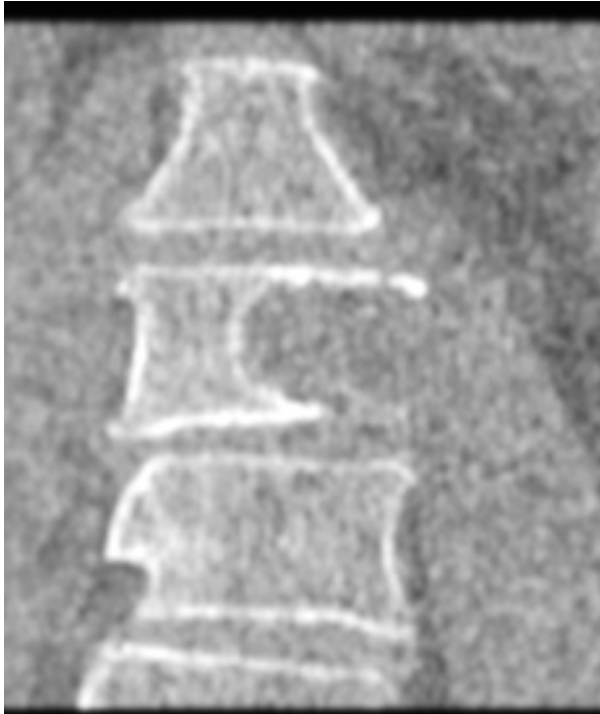- Randomized double blind trial
- RFA cervical facets
- Median time for 50% pain recurrence: 263 days treated vs. 8 days placebo (p=.04)

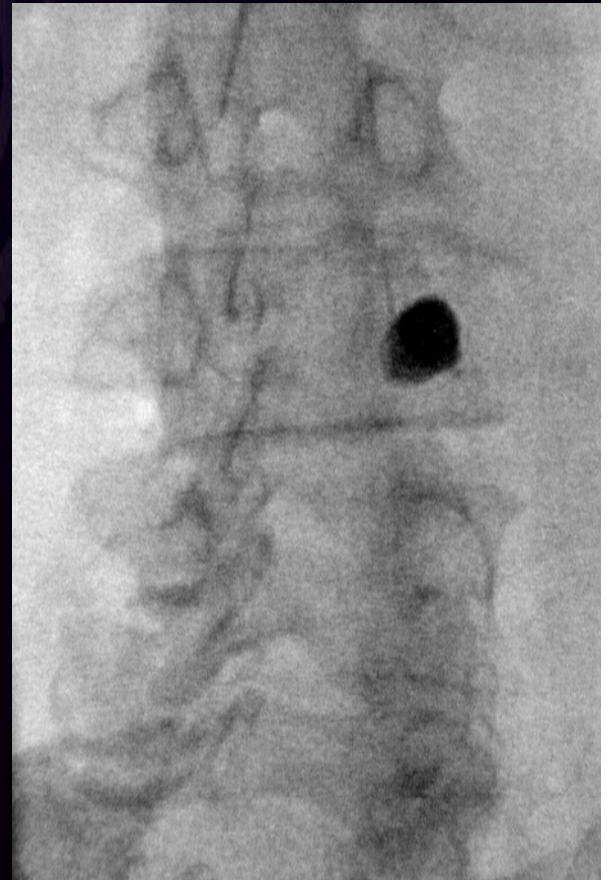
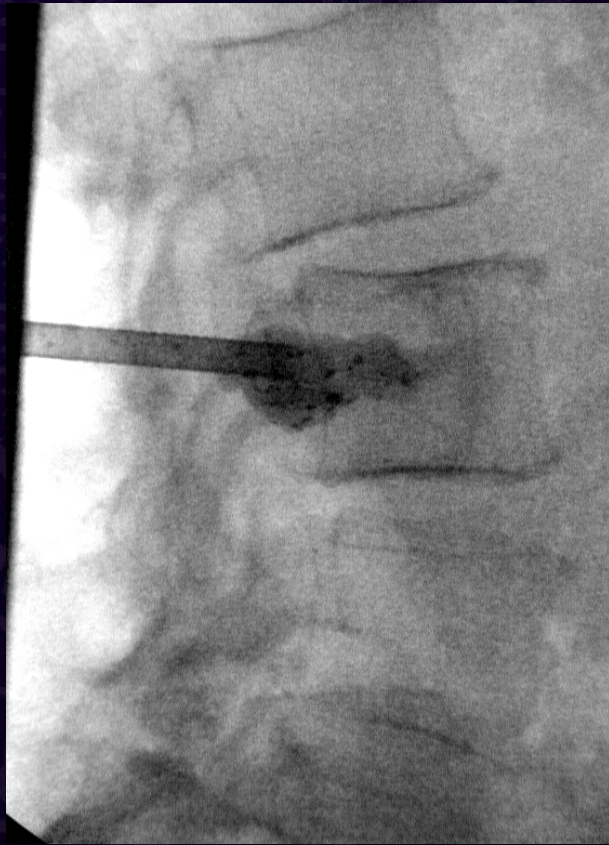
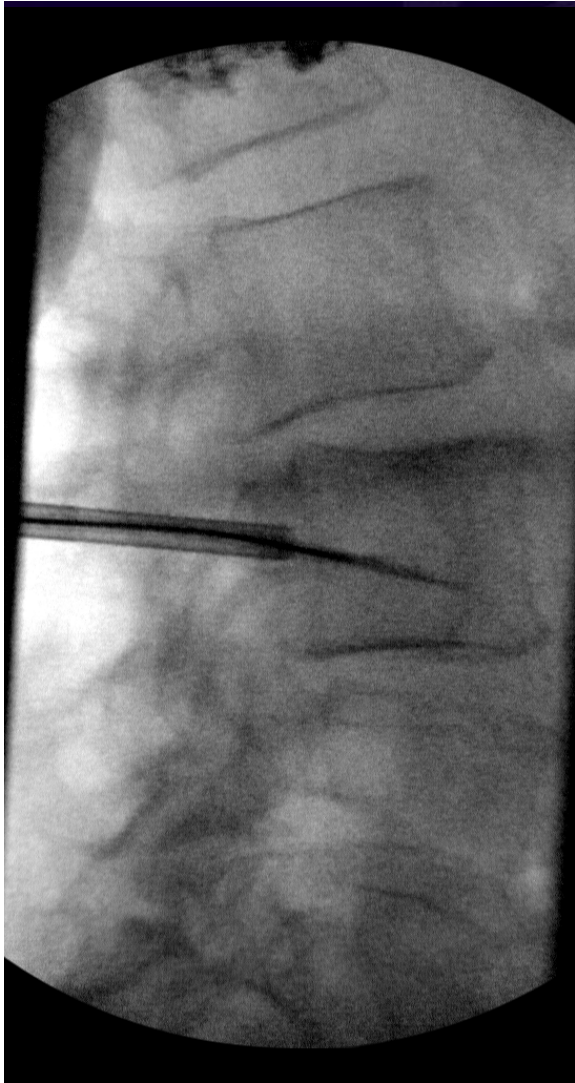
Lord SM et al NEJM 1996 335:1721-6

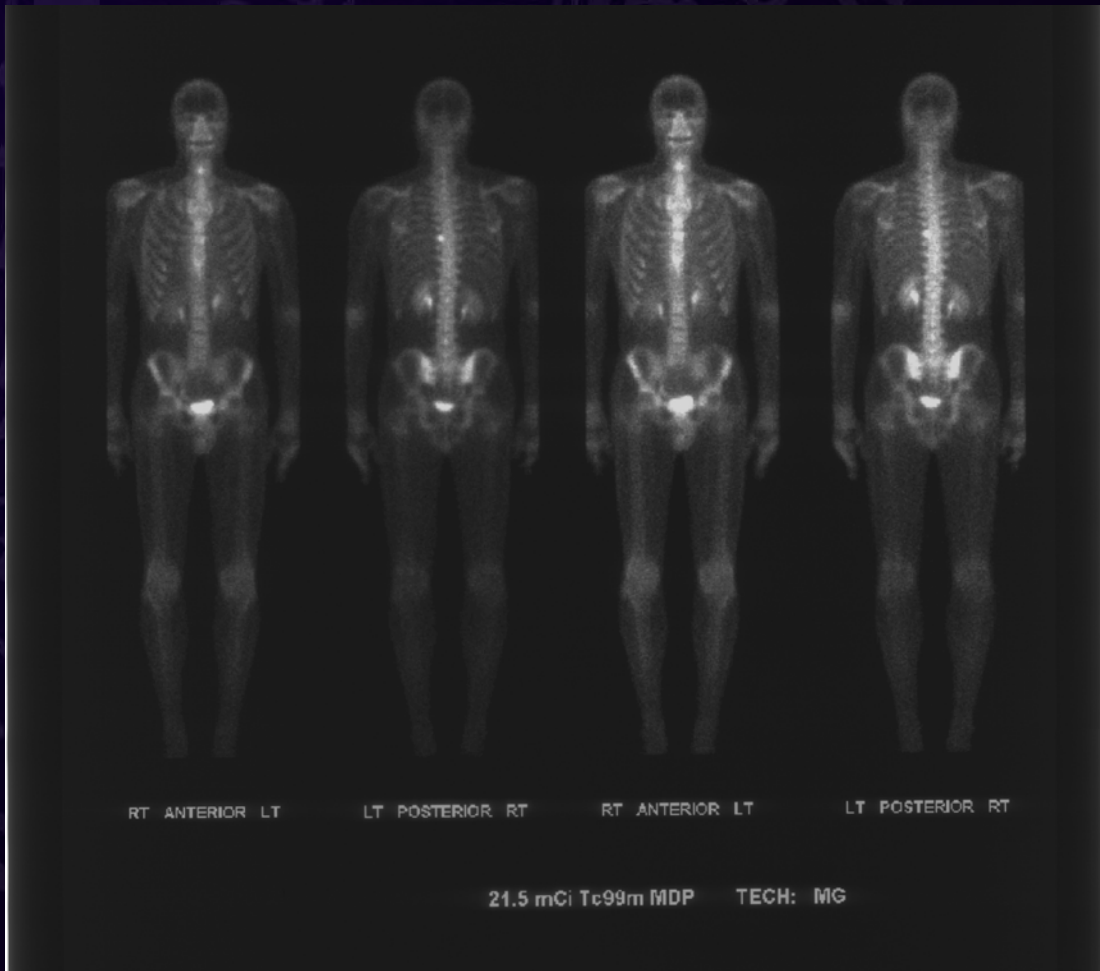
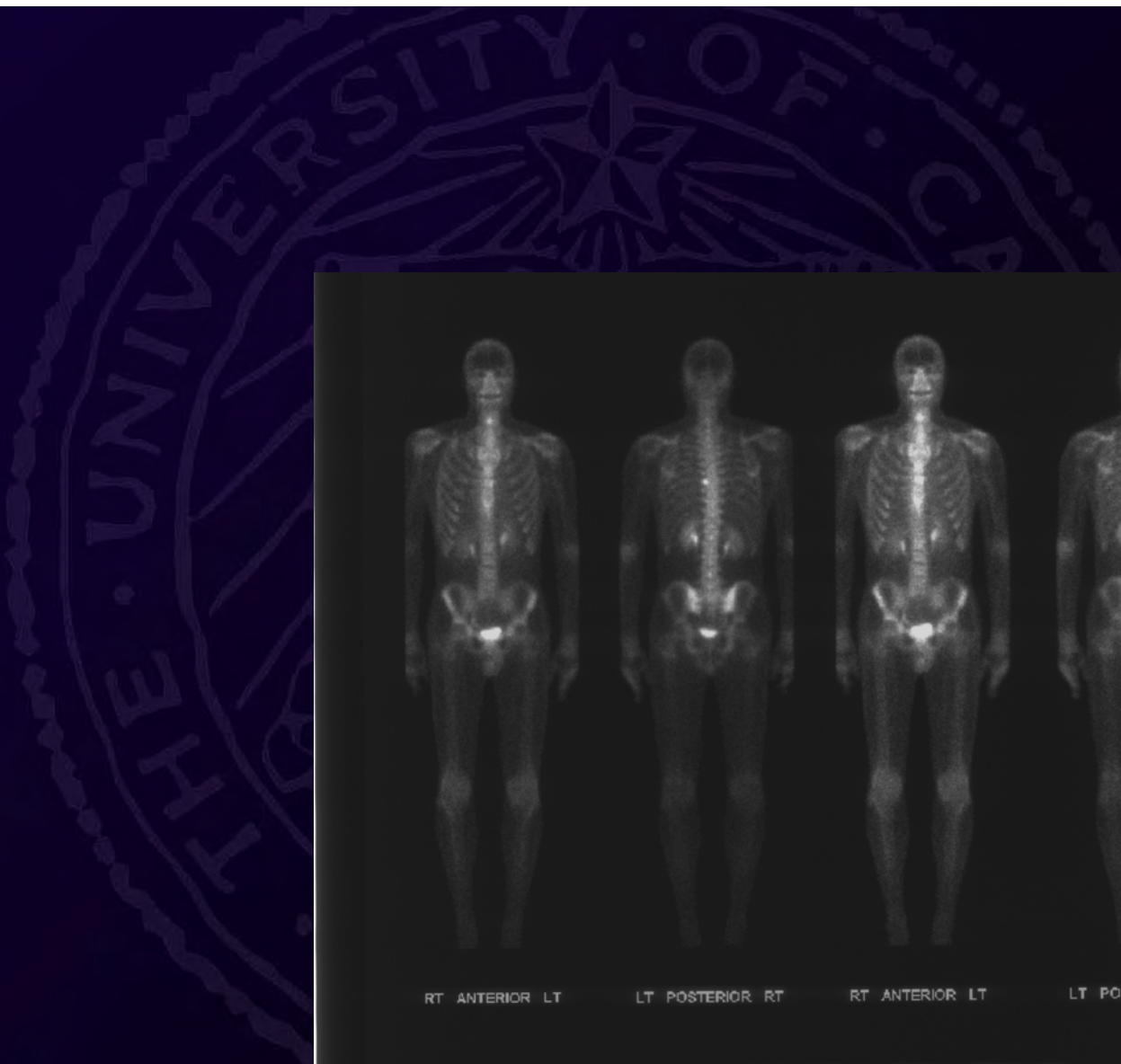


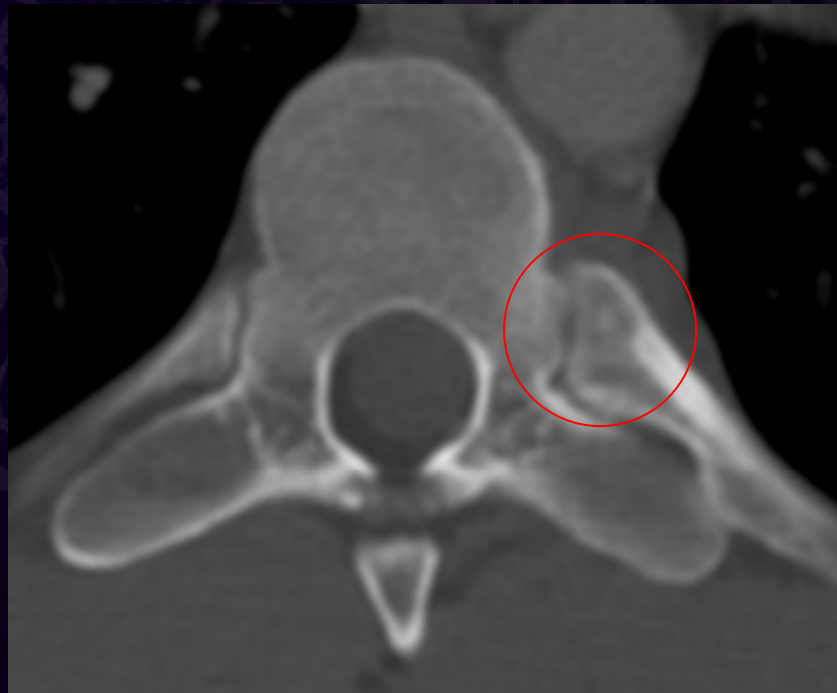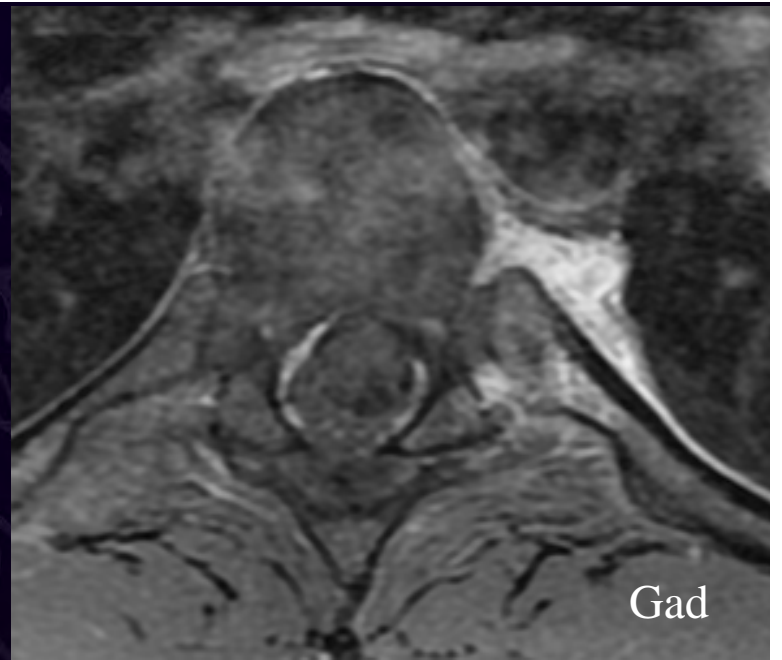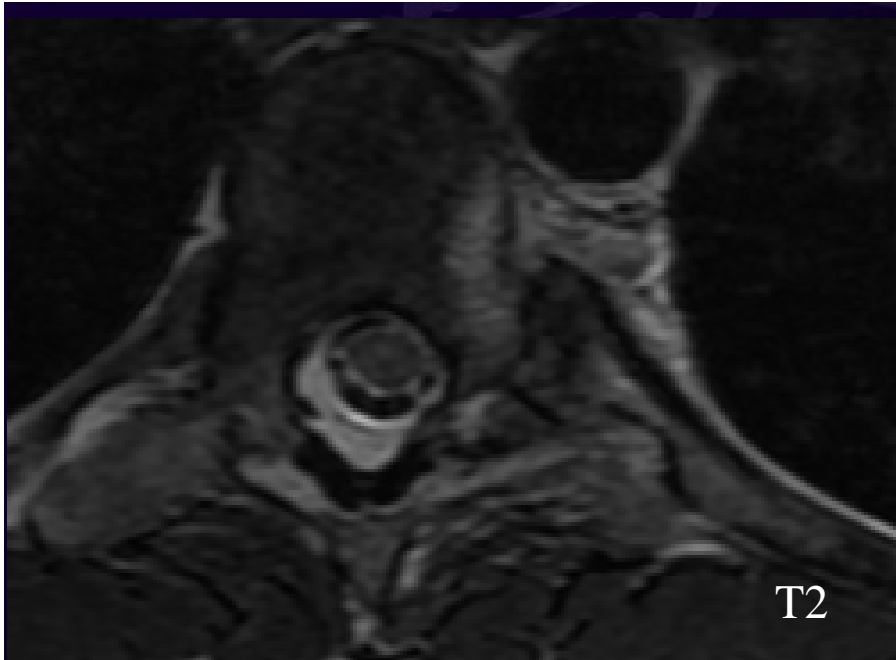
# Facet denervation

- Effects of facet denervation usually not permanent - 1 year +/-
- Best candidate - 80% improvement from facet and medial branch blocks

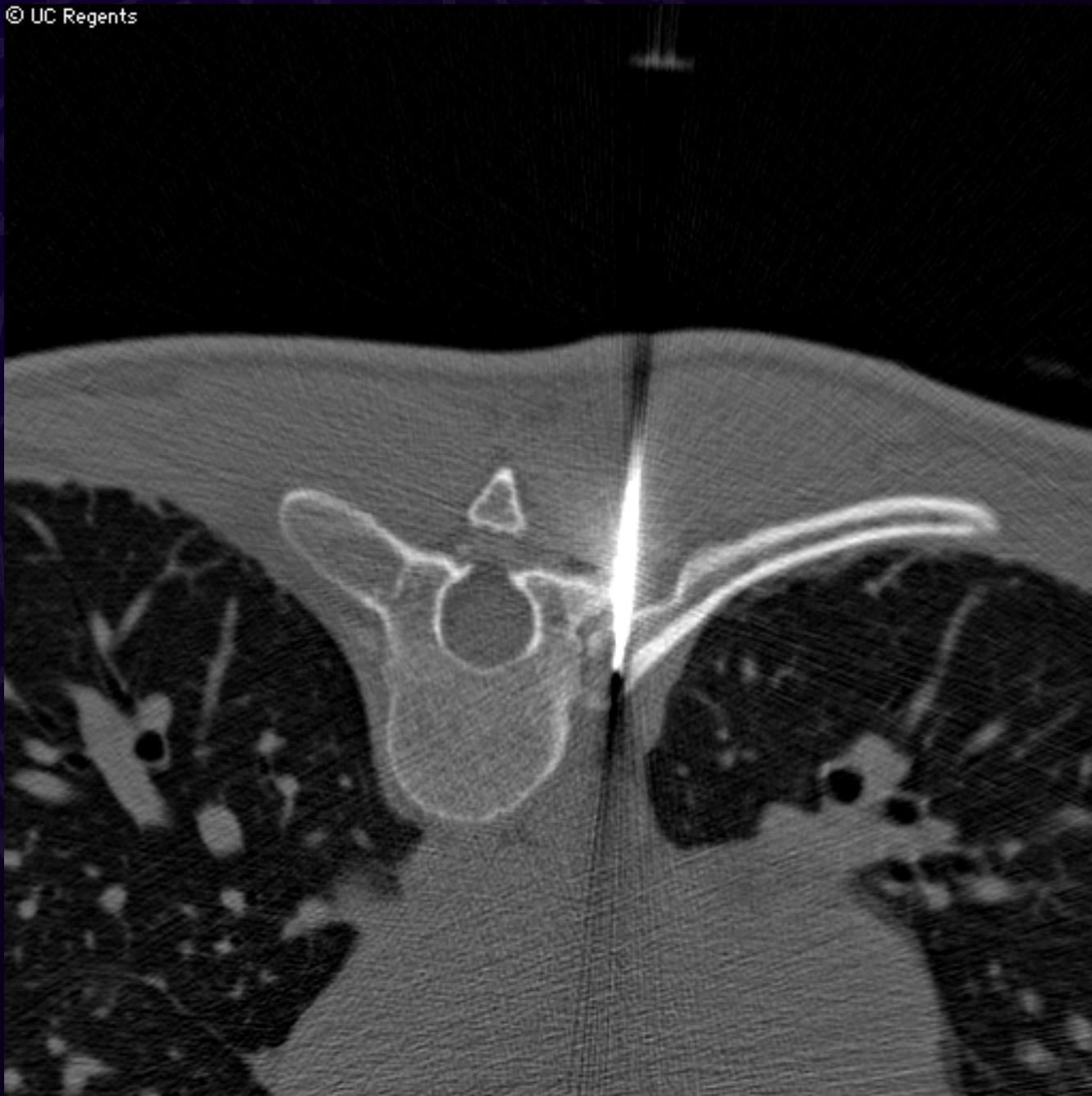


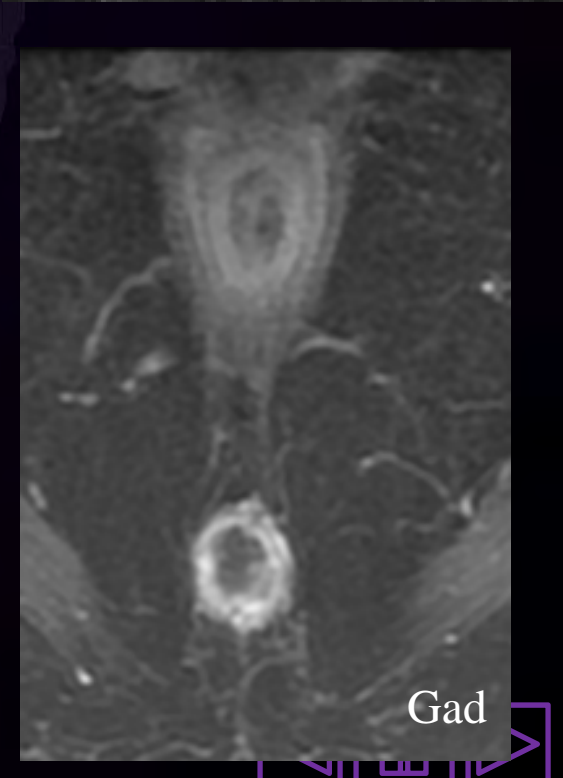
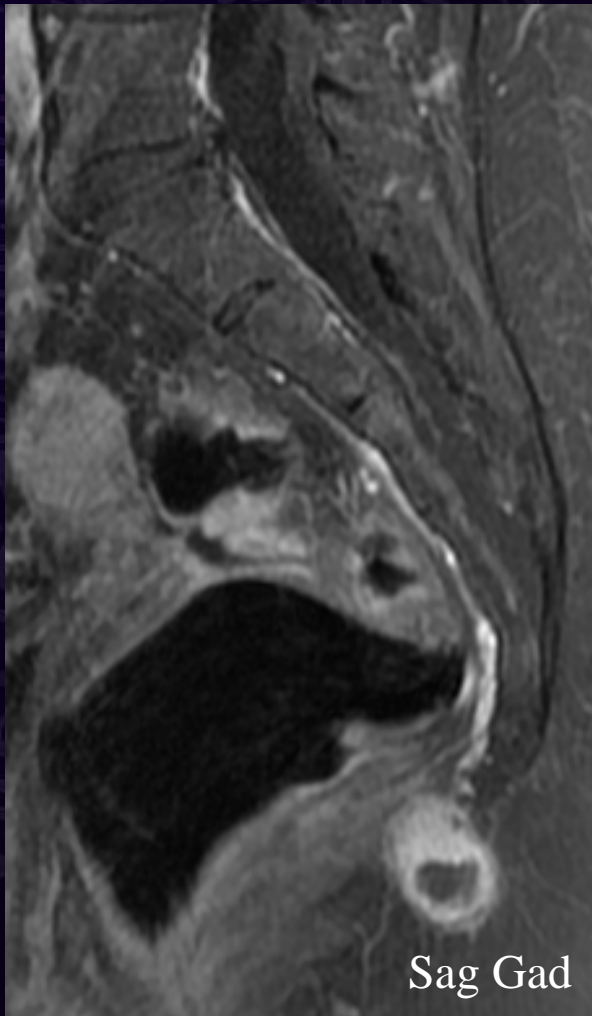
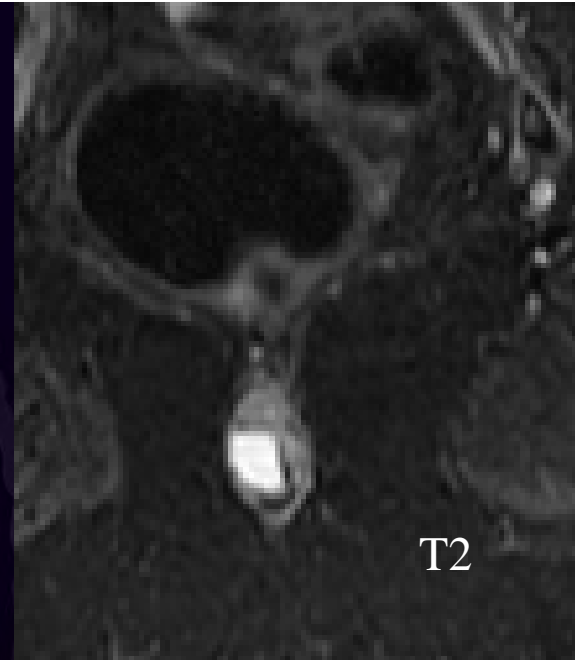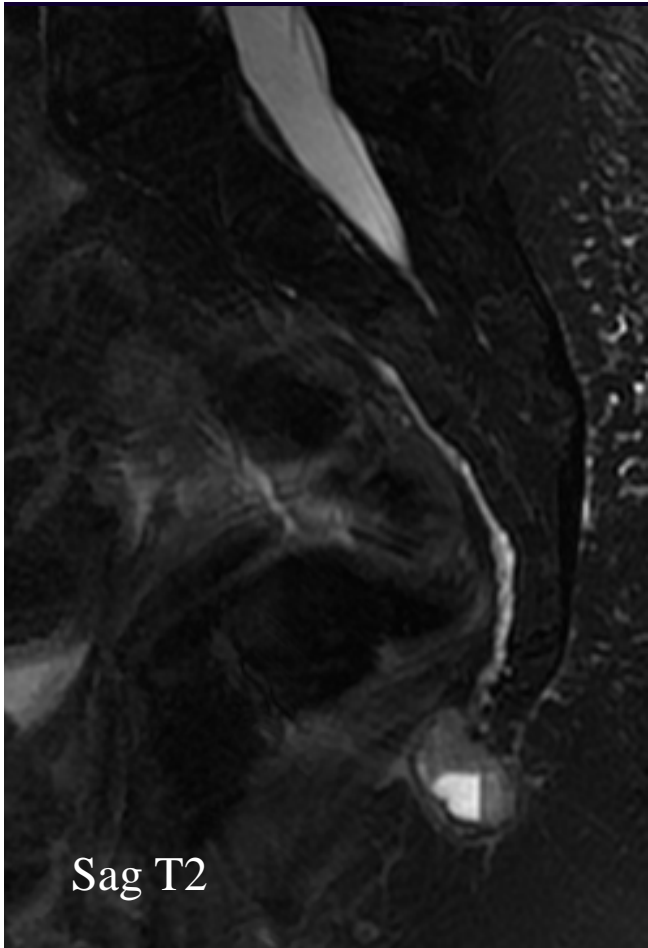






© UC Regents





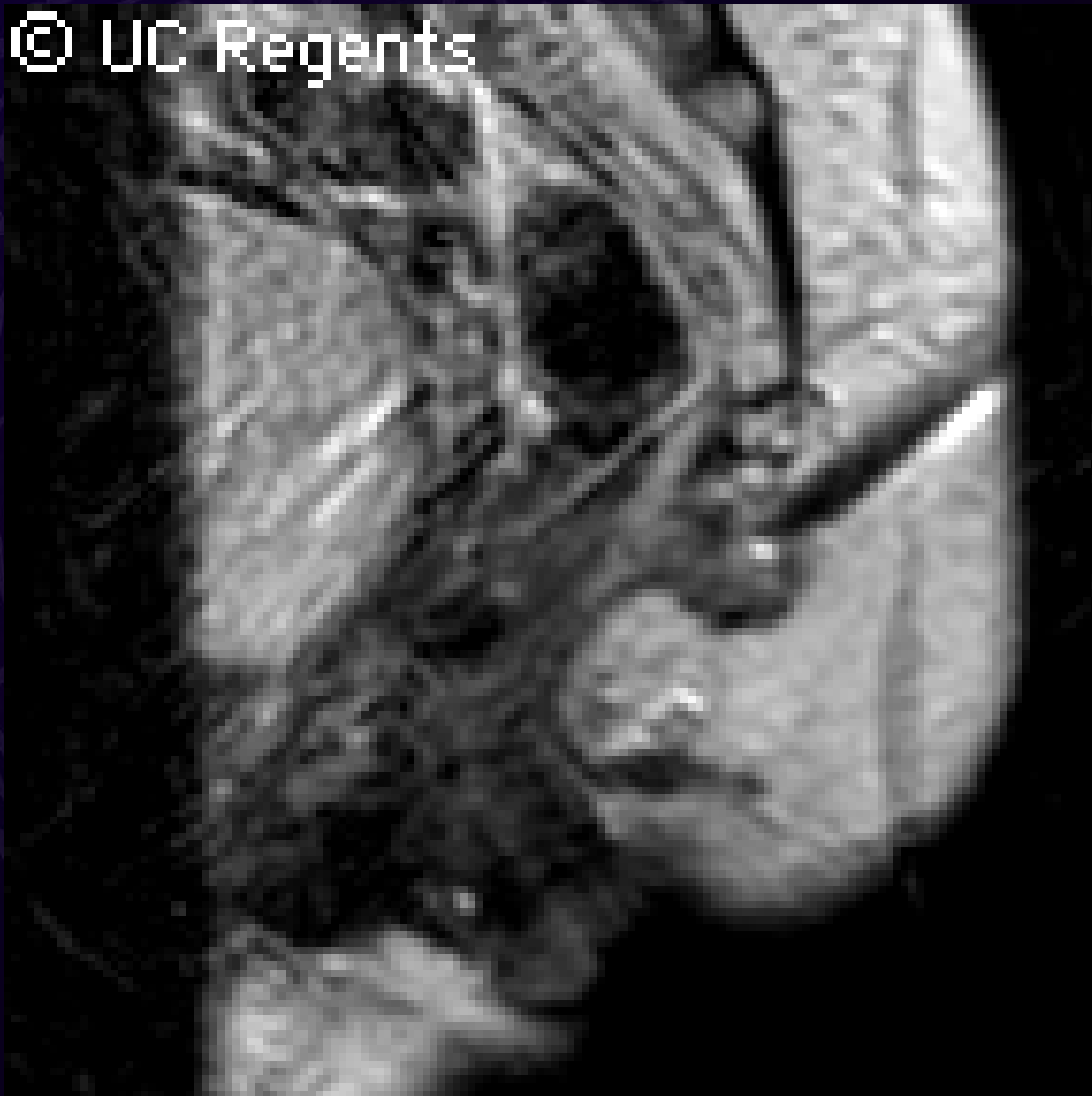CChin

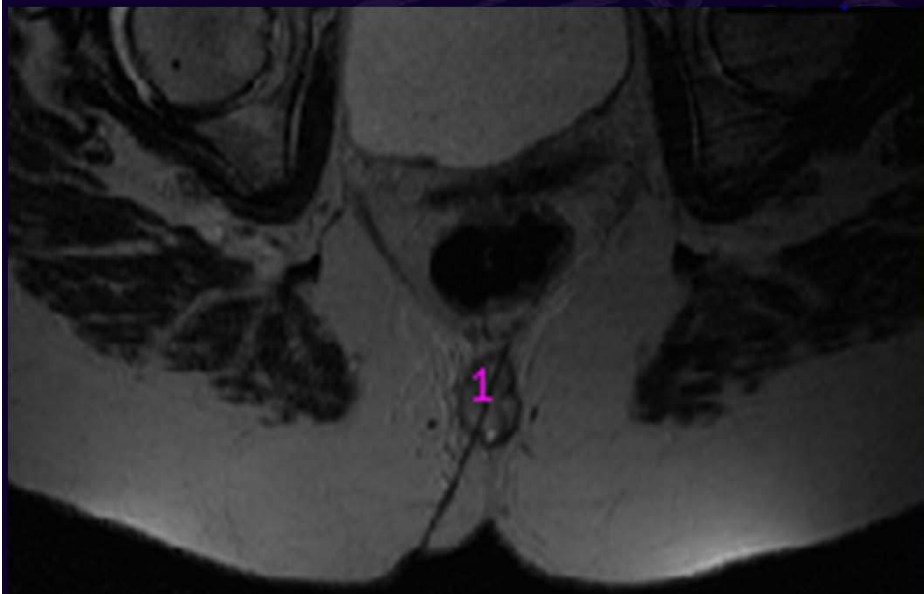
Sag Gad

Gad

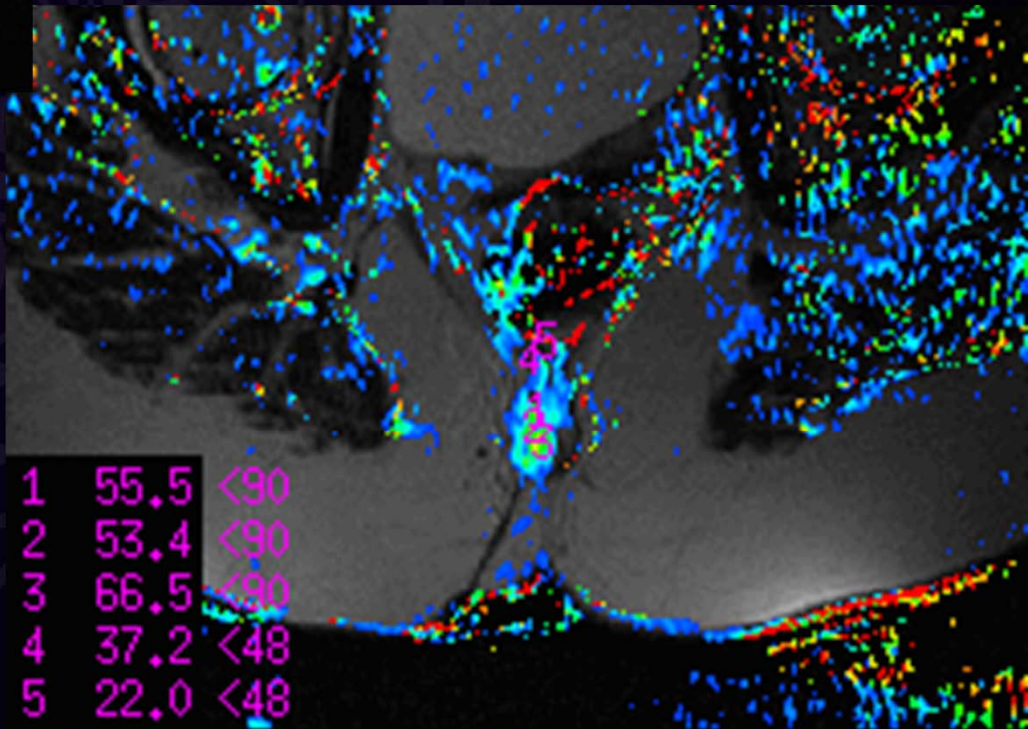


© UC Regents





1 37.0 <90  
0:05 Laser off.

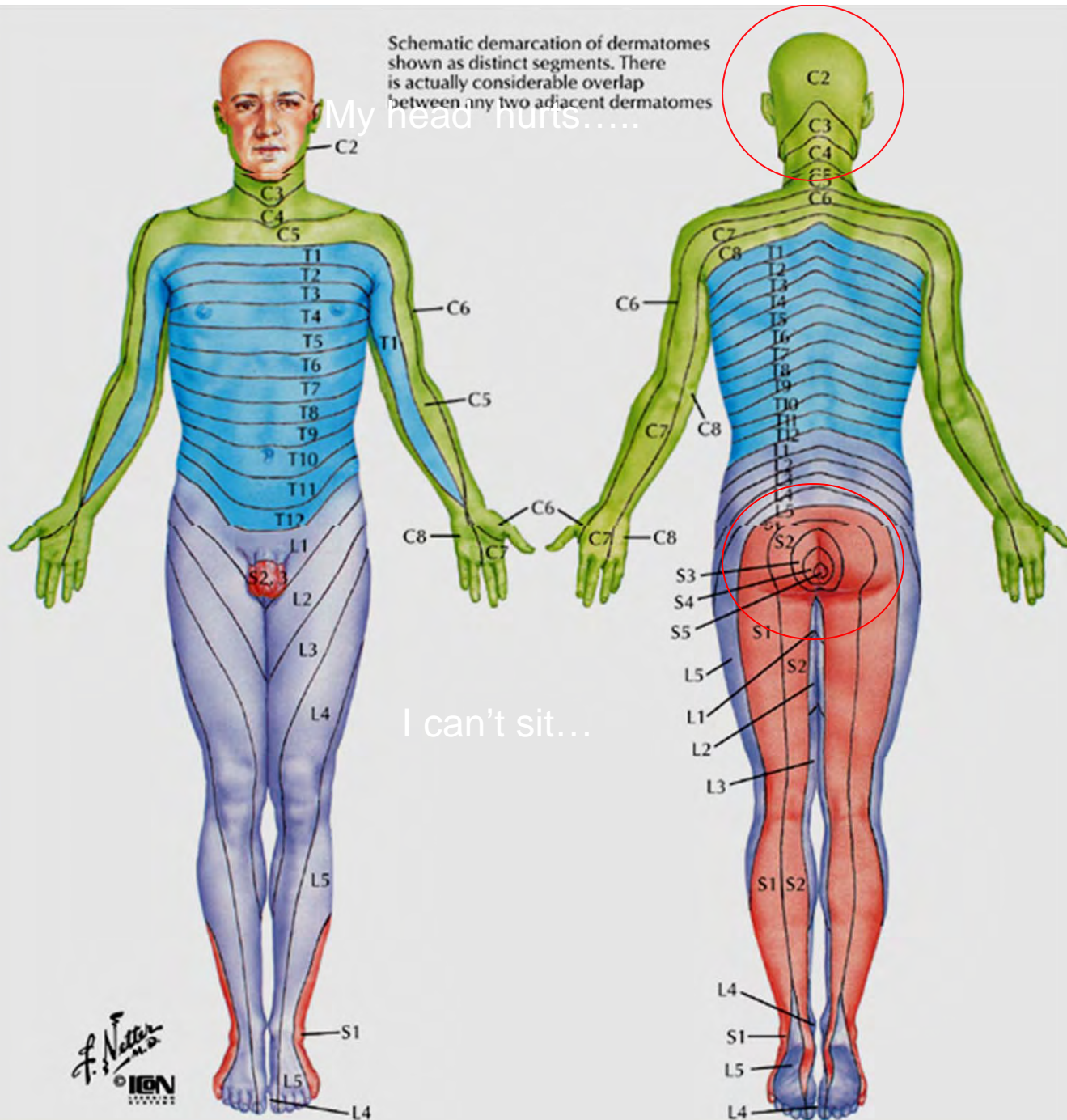


1 55.5 <90  
2 53.4 <90  
3 66.5 <90  
4 37.2 <48  
5 22.0 <48

2:50 Laser Power = 85%

Schematic demarcation of dermatomes shown as distinct segments. There is actually considerable overlap between any two adjacent dermatomes

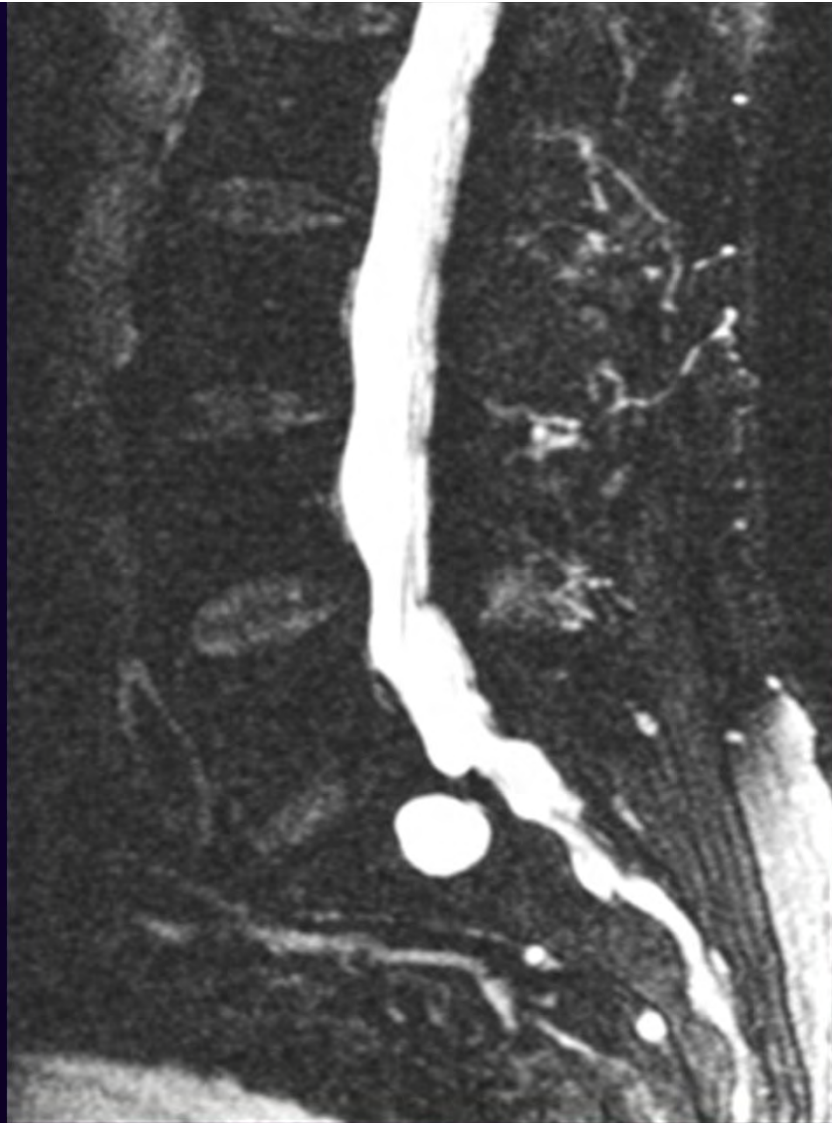My head hurts.....



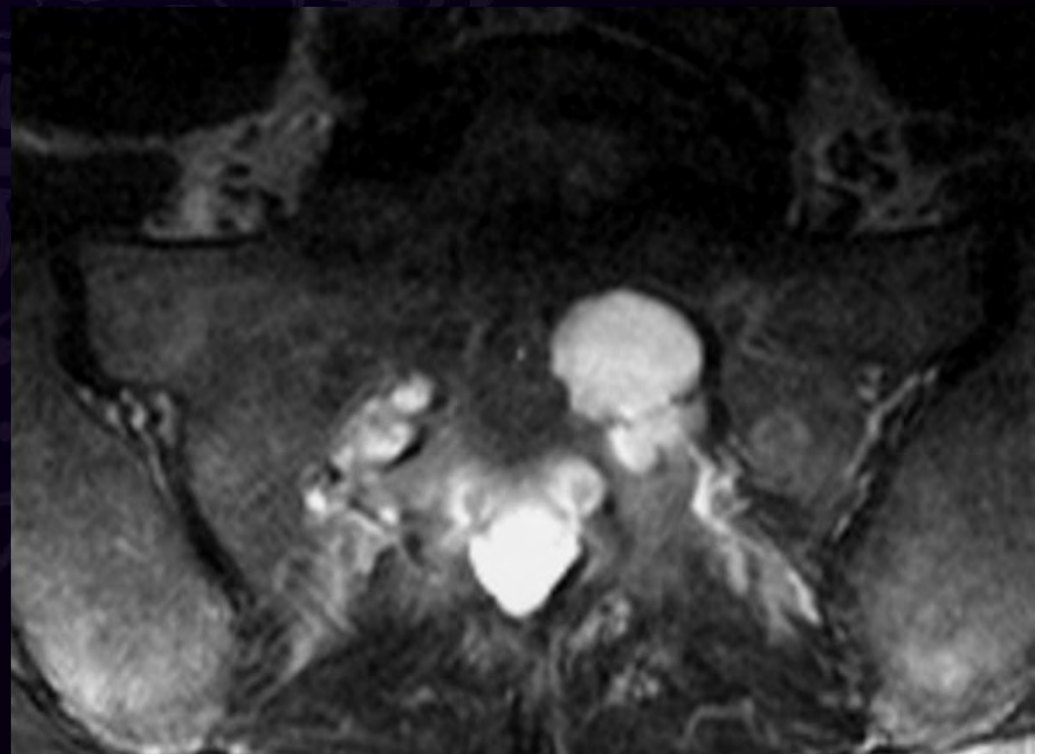
I can't sit...

F. Netter M.D.  
© IGV





Sag STIR



Axial T2

# Isadore M. Tarlov

1905-1970

Neurosurgeon

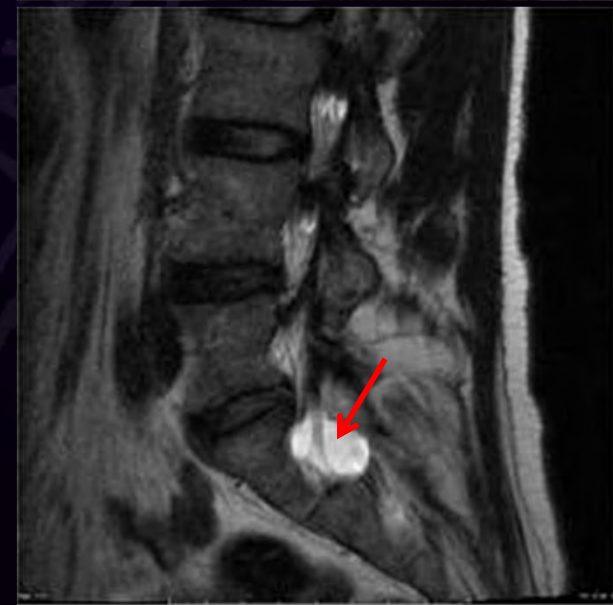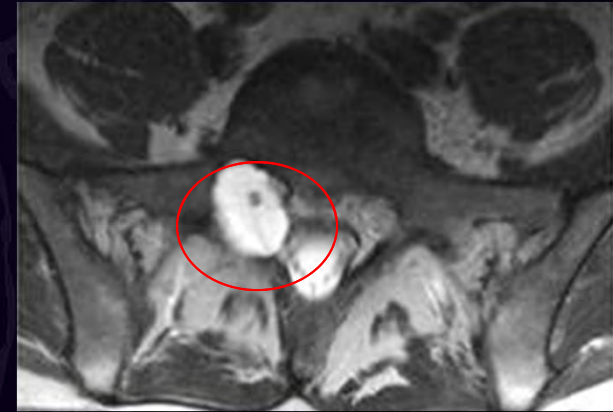
1938

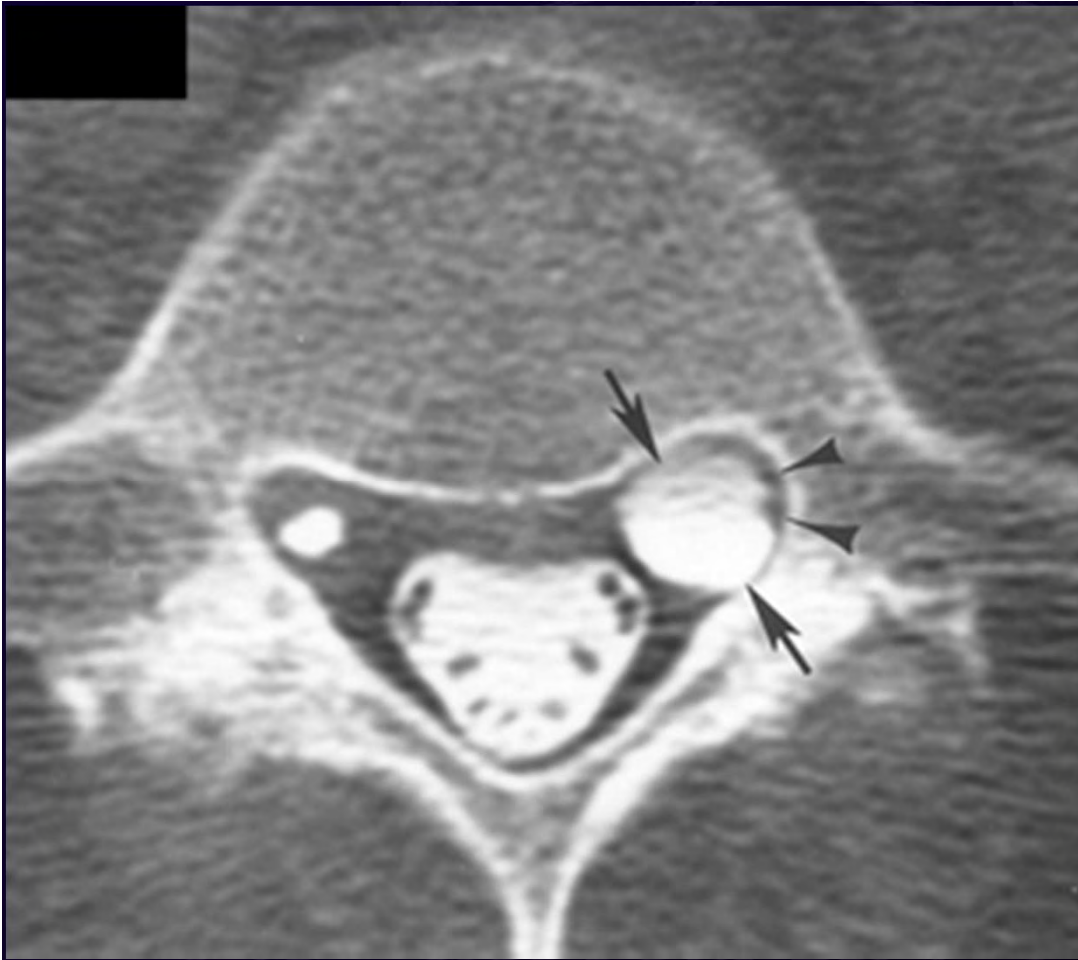
Incidental finding in  
study of filum structure



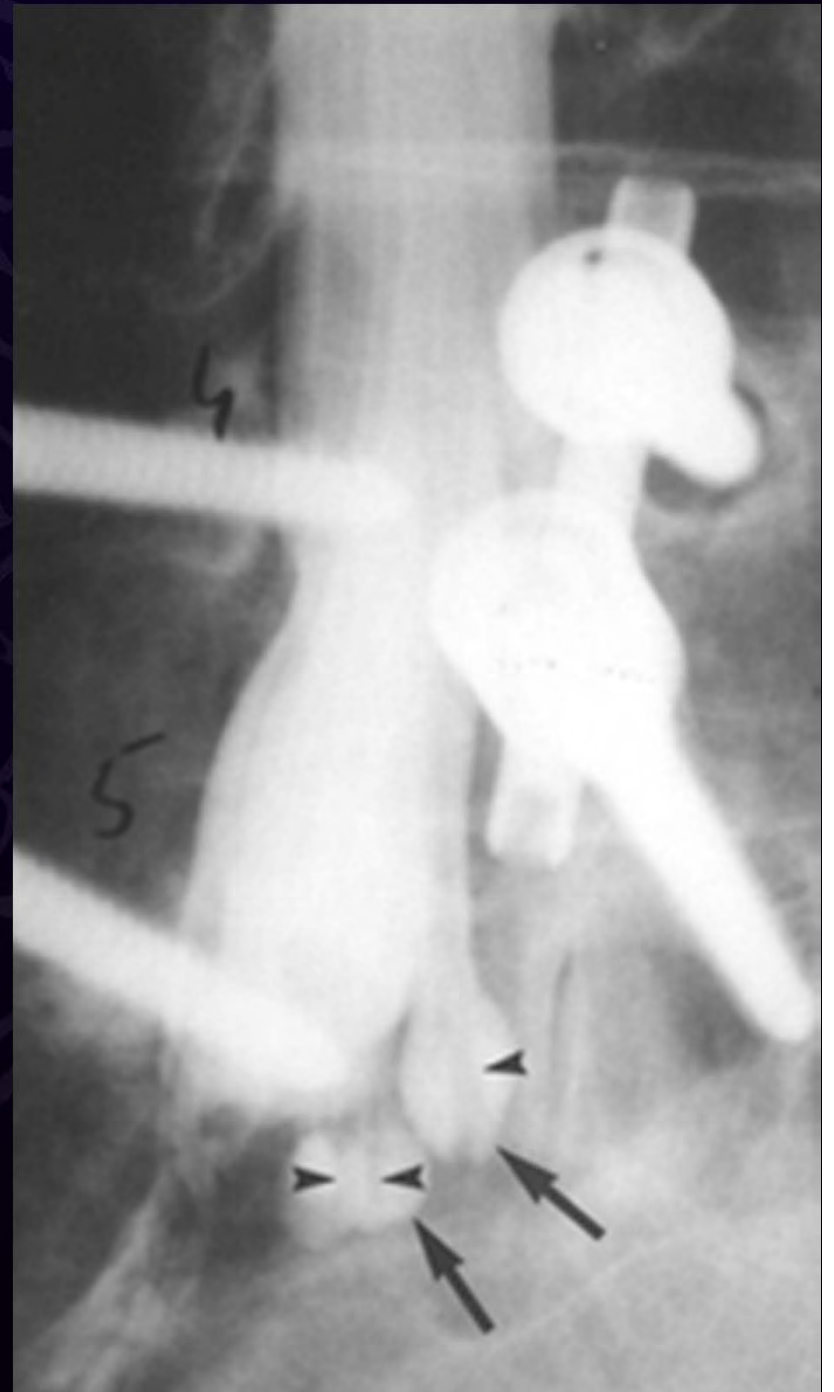
# Tarlov Cyst

- Meningeal cysts spinal nerve root fibers
- nerve root sheath at DRG
- Ball valve theory – sxs
- Etiology – inflammation trauma congenital?

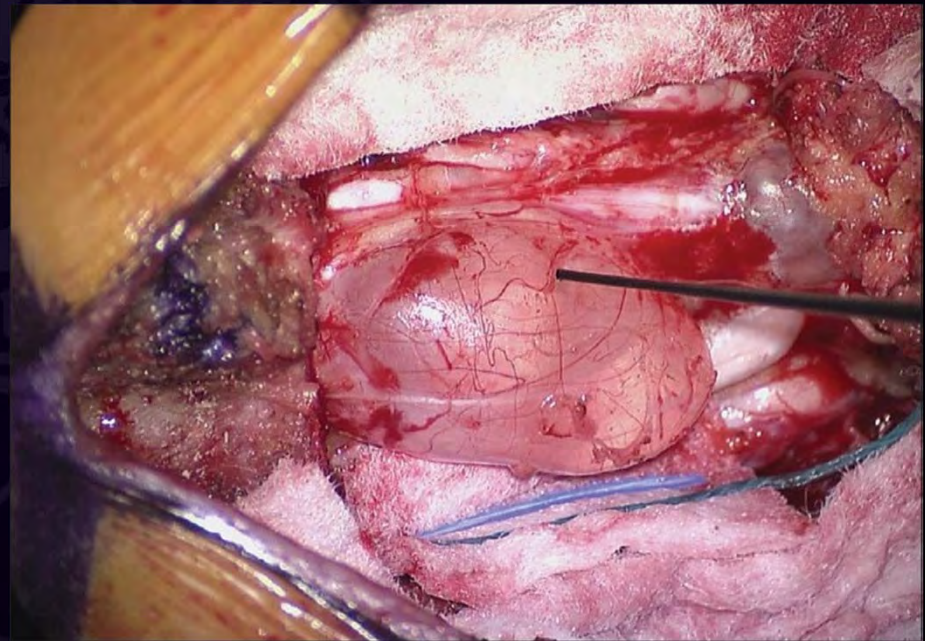
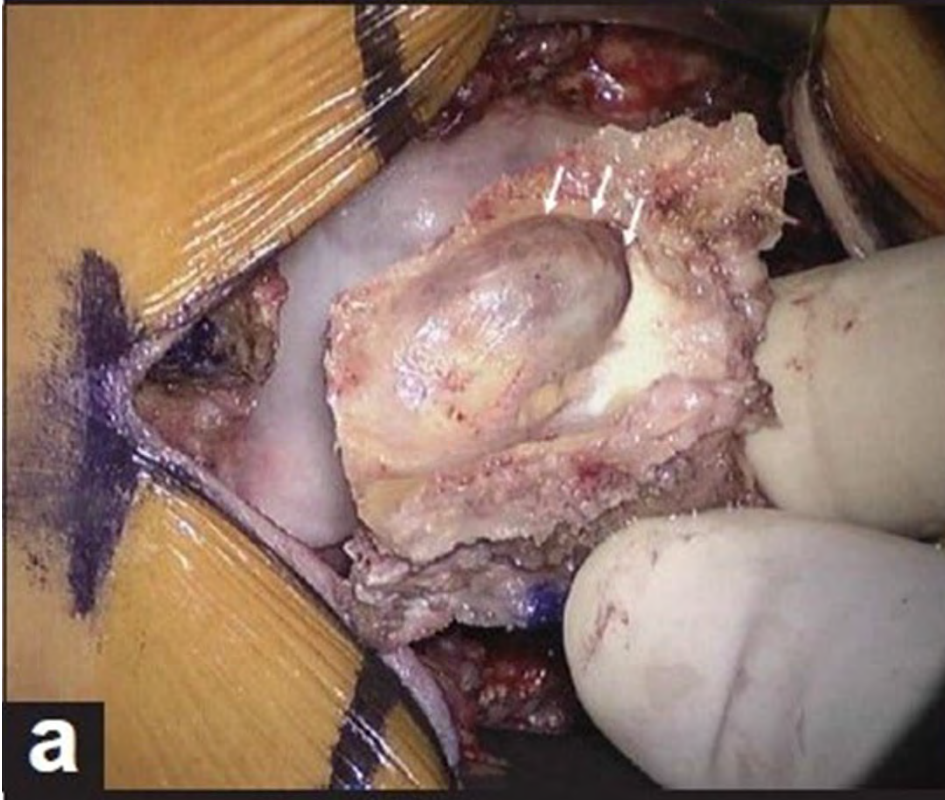



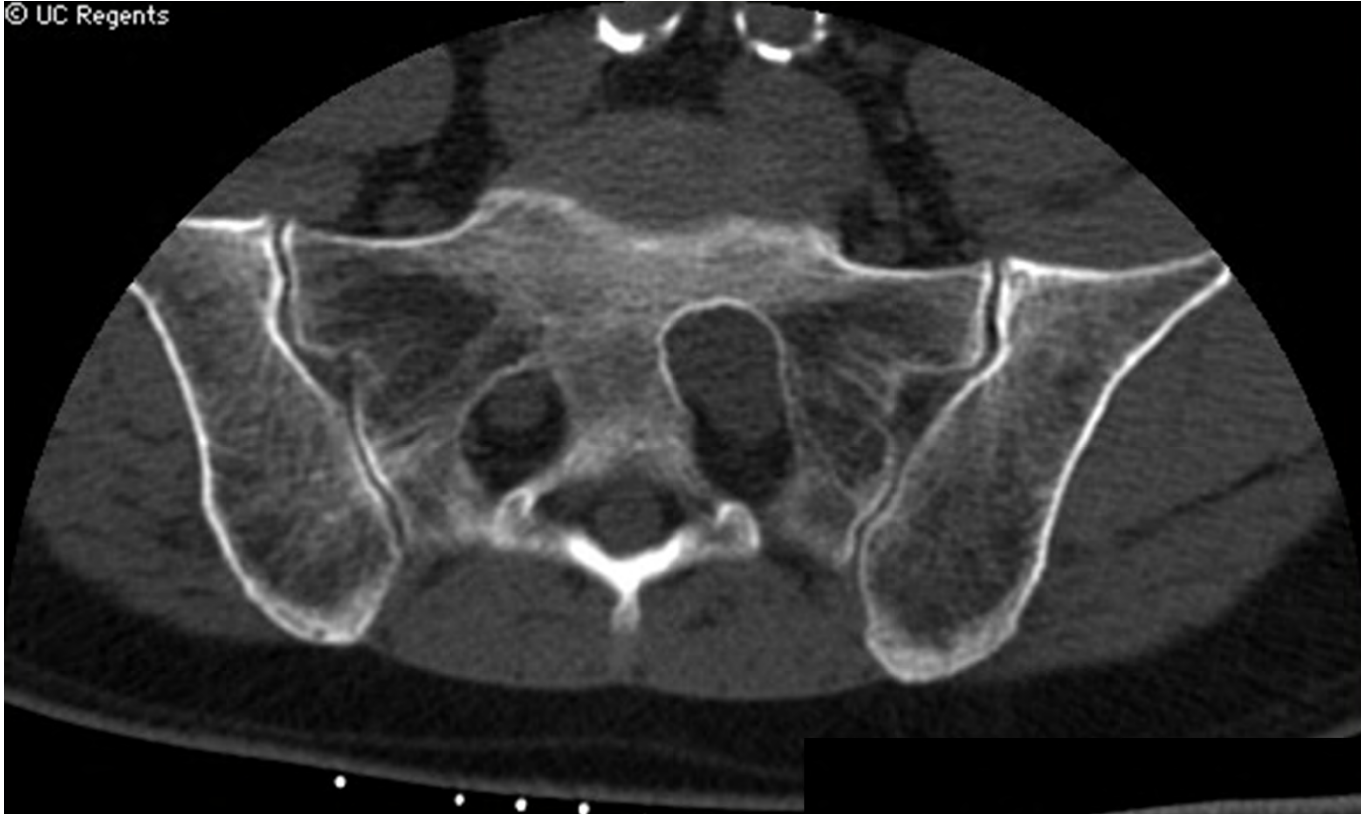
Khosla A JR 2002



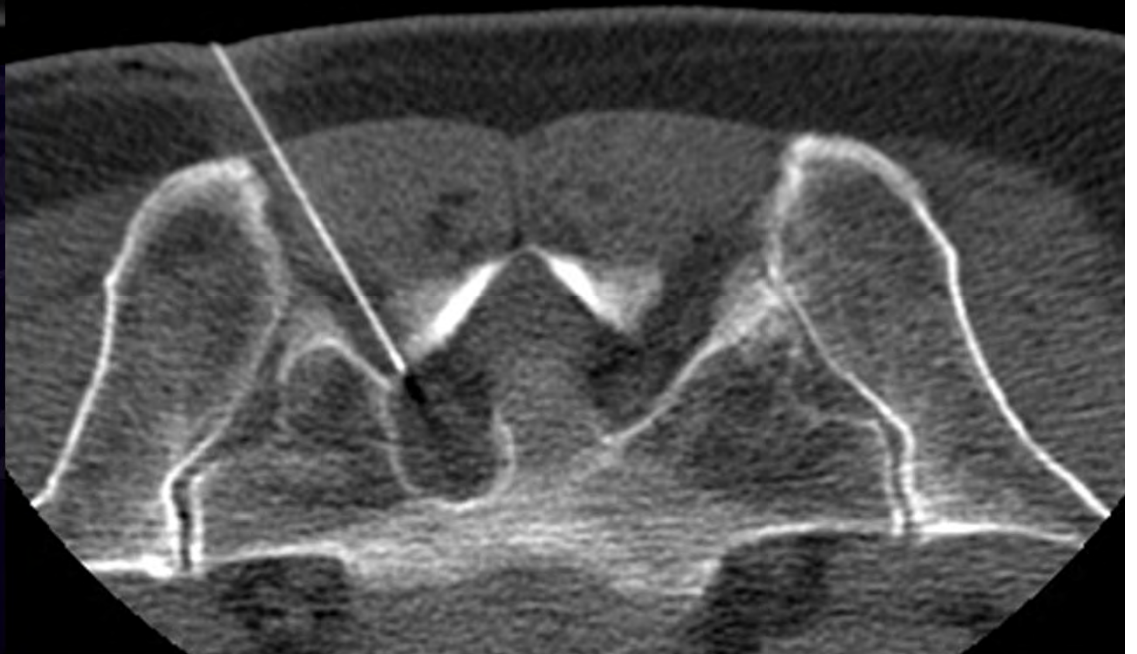
# Tarlov Cyst

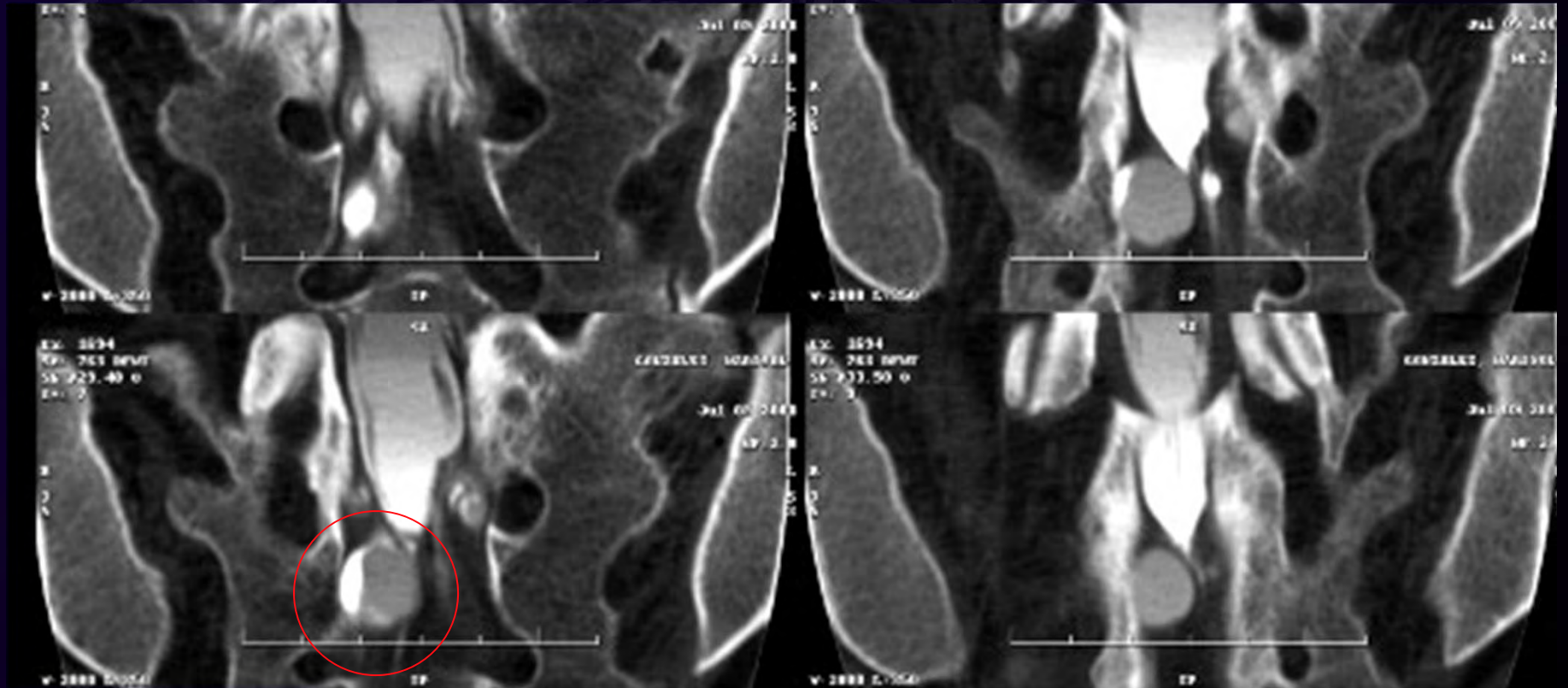






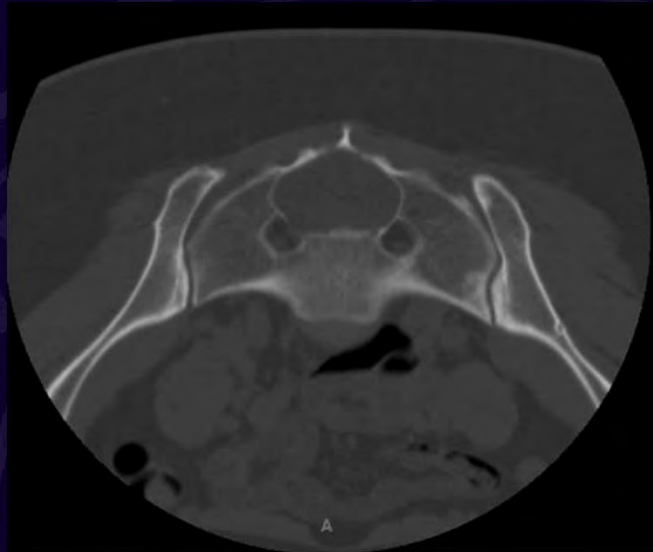
S1 Nerve Block



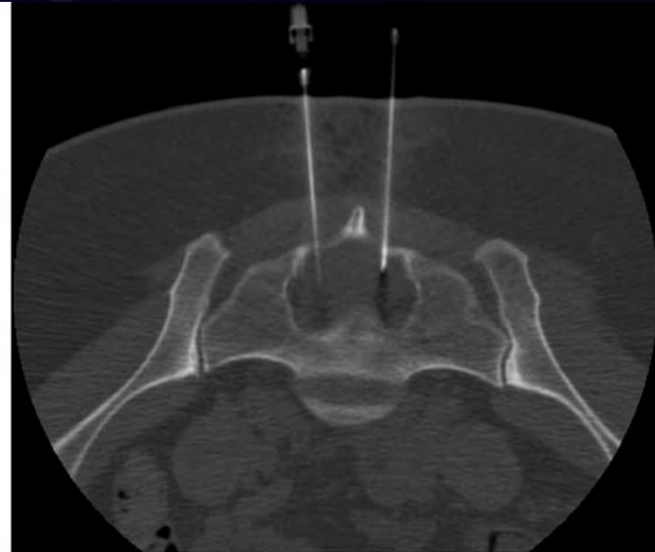

Myelogram

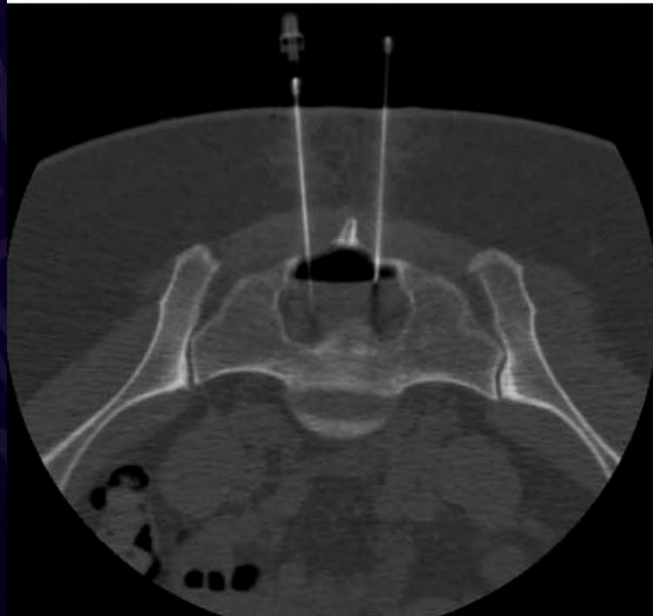



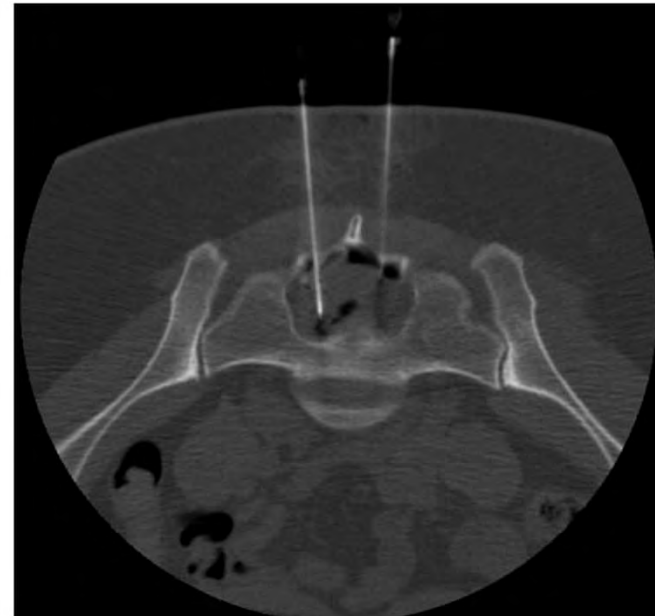a.



b.



c.

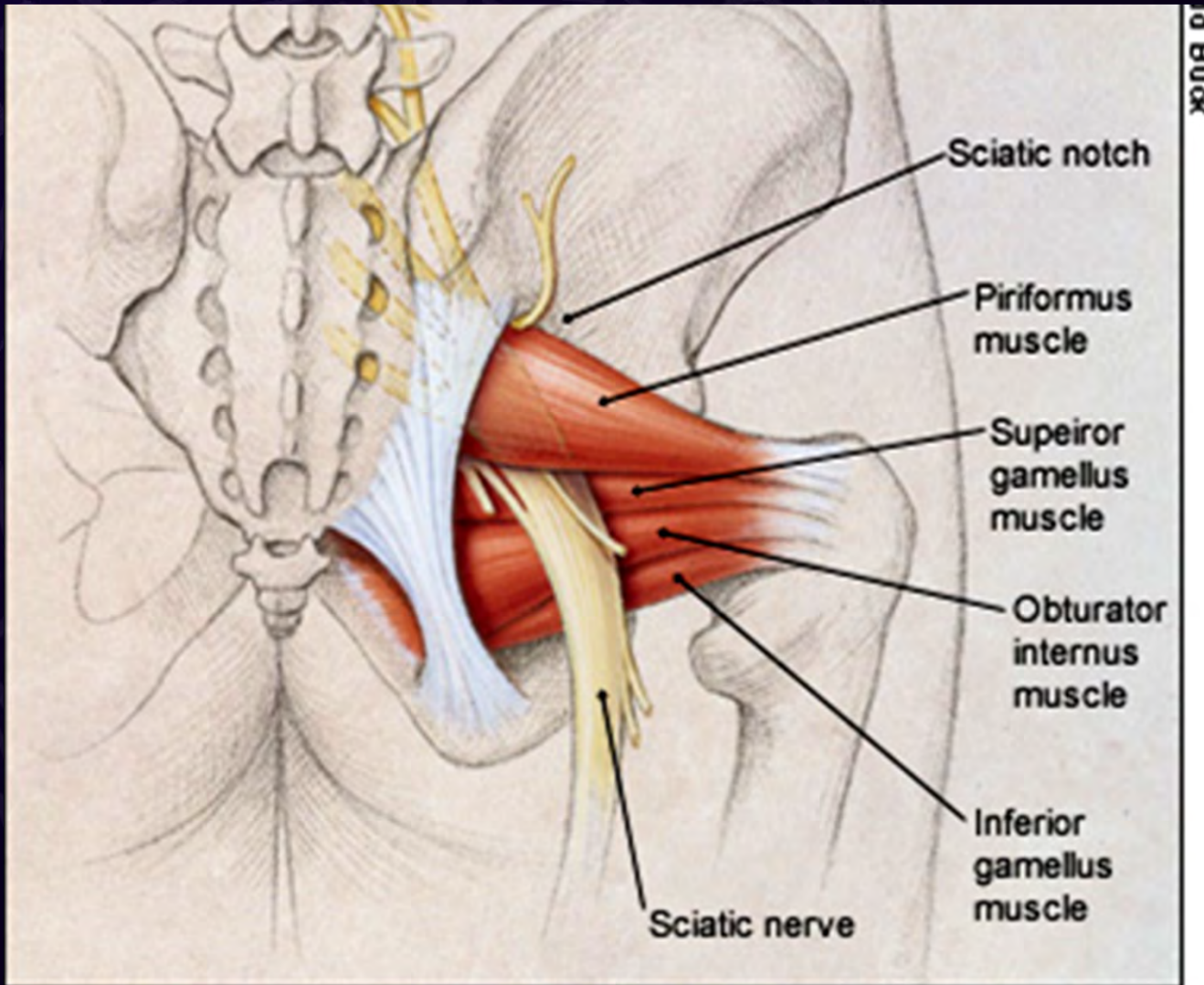


d.

Murphy K J Vasc Interv Rad 2008

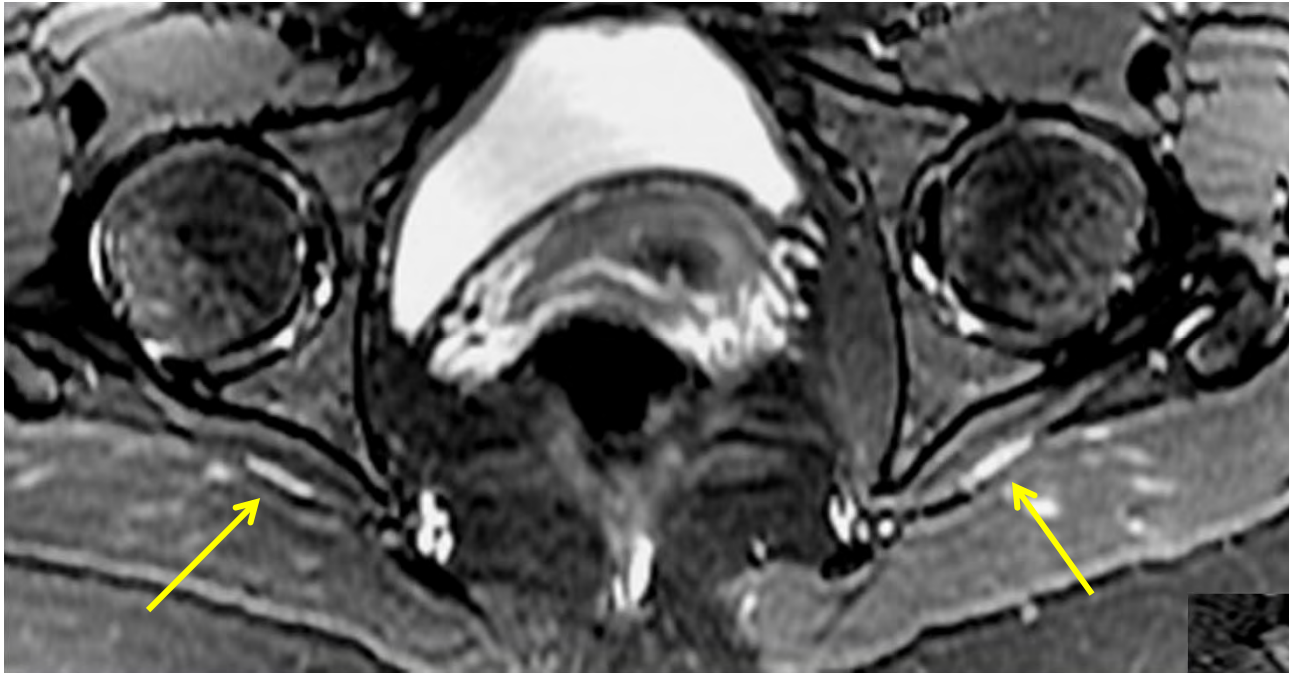

# Extraspinal Sciatica

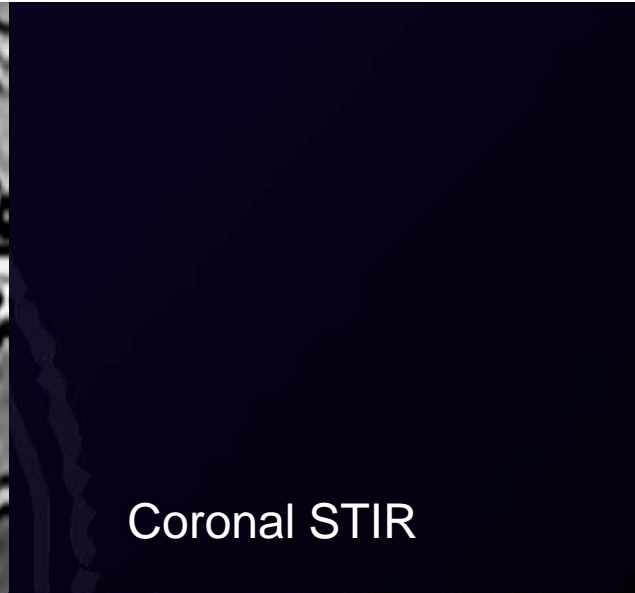


American Family Physician, 1 April, 2000;  
61(7):2109-18.

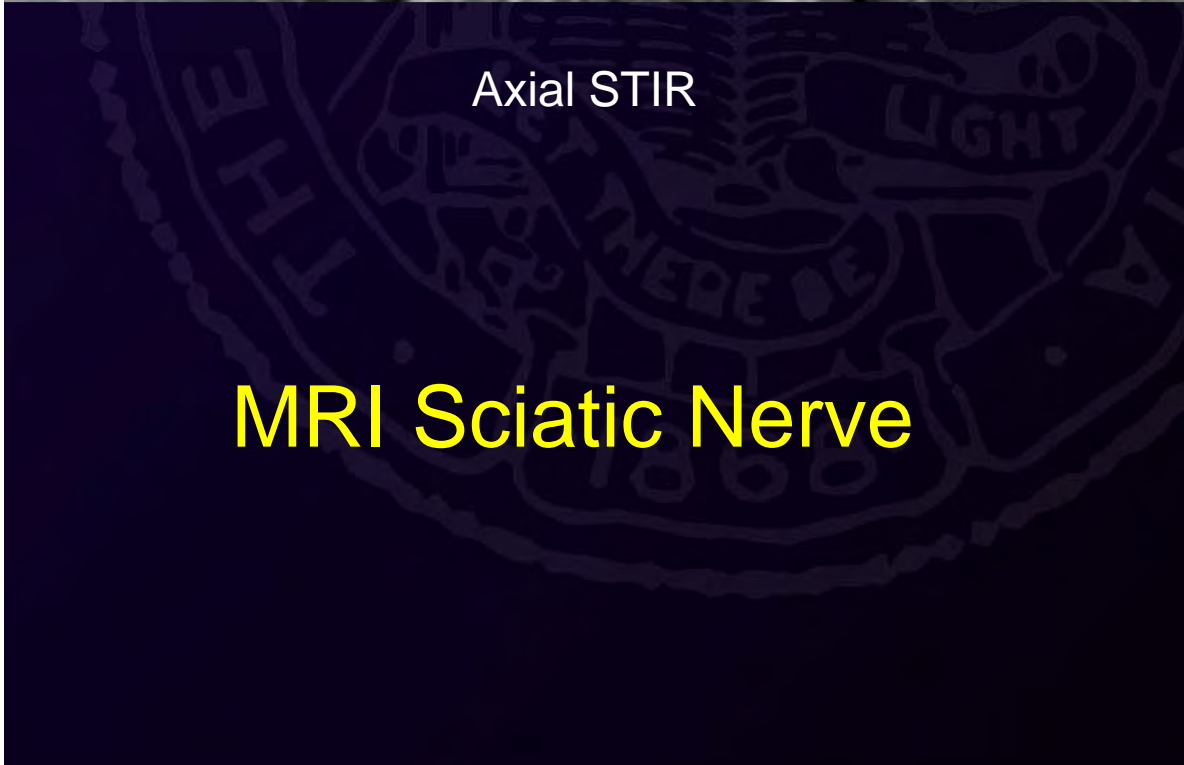



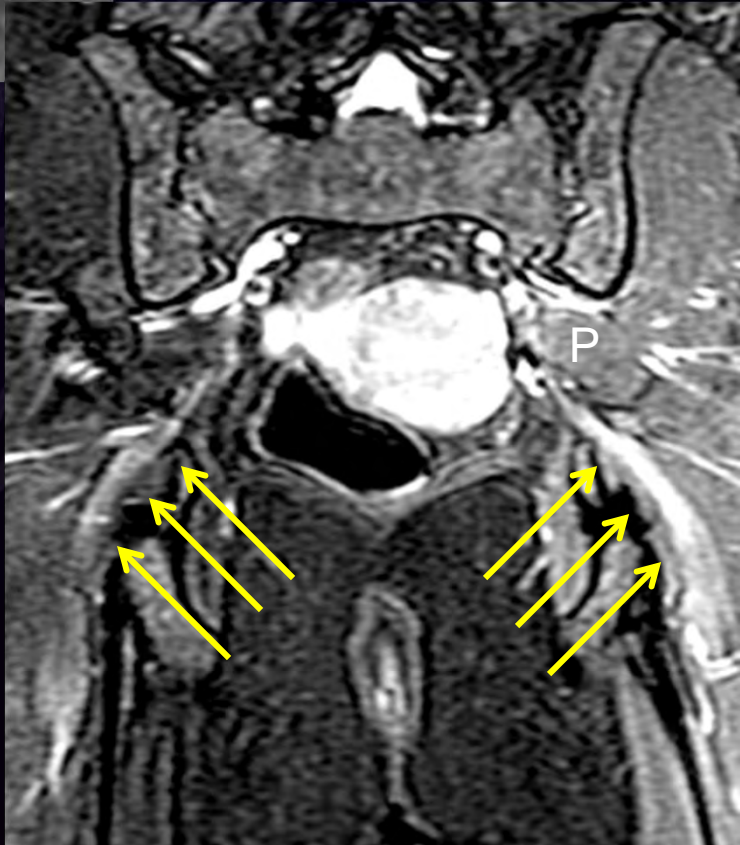
Axial STIR

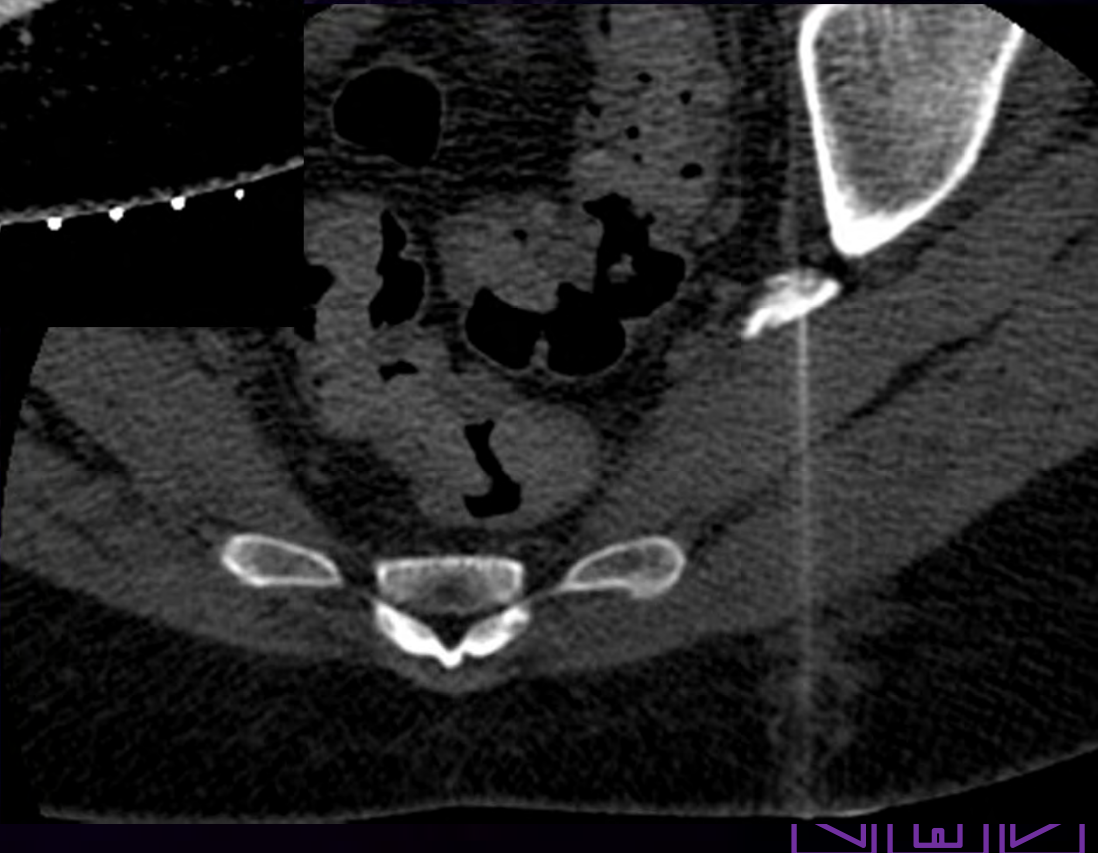
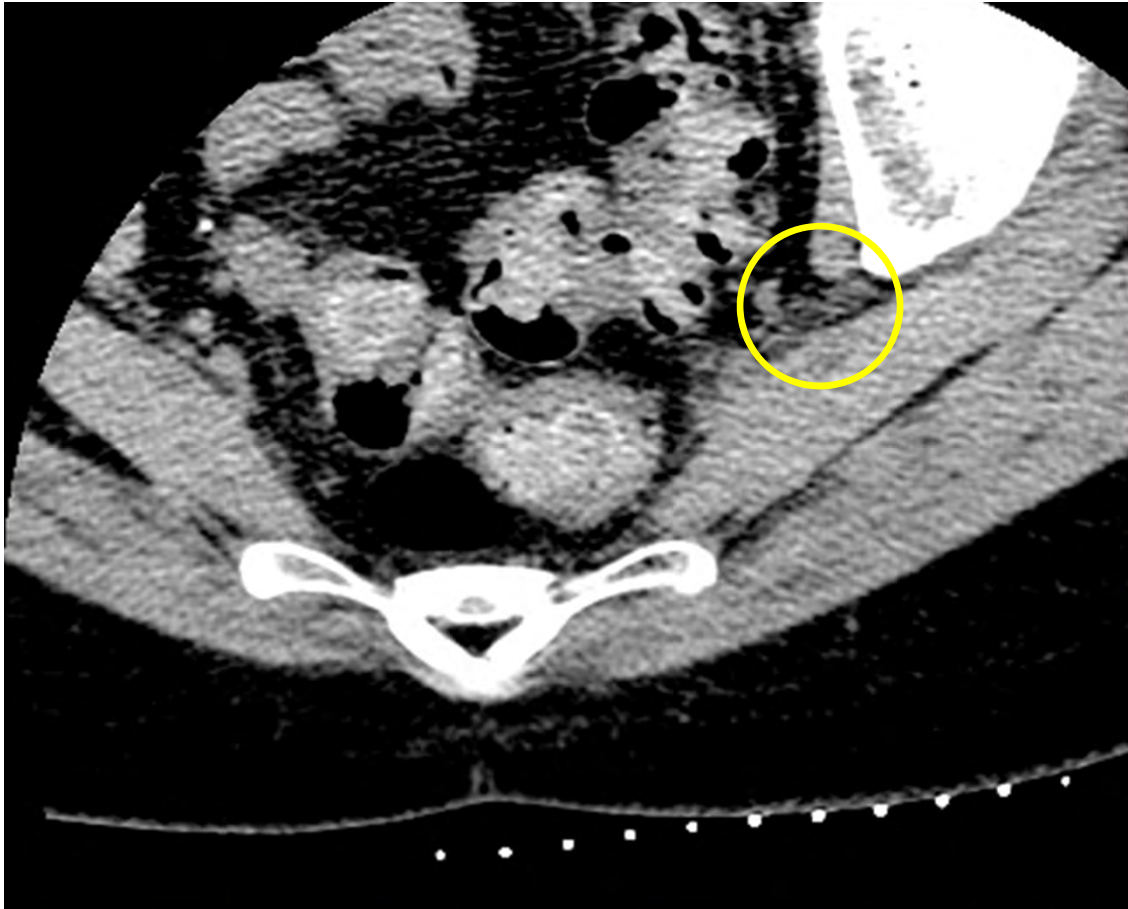


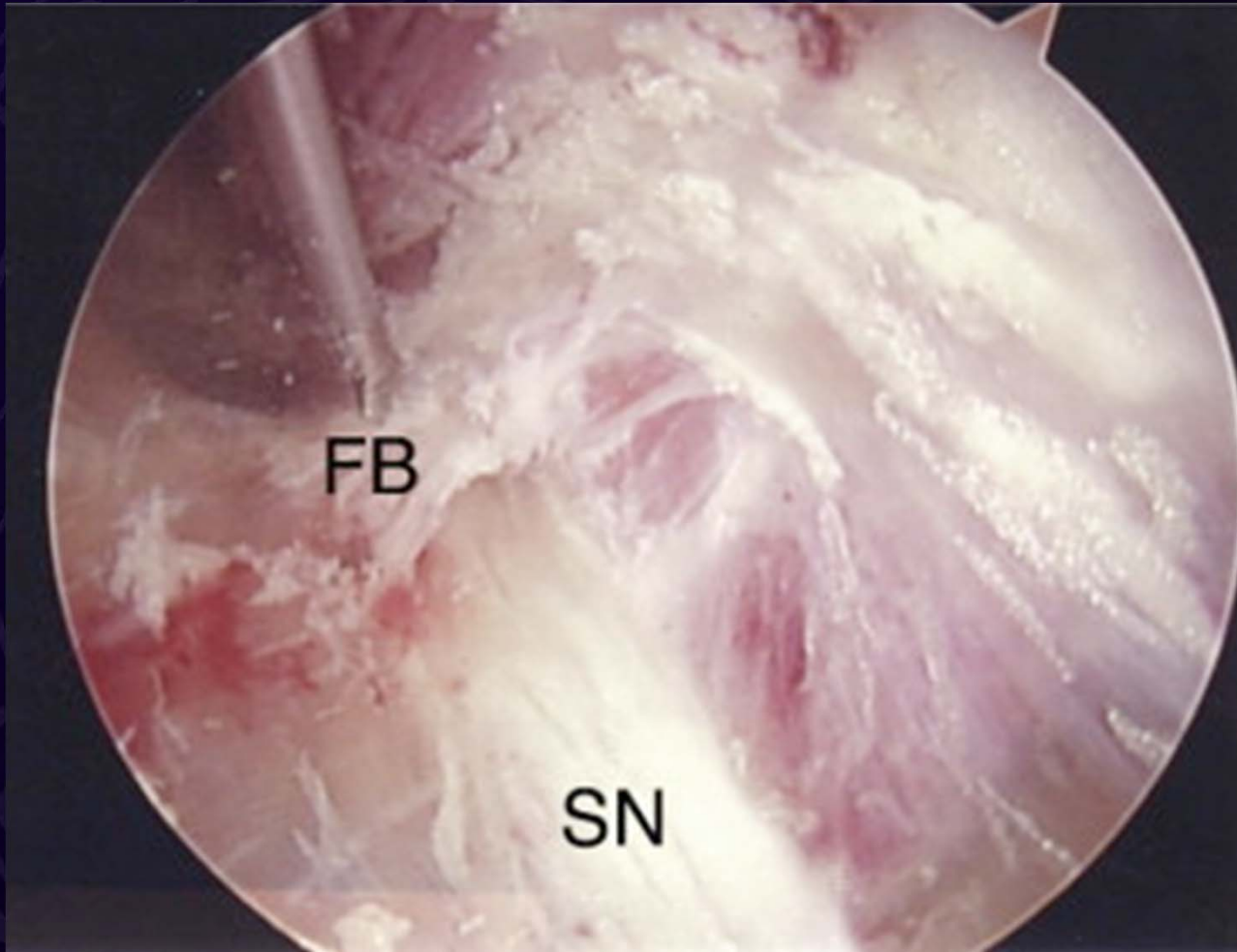
Coronal STIR



# MRI Sciatic Nerve

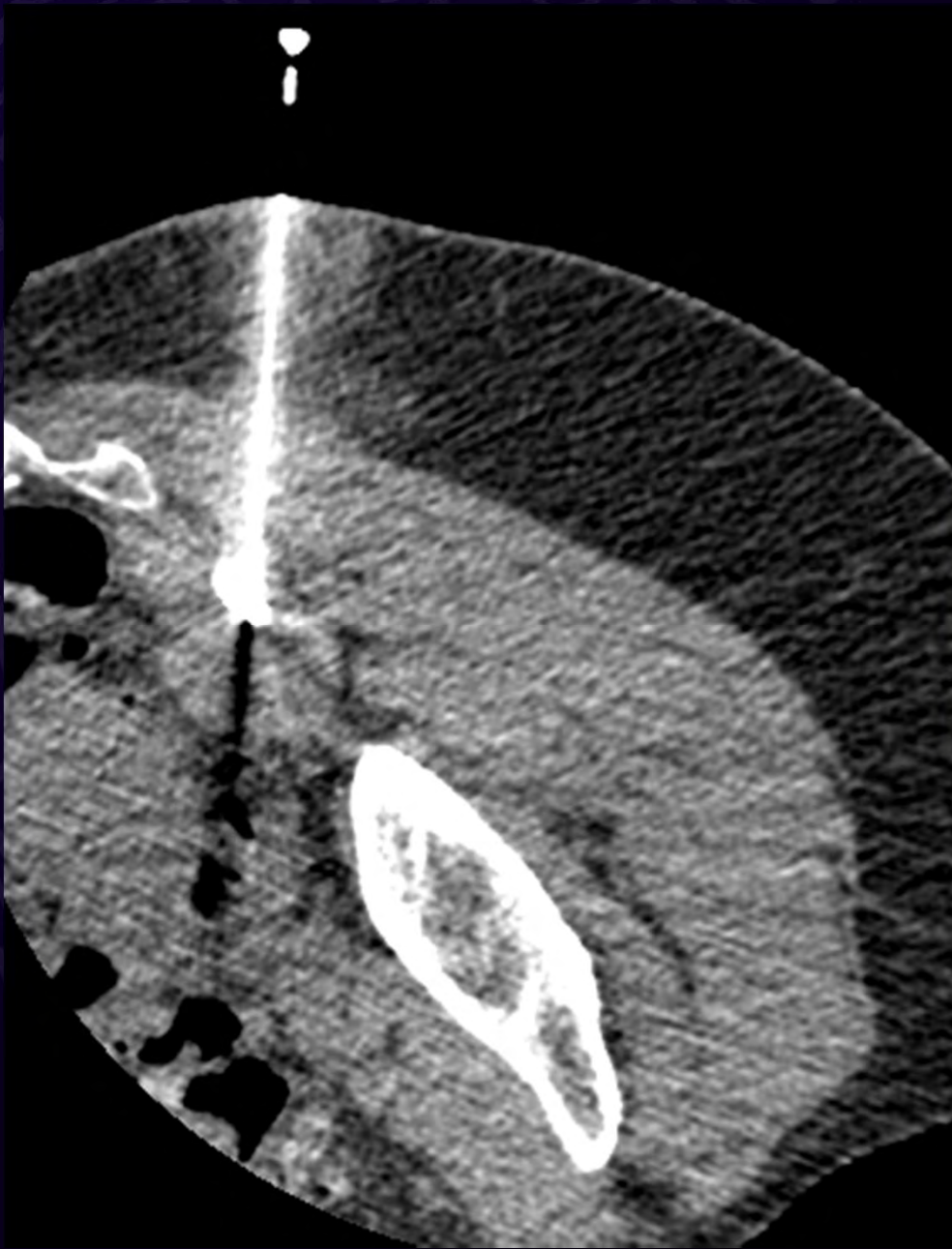






Martin HD 2011





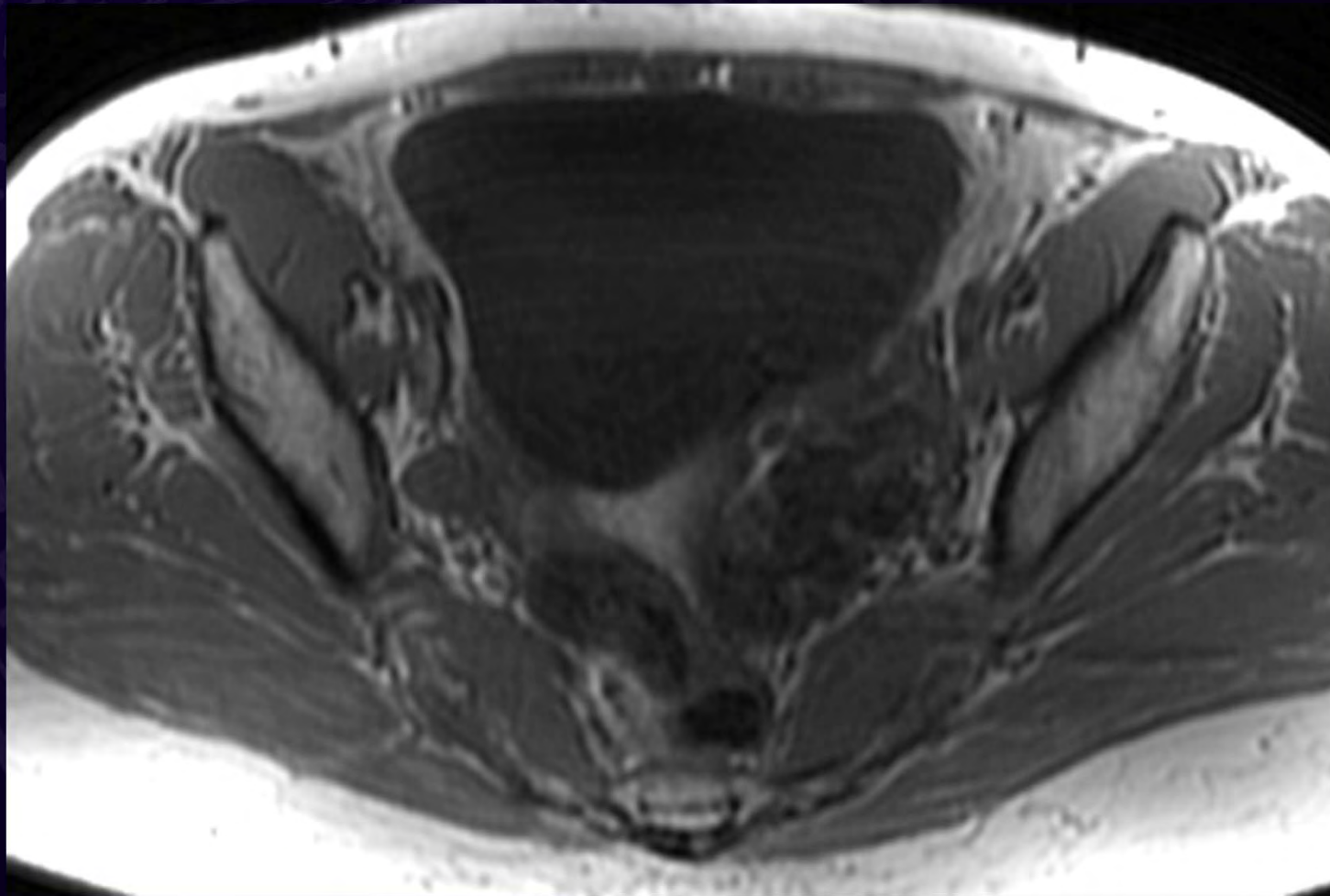
Piriformis Block

Anesthetic  
Steroid  
Botox

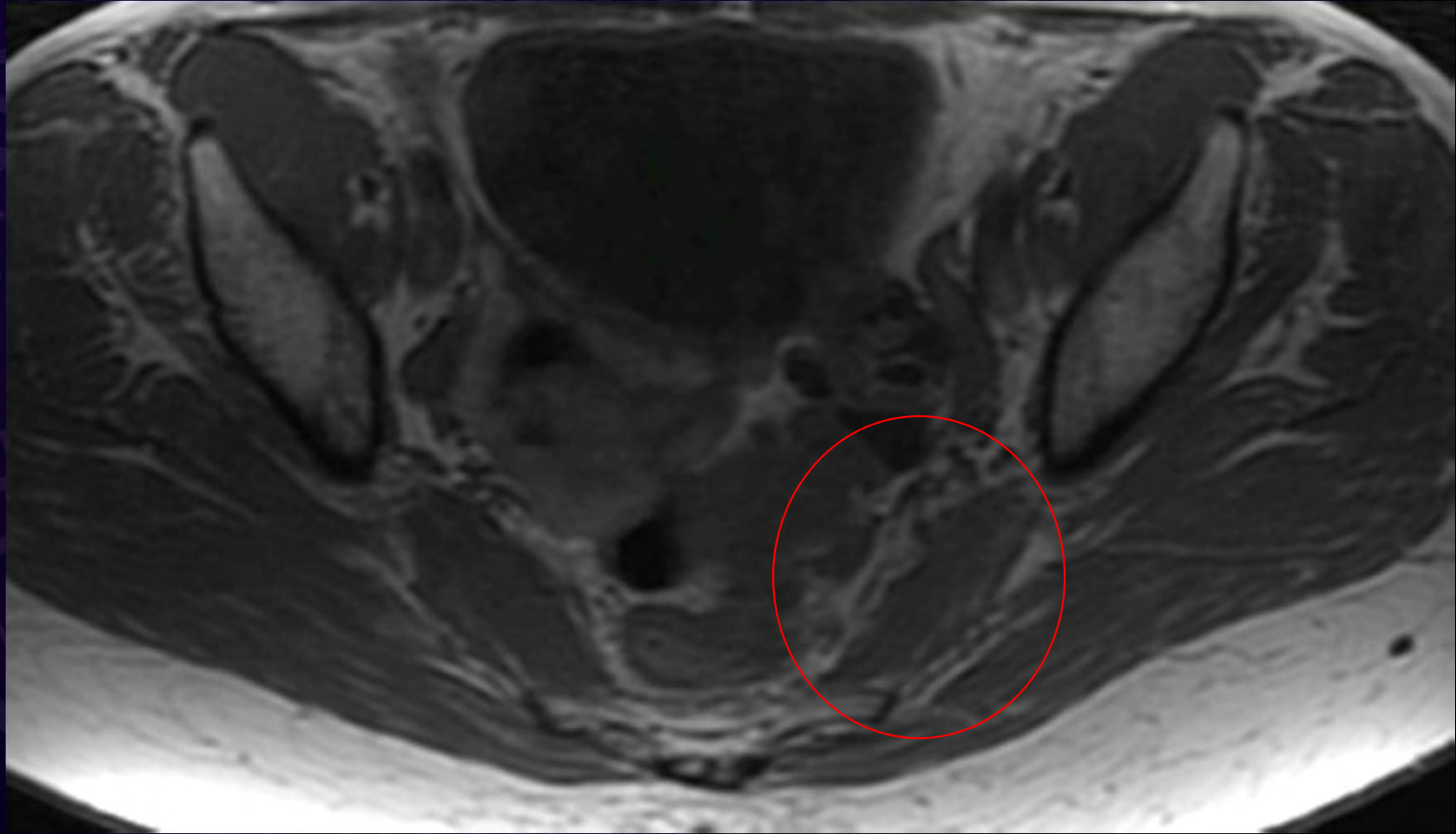




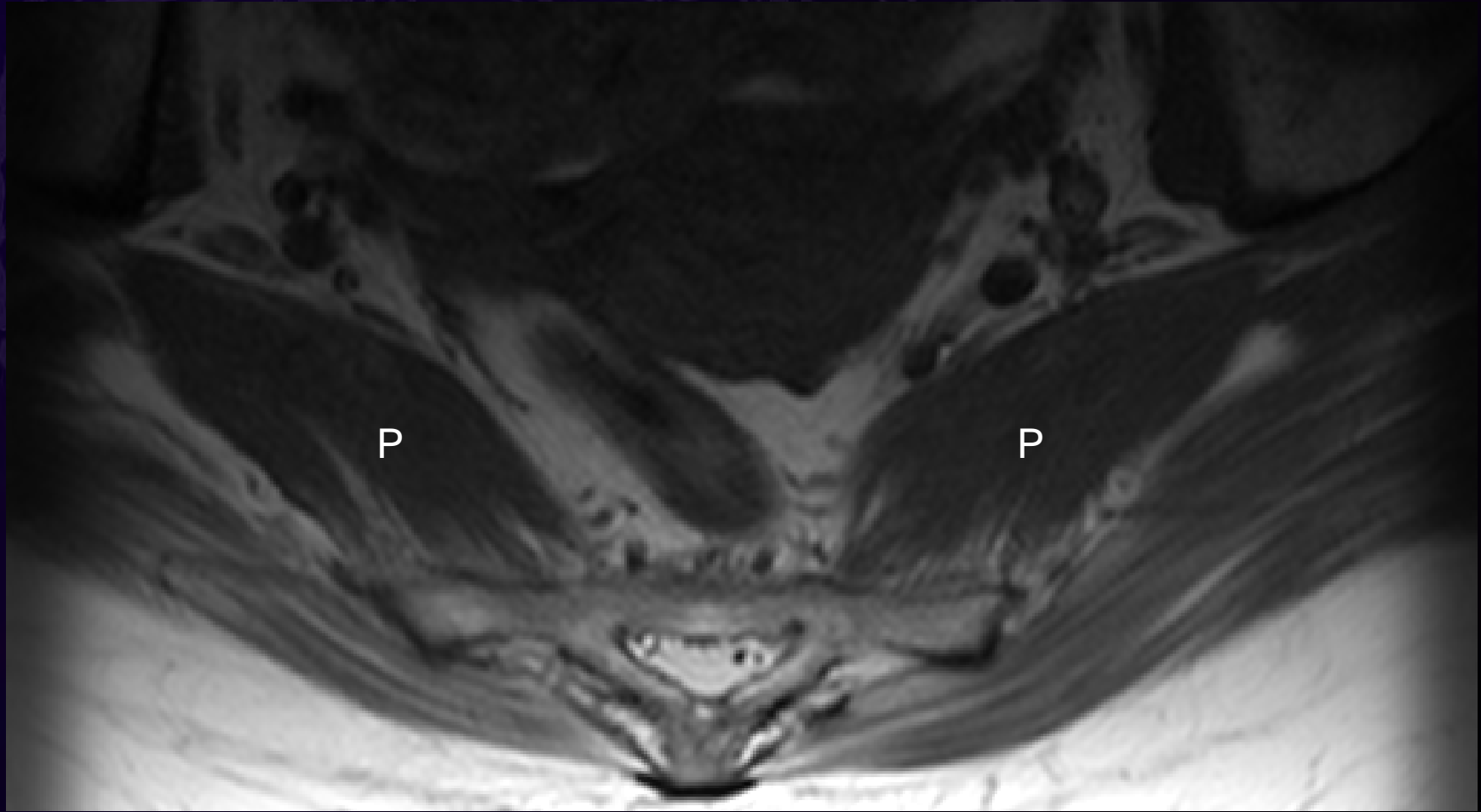
Pre-injection



# Post-injection - atrophy



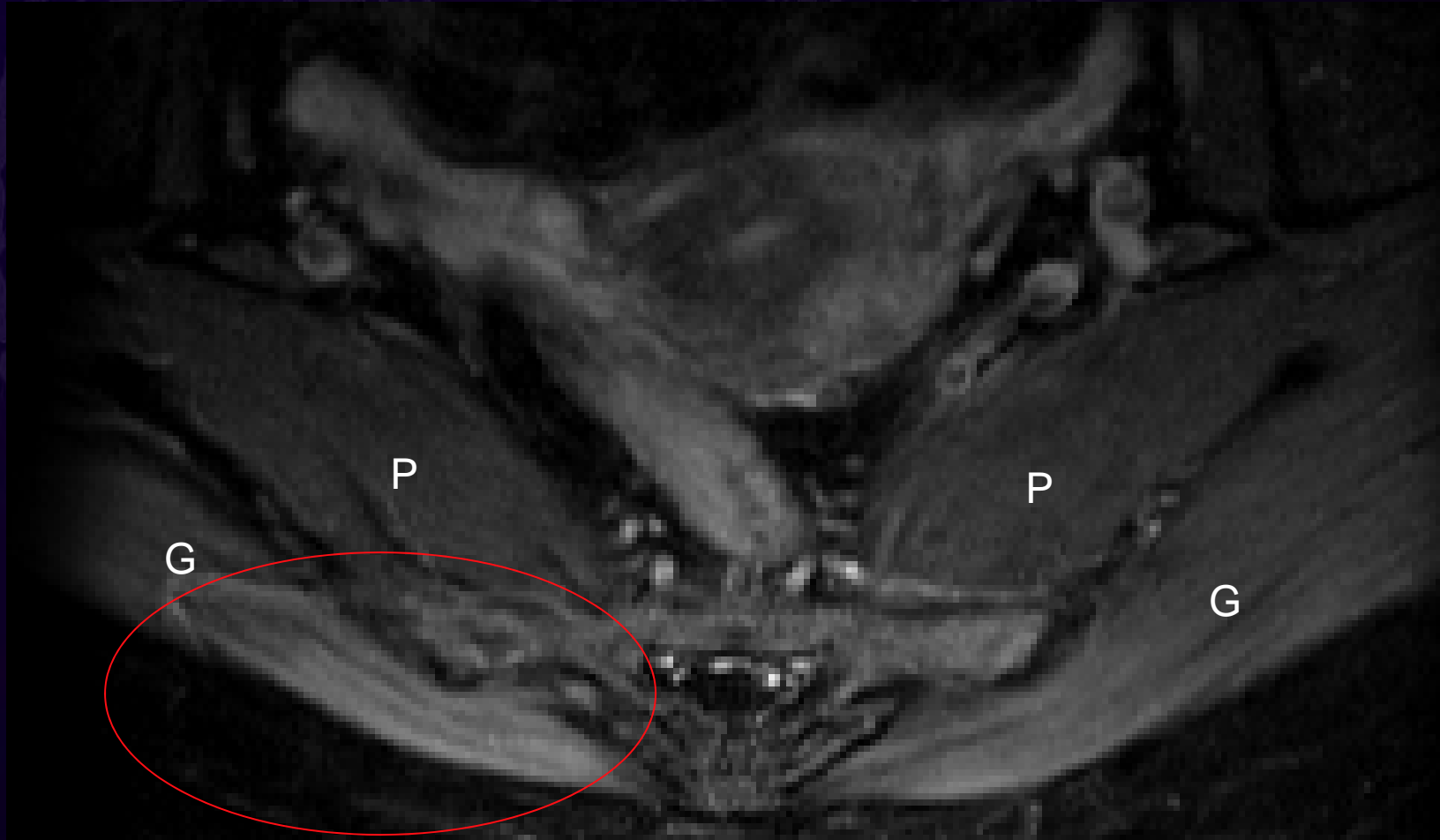
# Piriformis injection?



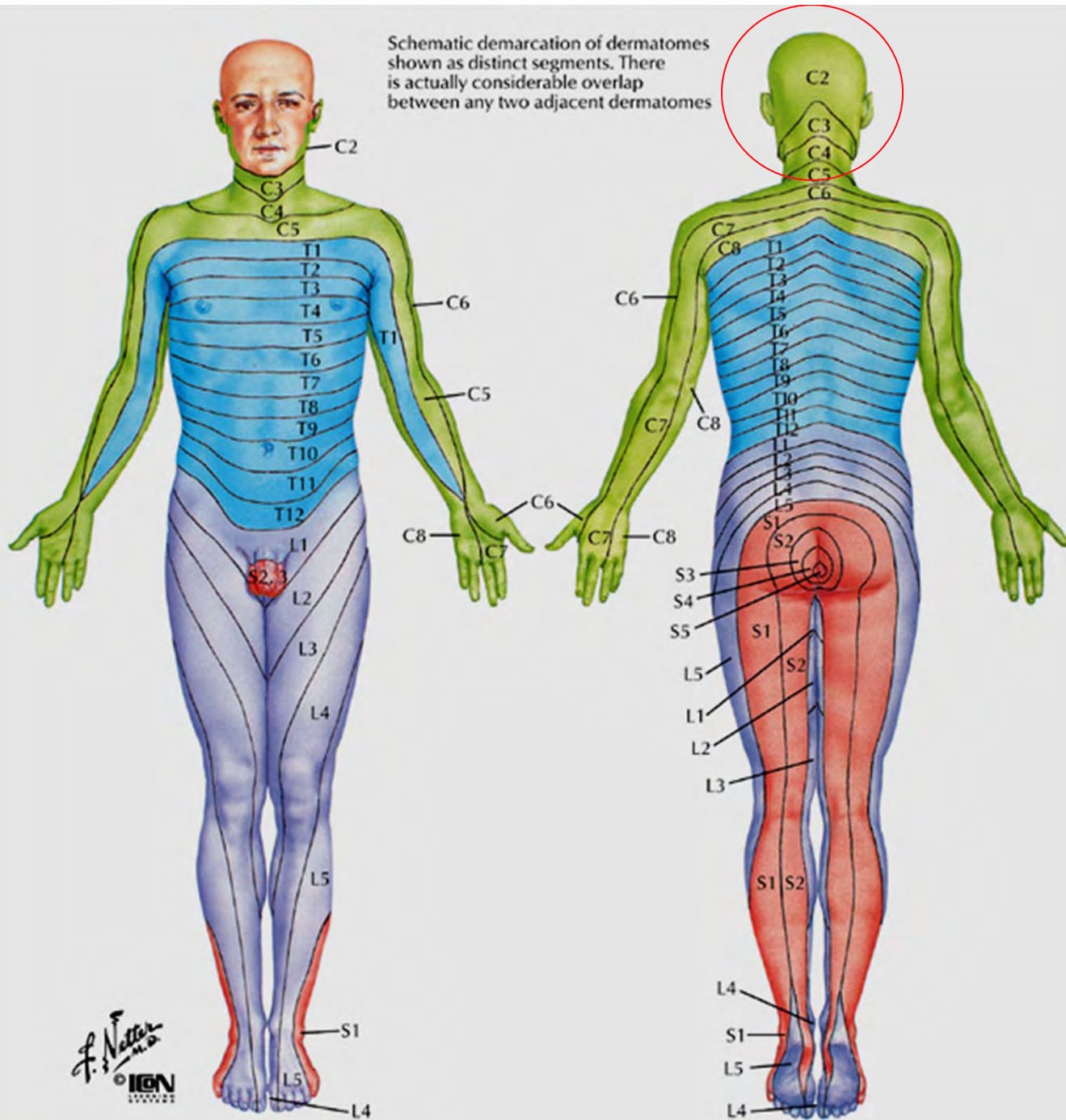
Axial T1



# Piriformis injection?



Schematic demarcation of dermatomes shown as distinct segments. There is actually considerable overlap between any two adjacent dermatomes



F. Netter  
M.D.  
© IGV  
LONDON



# Cervicogenic Headache

- 0.4%-2.5% general population
- 15-20% pain management patients
- Overlaps primary HA disorders – tension, migraine
- Reliable indicator: pain starts in neck radiating to frontotemporal; provocation w/ neck motion

# Cervicogenic Headache: Facet

- 70% compressive force upon discs transfers to facet jts.
- Whiplash: excessive flexion/extension
- Referred-pain maps – similar to dermatomal maps (Dwyer A. 1990)

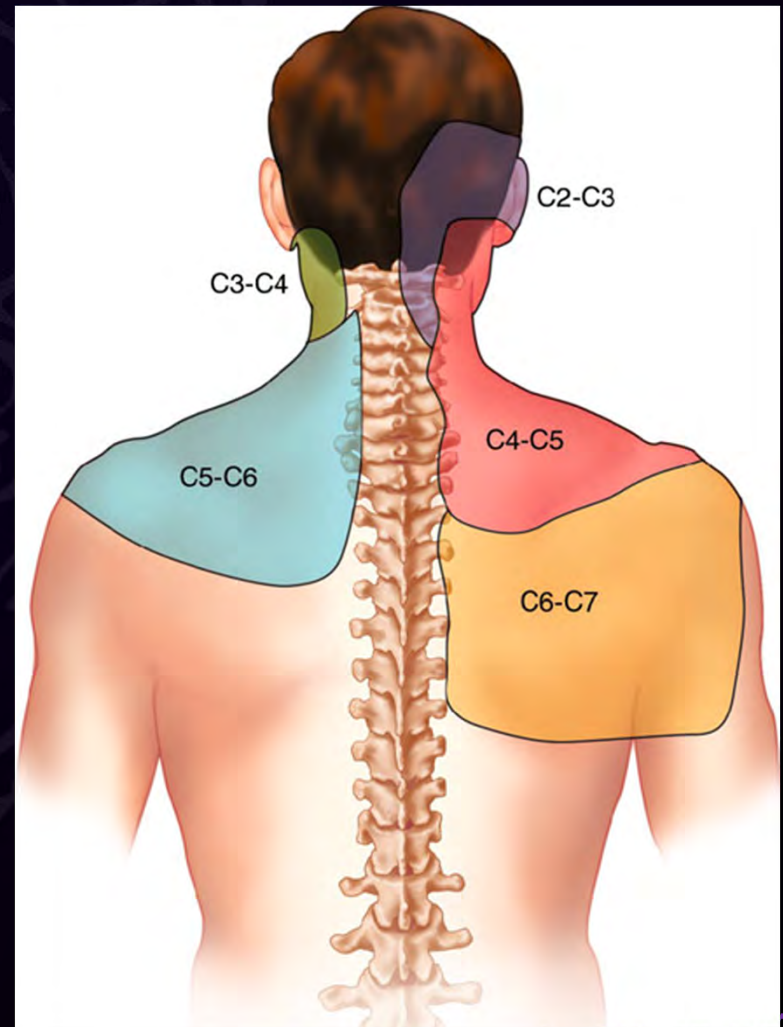
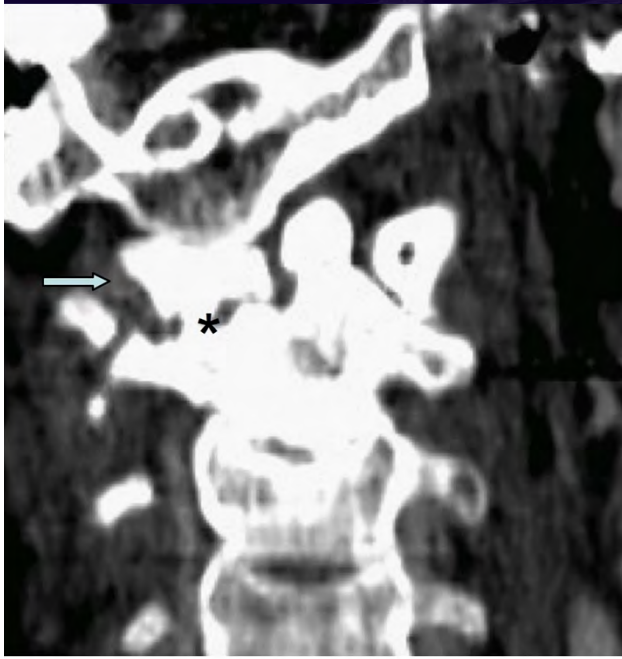
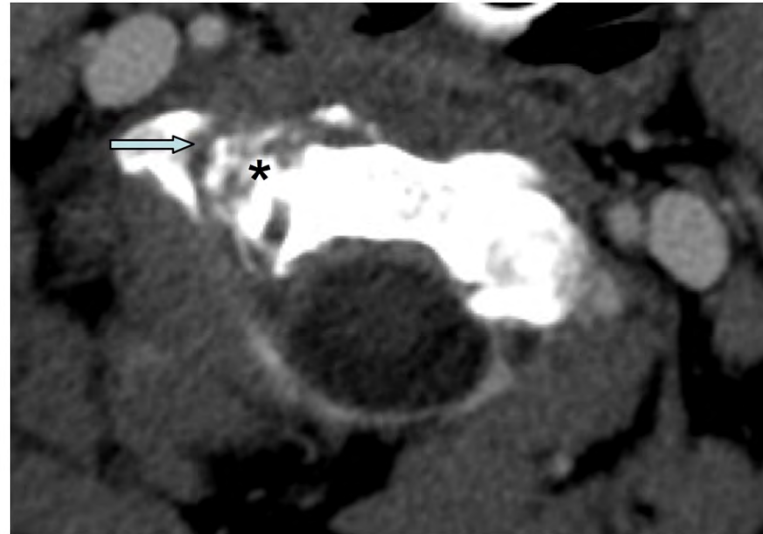


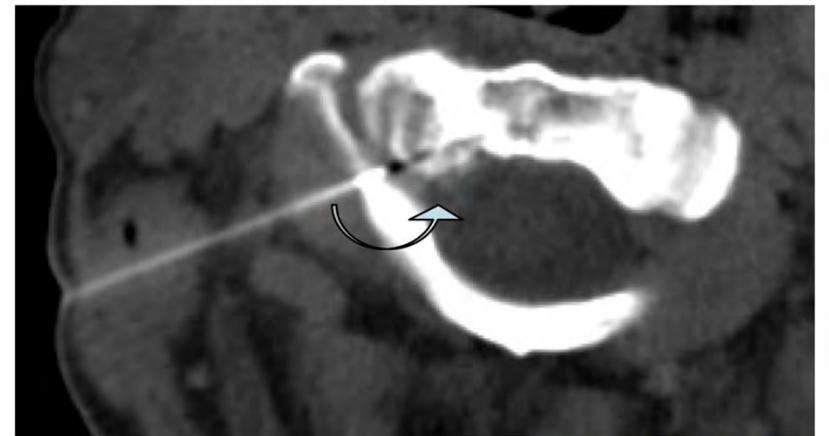
Figure 5



A



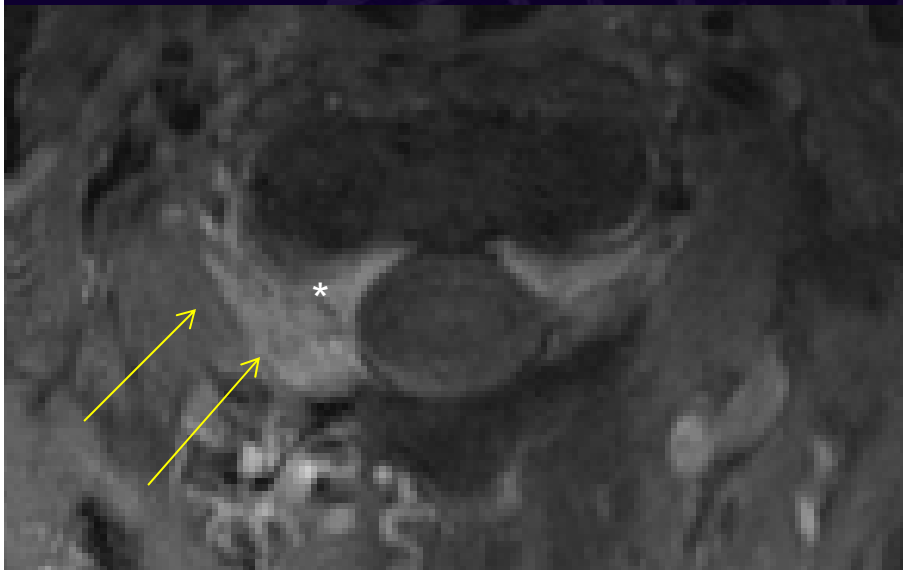
B



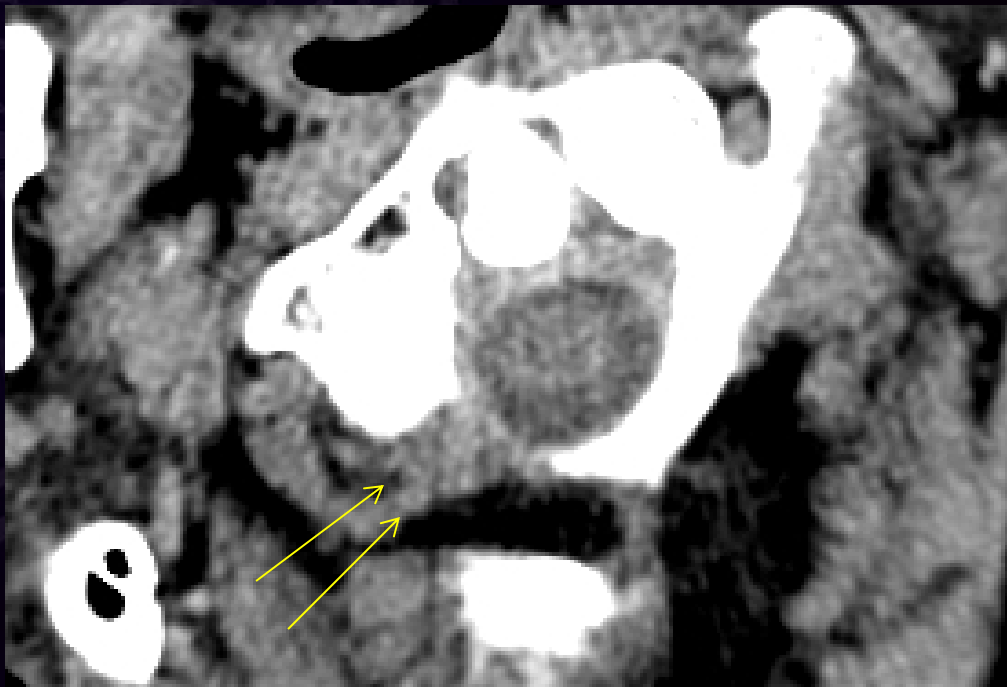C



91 y o M  
Post-operative decompression  
C2 with scar

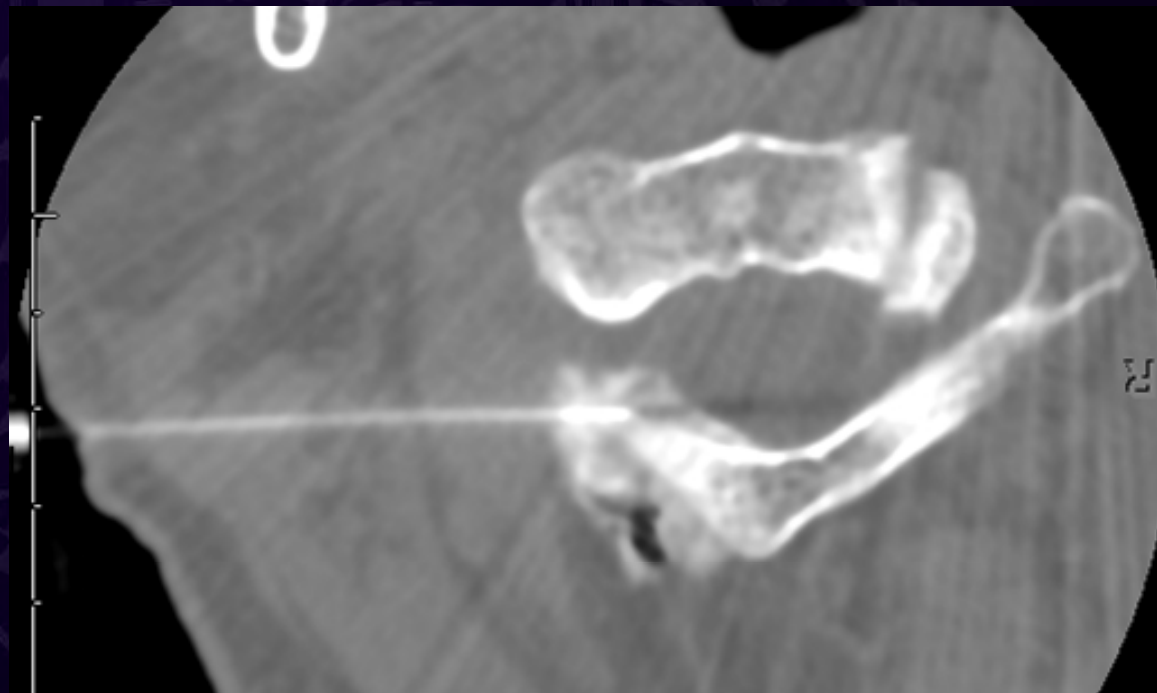


Axial T1 post-gad  
Fat sat



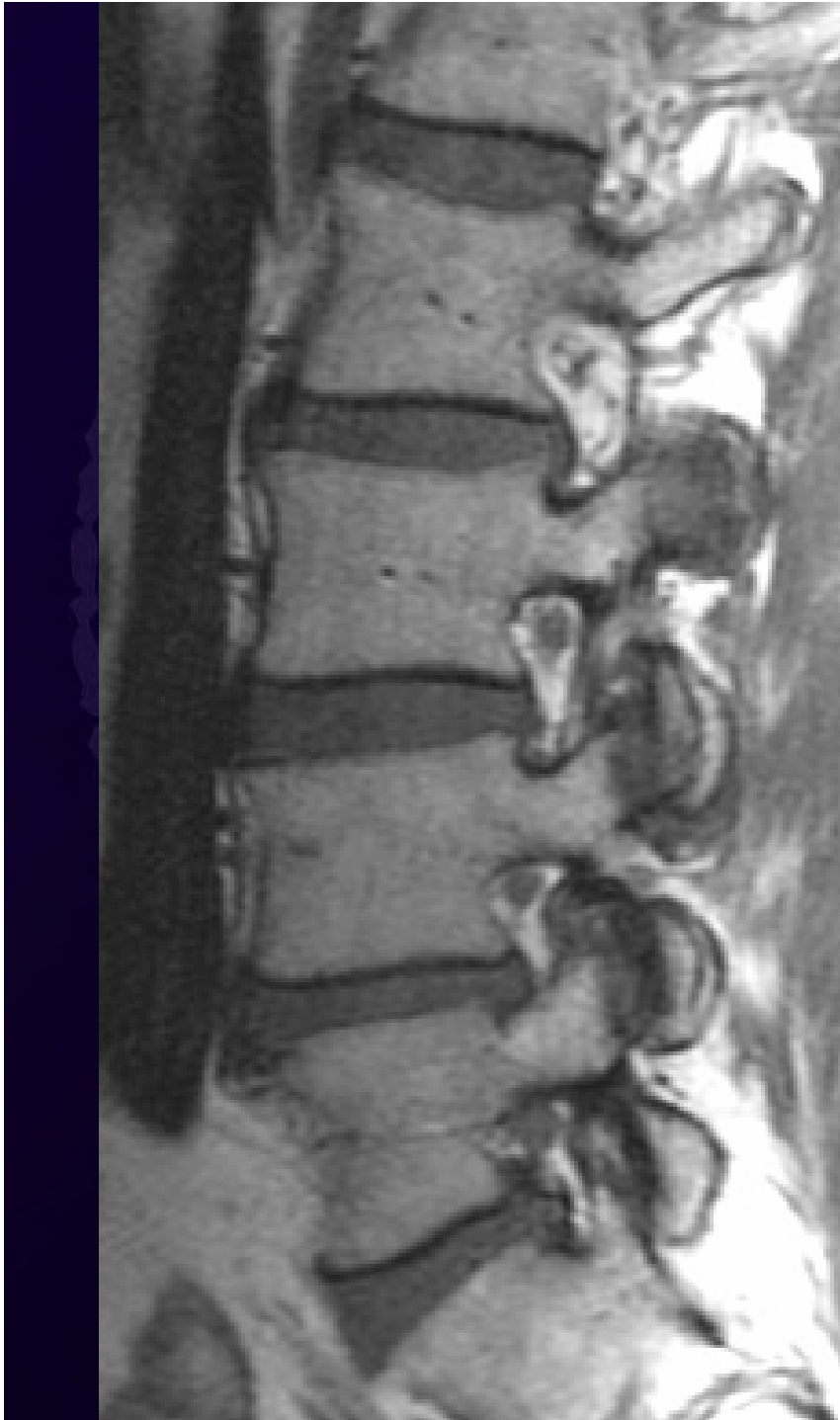
Axial CT non-con



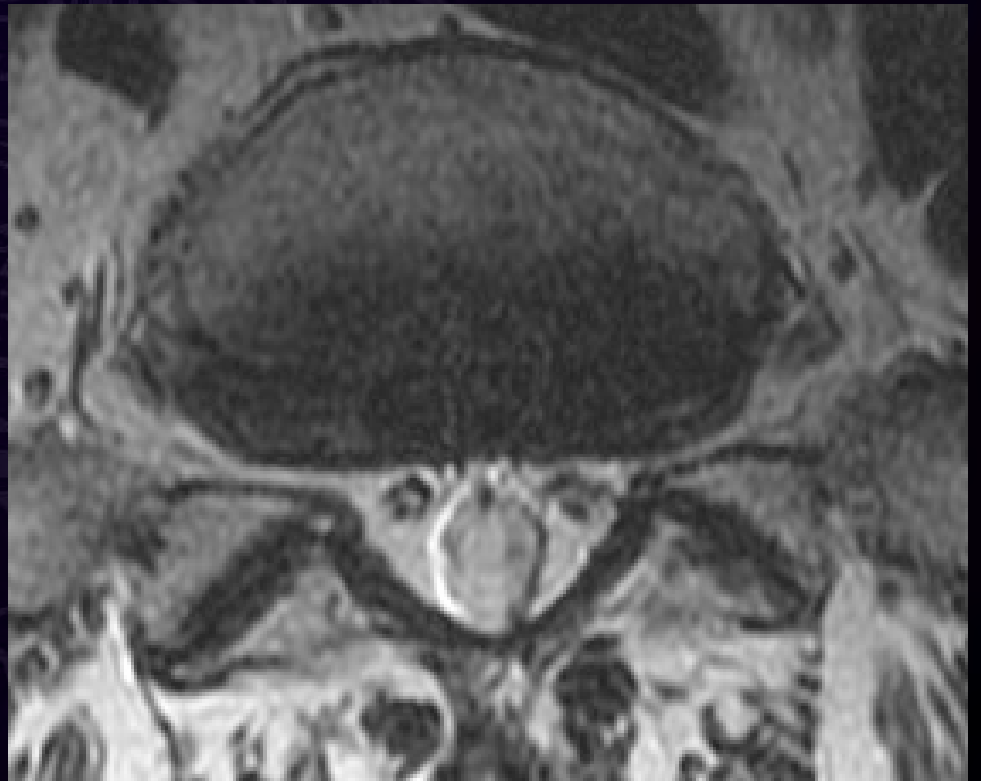


C2 block



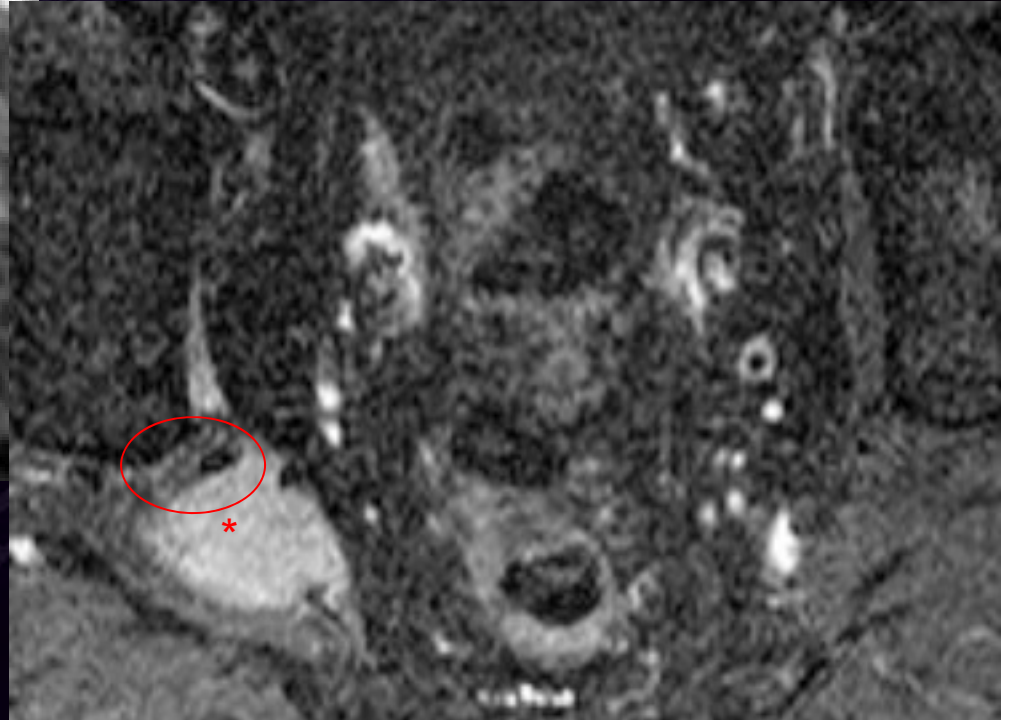
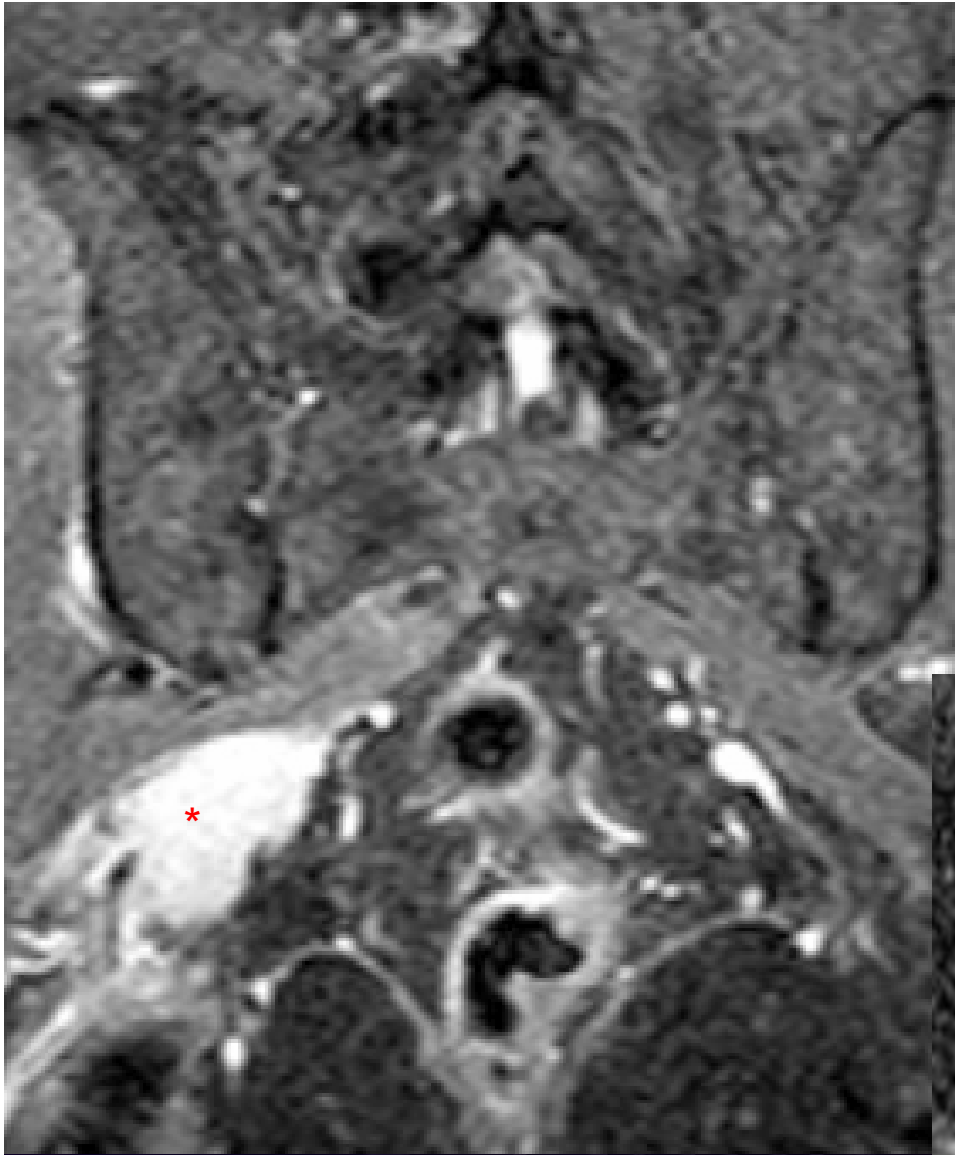


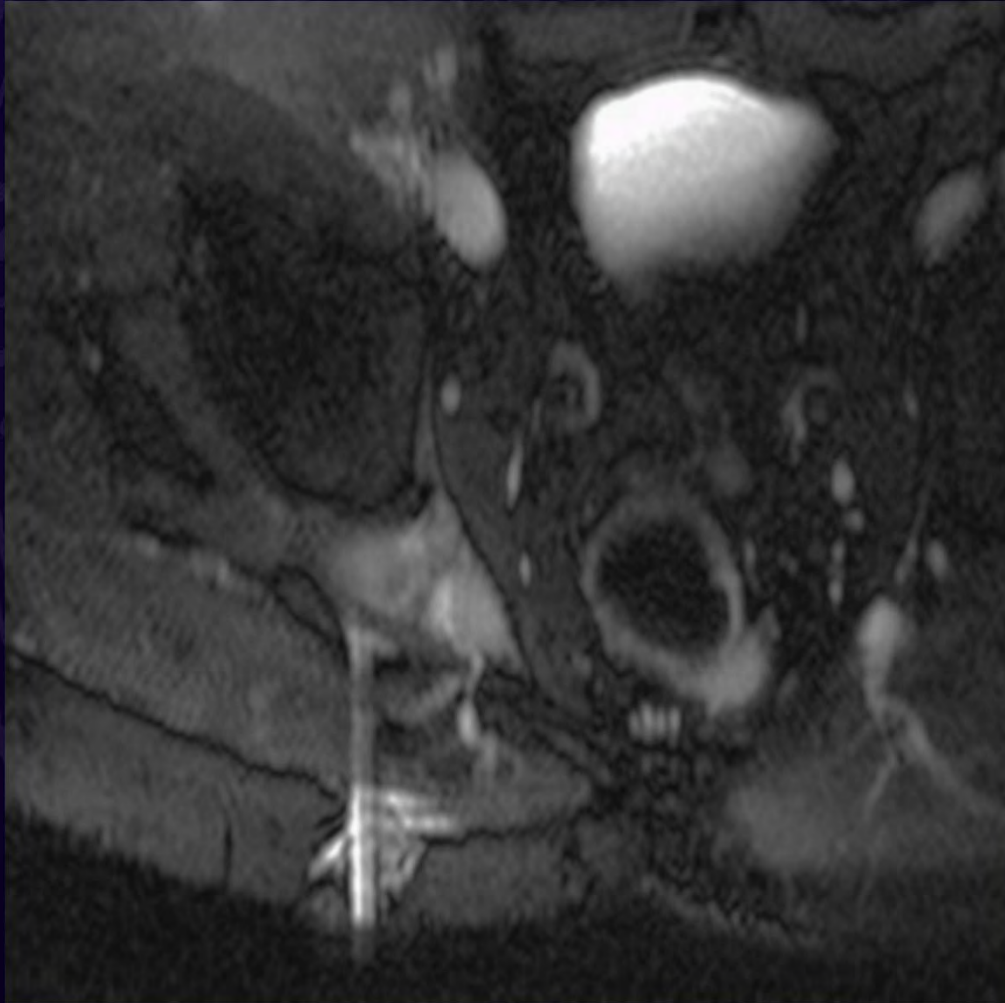
RIGHT SCIATICA



STEROID DOSE PACK  
NERVE ROOT BLOCK





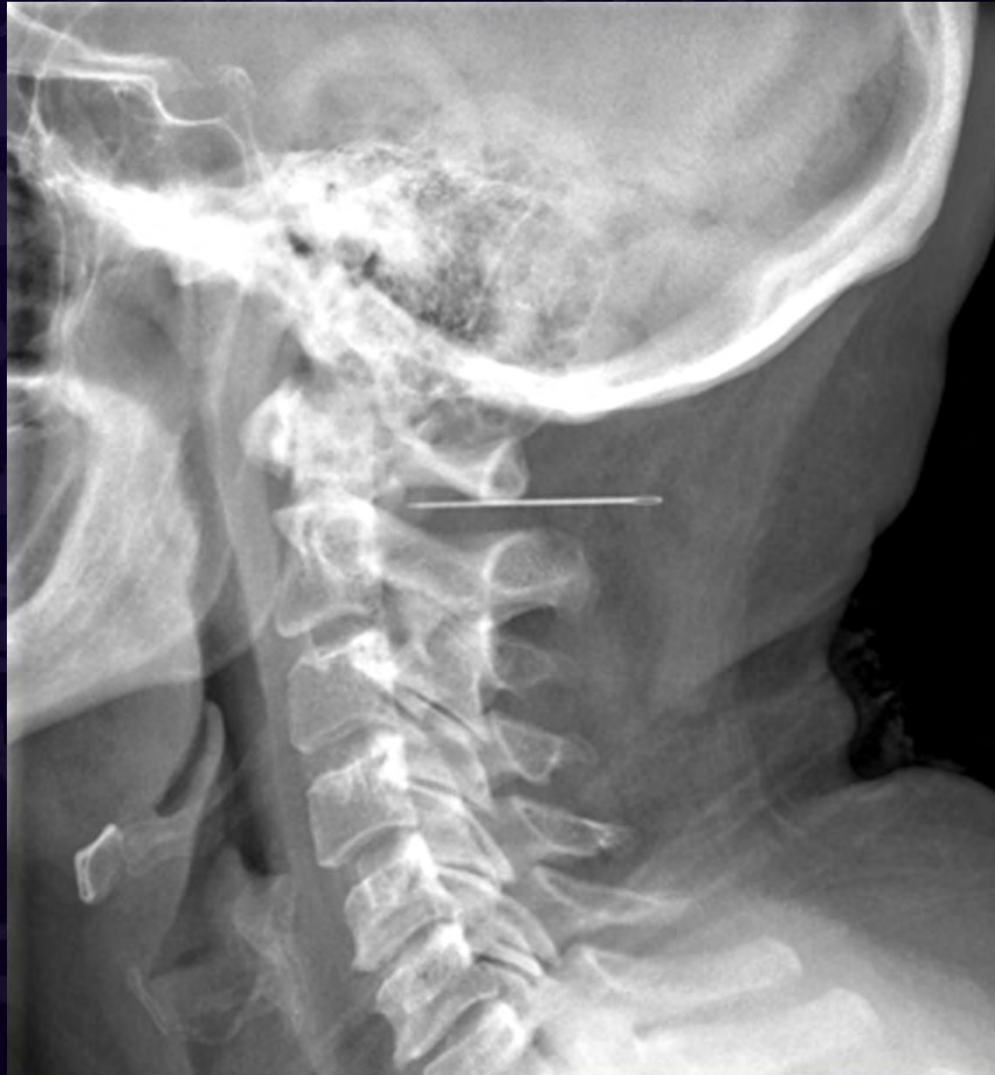


Lymphoma  
within  
sciatic notch  
compressing  
sciatic nerve

# Summary

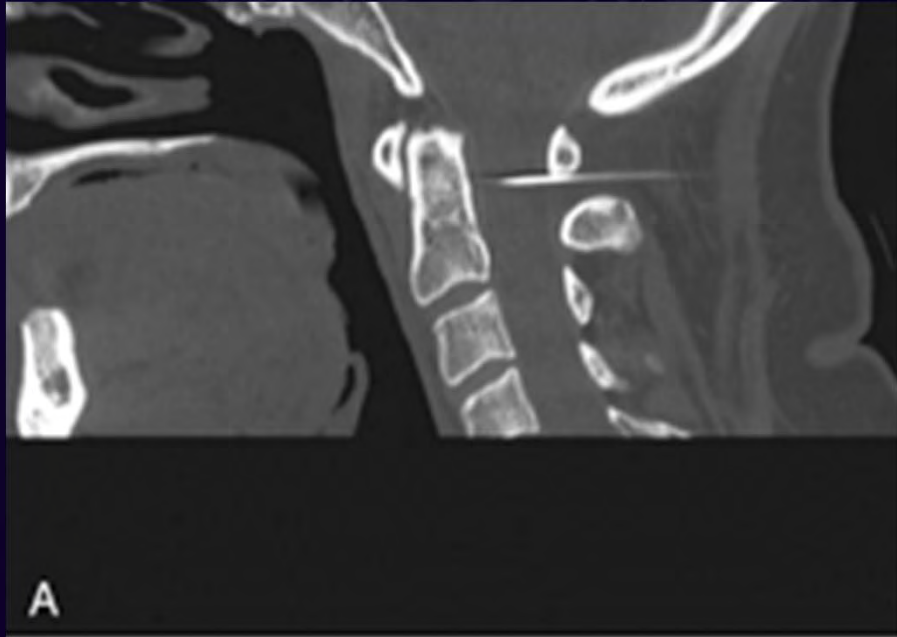
- Spine intervention offer dx and therapeutic non-operative management safe and precise
- Localization for operative therapy
- Mission – continue to advance imaging techniques to identify and target pain generators

# “Self-Pith”

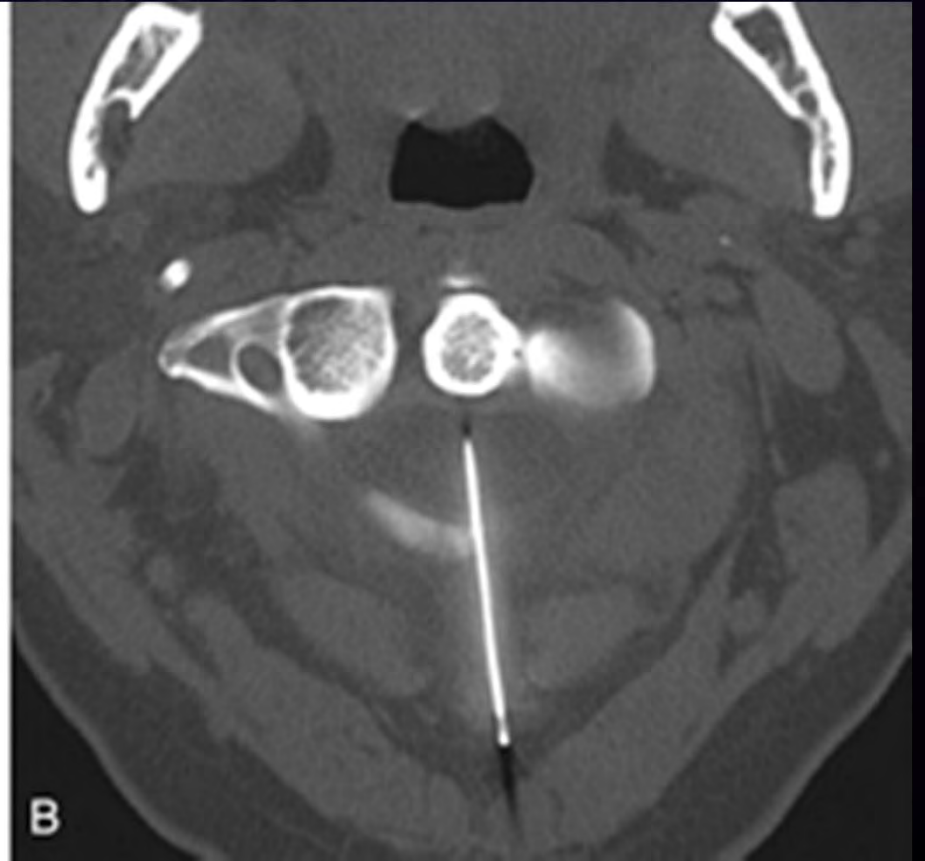


Anderson DW AJNR April 2007





A

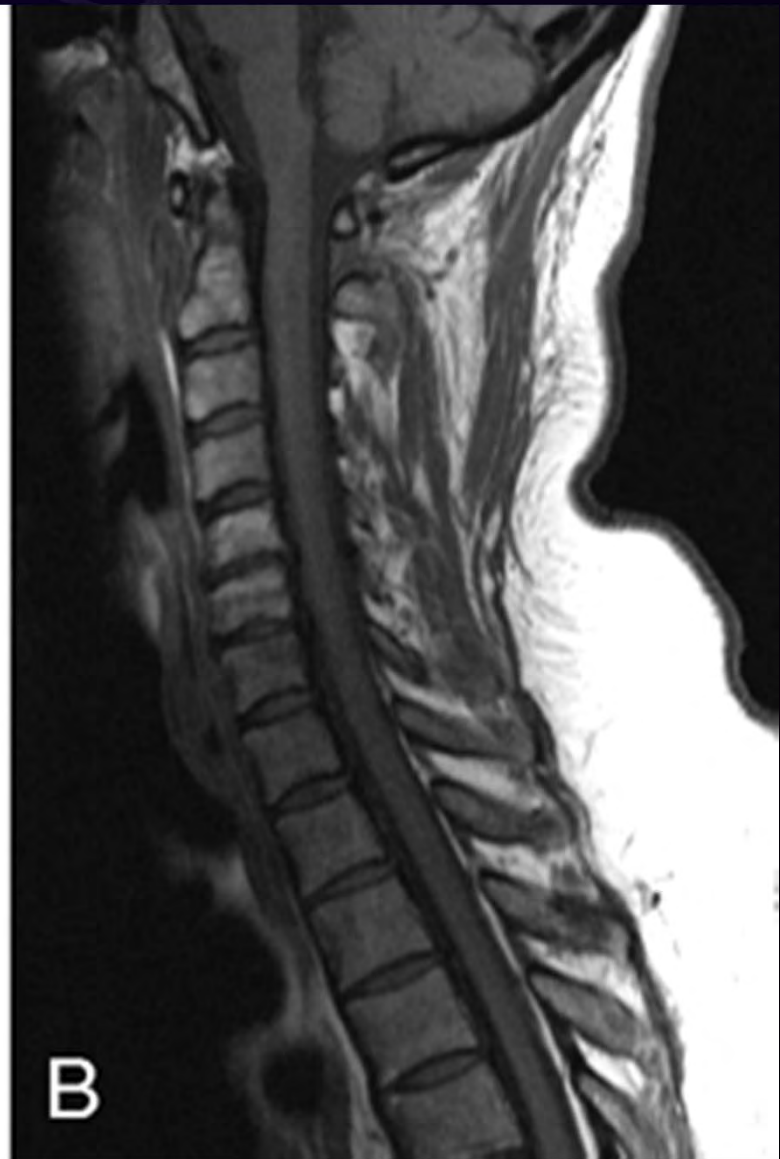
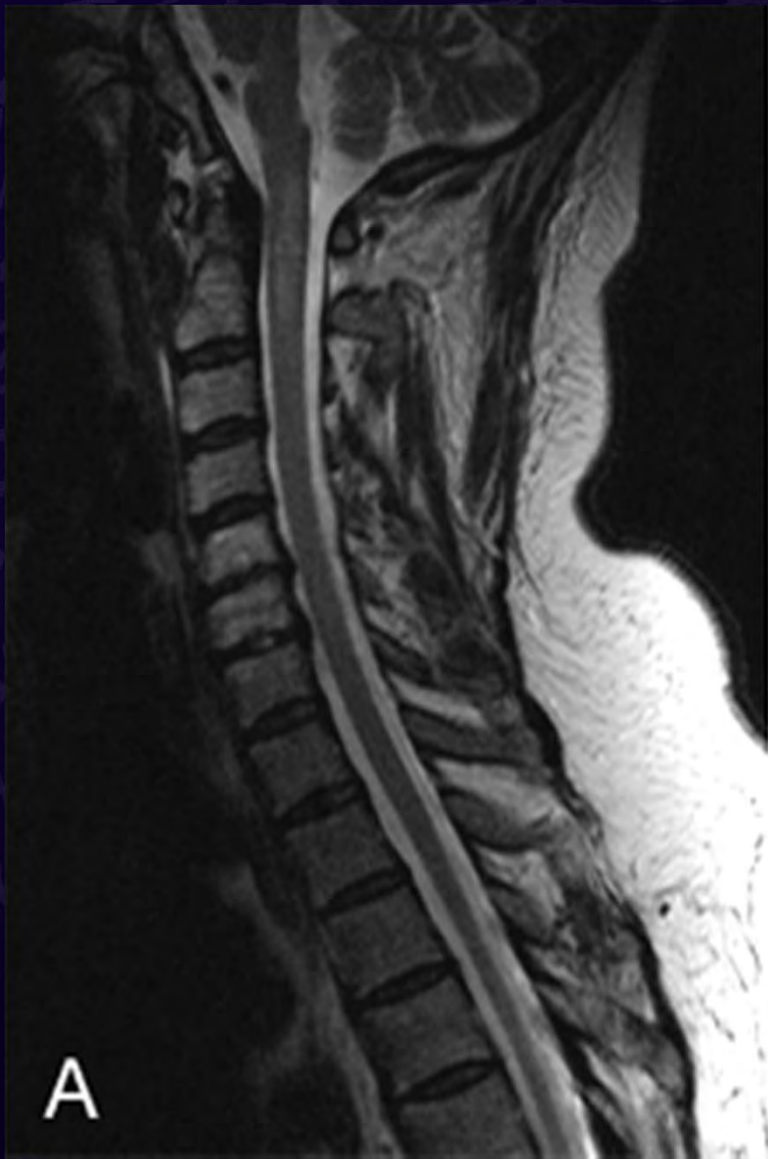
B

Anderson DW AJNR April 2007







Anderson DW AJNR April 2007





Thank you!!

[cynthia.t.chin@ucsf.edu](mailto:cynthia.t.chin@ucsf.edu)

